

A case of systemic lupus erythematosus with complex partial status epilepticus

Masayasu Tsuji¹, Hisashi Tanaka², Masahito Yamakawa³,
Ryuichi Sagawa⁴, Hideki Azuma⁵

¹ Department of Psychiatry; ² Department of Neurology; ³ Department of Internal Medicine; ⁴ Department of Psychiatry, Kyoritsu General Hospital; ⁵ Department of Psychiatry, Nagoya City University Medical School, Nagoya, Japan

Received July 28, 2004 ; Accepted February 16, 2005

ABSTRACT – We describe a woman with systemic lupus erythematosus who had complex partial status epilepticus as the sole epileptic manifestation. The patient presented with a confusional state, initially considered to be psychotic in nature, due to SLE. However, the EEG demonstrated the epileptic etiology of her symptoms. In patients with lupus presenting with prolonged episodes of confusion and behavioural disturbance, an EEG should be performed, whenever possible during the episode, even in the absence of a previous history of epilepsy.

Keywords: systemic lupus erythematosus, complex partial status epilepticus, confusional state, non-convulsive status, psychosis

Systemic lupus erythematosus (SLE) is frequently associated with seizures (Palace and Lang 2000), which can be partial or generalized. Patients may also experience status epilepticus, rarely presenting as complex partial status epilepticus (CPSE). Our patient was initially considered to be suffering from SLE with psychosis, but the symptoms were later attributed to CPSE. This case report describes SLE presenting uniquely as CPSE.

amination was normal. Brain CT scan revealed diffuse cerebral atrophy. Magnetic resonance imaging (MRI) of the brain also disclosed diffuse cerebral atrophy, mainly in frontal and temporal lobes, and some lacunae lesions in the white matter and basal ganglia.

Her confusional state disappeared the next day without any medication apart from antibiotics and vitamins. After the first episode, when she was no longer confused, an electroencephalogram (EEG) showed a 9-10 Hz background activity and occasional, diffuse slow (5-7 Hz) wave bursts with a frontal maximum. Carbamazepine (CBZ) was then administered at a daily dose of 200 mg in view of the possibility that her confusional state was an epileptic event.

One month later, she again had an episode of confusion and abnormal

Case study

In late October 2000, a 56-year-old, right-handed female with a 33-year history of SLE and under treatment with immunosuppressive drugs and steroids, was admitted to our hospital for a first episode of confusional state preceded by nausea. Neurological ex-

Correspondence:

M. Tsuji
Department of Psychiatry
Kyoritsu General Hospital
4-33, Goban-Cho, Atsuta-ku
Nagoya,
Japan
Tel: 052 654 2211
Fax: 052 651 7210
<minato99@quartz.ocn.ne.jp>

behaviour, preceded by vomiting, during which she complained of a feeling of heaviness in her legs. She was agitated in bed and said "I want to have an easy death." This episode involved no automatisms or clinical manifestations. At this time, since her neurological examination was normal and her symptomatology was considered SLE-related, we thought that she had some type of psychosis.

An EEG showed 150 μ V, diffuse 5-7 Hz continuous slow waves (figure 1). The EEG and clinical symptoms improved following intravenous administration of diazepam (DZP). She was able to speak normally, her mood improved and psychomotor manifestations disappeared. However, her confusional state reappeared. An intravenous drip of phenytoin (PHT) was then given, and her confusional state disappeared within three days. The patient was disoriented during these episodes and retained little memory of them. No abnormal metabolic data were subsequently found. A diagnosis of non-convulsive status epilepticus (NCSE) was made and treatment with PHT was continued.

During the next three years she experienced a total of seven episodes of CPSE. Nausea or vomiting preceded all but one of the CPSE episodes, each of which continued for two to six days. The ictal EEG of the fourth episode showed high voltage, 2.5-3 Hz, continuous slow waves or 2.5-3 Hz, diffuse spike and wave complexes, which partially

formed triphasic-like waves. Ictal EEGs of other episodes also showed continuous high voltage 2.5-3 Hz, slow waves or diffuse, continuous, 2.5-3 Hz spike and wave complexes. No correlation was found between these confusional episodes and serological evidence of worsening SLE. Steroids could not be incriminated as she was on this regimen only when she experienced the first two episodes, but were discontinued and only immunosuppressive drugs were used thereafter.

During the fourth episode, administration of intravenous diazepam modified the continuous diffuse high-voltage, 2.5-3Hz slow waves over the fronto-polar regions. The interictal EEG sometimes also demonstrated 2.5-3 Hz high-voltage slow waves over the left frontal areas. We then considered that her epilepsy was probably frontal in origin.

With evolution, interictal, abnormal slow waves were more frequently recorded. Recently, delusional symptoms were observed during the transitional period following episodes of nonconvulsive status. For example, after her seventh episode she cried, saying "My husband and daughter were hurt in a traffic accident!". Brain atrophy at CT was seen to be progressing gradually.

Moreover, between the fourth and fifth episode of NCSE, she experienced a wandering episode. Although we were not able to obtain detailed information on this episode we

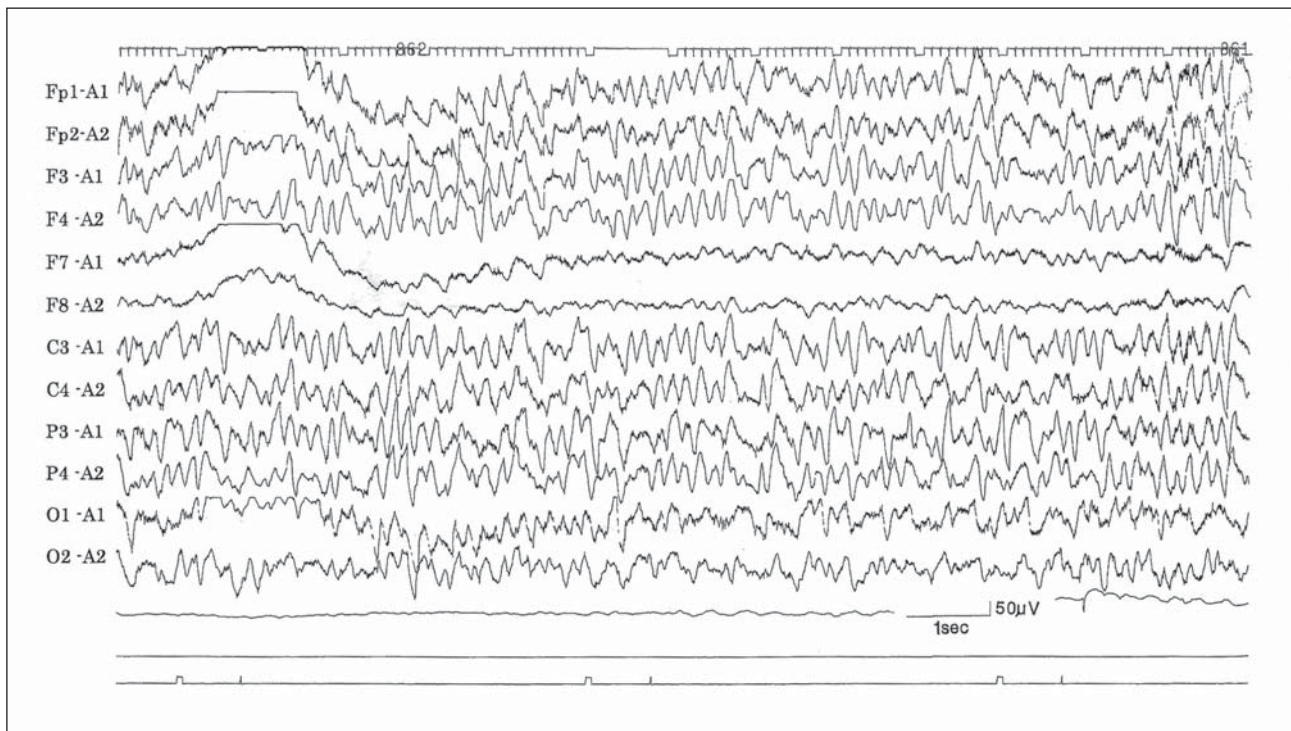


Figure 1. Ictal EEG of a second episode of CPSE. High-voltage, 5-7 Hz, continuous slow waves are diffused. The patient had never experienced other episodes evocative of partial seizures.

believe that, because it lasted for a few hours, this was not a complex partial seizure but yet another episode of NCSE. The patient never experienced other types of seizures or manifestations that could be considered as being of an epileptic nature (staring, automatisms or other focal manifestations). After her fourth episode, phenytoin was discontinued and replaced by sodium valproate. Currently she receives a combination of sodium valproate and carbamazepine. Although blood levels of these drugs are within the usual range, she still experiences episodes of NCSE.

Discussion

We describe the clinical, electroencephalographic and neuroimaging findings of a woman with SLE who initially showed NCSE and which later resolved to the frontal lobe, after IV benzodiazepines revealed it to be CPSE.

We were at first uncertain whether the continuous slow waves showing partially triphasic wave on the EEG were ictal, due to a disturbance of consciousness or psychosis. However, the slow waves disappeared, her level of consciousness improved following intravenous injection of DZP, and we could find no abnormal metabolic data. Fountain and Waldman (2001) reported that benzodiazepine administration may help distinguish the sharp waves of epileptic origin from those resulting from metabolic encephalopathy. They found that when a benzodiazepine induces a resolution of electrographic changes and clinical improvement, the epileptic origin becomes more evident. In short, because a resolution of electrographic changes and clinical improvement was achieved by diazepam in our case, the confusion was not considered as an encephalopathy. Besides, rhythmic bursts, such as those we recorded, are not usually seen in encephalopathic processes. Psychosis was also eliminated for the reasons described above.

On the ictal EEGs of this case, clearly lateralized epileptiform discharges were not recorded, although frontal discharges were eventually seen; however, this may be due to the fact that ictal onset was not recorded on the scalp EEG. This is also supported by the fact that the interictal EEG sometimes showed slow waves predominantly over the left frontal area and ictal, continuous, diffuse high-voltage slow waves over the frontal pole became evident following administration of diazepam. Mayeux and Lüders

(1978) suggested that a prolonged complex partial seizure resulting in CPSE should have continuous complex symptoms accompanied by a continuous electroencephalographic seizure pattern that is either focal or secondarily generalized. They also suggested that an ictal EEG of CPSE can take the form of generalized waves.

Both diffuse and focal electroencephalographic abnormalities have been reported in lupus (Koppel 1997). Our case is thought to present the long-lasting periods of confusion of CPSE reported by Gastaut and Tassinari (1975). Some authors have observed CPSE occurring in lupus. Fernández-Torre *et al.* (2003) reported the case of a patient with SLE who experienced episodes of extratemporal CPSE, having also presented left, hemicorporal, partial motor seizures evolving occasionally into generalized tonic-clonic attacks. They suggested that CPSE should be considered as a possible cause of altered mental status in lupus and that an EEG is essential to make an accurate diagnosis. This becomes particularly true when considering the case of our patient who had never presented with any other type of seizure suggestive of an epileptic origin for her confusional attacks.

In conclusion, EEG should be conducted in all SLE patients presenting with episodes of acute confusional state, even in the absence of a history of epilepsy. □

References

- Fernández-Torre JL, Sánchez JM, González C, Fernández-Guinea. Complex partial status epilepticus of extratemporal origin in a patient with systemic lupus erythematosus. *Seizure* 2003; 12: 245-8.
- Fountain NB, Waldman WA. Effect of benzodiazepines on triphasic waves. *J Clin Neurophysiol* 2001; 18: 345-52.
- Gastaut H, Tassinari C. Status epilepticus. In: Remond A, ed. *Handbook of electroencephalography and clinical neurophysiology vol 13A*. Amsterdam: Elsevier, 1975: 39-45.
- Koppel BS. Connective tissue diseases. In: Engel J, Pedley TA, eds. *Epilepsy: A comprehensive textbook*. Philadelphia: Lippincott-Raven Publishers, 1997: 2597-604.
- Mayeux R, Lüders H. Complex partial status epilepticus: Case report and proposal for diagnostic criteria. *Neurology* 1978; 28: 957-61.
- Palace J, Lang B. Epilepsy: an autoimmune disease? *J Neurol Neurosurg Psychiatry* 2000; 69: 711-4.