

“Burst and slow complexes” in nonconvulsive epileptic status

Akio Ikeda¹, Masaru Matsui¹, Yoshiki Hase¹, Takehumi Hitomi¹, Yukitoshi Takahashi², Hiroshi Shibasaki³, Shun Shimohama¹

¹ Department of Neurology, Kyoto University School of Medicine, Kyoto

² National Epilepsy Center, Shizuoka Institute of Epilepsy and Neurological Disorders, Japan

³ Takeda General Hospital, Kyoto

Received April 25, 2005; Accepted October 10, 2005

ABSTRACT – Generalized 1Hz, burst-and-slow-wave complexes were observed in a comatosed patient with acute disseminated encephalomyelitis (ADEM) when she showed extremely intractable, generalized convulsions and fragmented myoclonus in the whole body. Two types of short-latency SEPs were obtained separately during the burst and slow phase of the EEG (SEP-burst and SEP-slow, respectively), which showed a two fold greater amplitude of N20 in the former than in the latter. This suggests enhanced responsiveness to the peripheral stimuli during the burst phase as compared with the slow phase. CSF and serum were positive for autoantibodies to NMDA receptors. The “burst and slow complexes” reported here are considered to be an atypical EEG pattern of a generalized epileptic phenomenon.

Key words: seizure, EEG, burst and slow complex, Glu R antibodies, acute disseminated encephalomyelitis

In clinical EEG, generalized epileptiform discharges comprise generalized spikes, polyspikes, sharp waves, spike-and-slow-wave complexes, or sharp-and-slow-wave complexes seen in patients with generalized epilepsy (Niedermeyer 1996, Kaplan, 2002). Generalized brief bursts of fast activities are also seen in patients with symptomatic or idiopathic generalized epilepsy (Brenner and Atkinson 1982). These, mainly interictal, epileptiform discharges are usually coupled with a slow activity, such as a spike-and-slow-wave complex, that presumably represents compensatory inhibitory mechanisms within the active, epileptic neuron (Engel 1989). In exceptional cases, the brief burst pattern of fast activities lasting several seconds is not accompanied by slow

wave complexes, because it represents fragmented ictal, but not interictal, EEG activity (Engel 1990).

We encountered a patient with acute disseminated encephalomyelitis (ADEM). The patient showed severe generalized and partial epileptic status, which was associated with generalized, 1Hz burst-and-slow-wave complexes (burst and slow complexes). The patient had positive titers for autoantibodies against glutamate receptor in the CSF and the serum during the acute stage. The “burst and slow complexes” seen in this particular patient, are most likely to be a type of epileptic EEG pattern that has not been well documented. It may represent generalized, epileptic hyperexcitability of the cerebral cortex caused

Correspondence:

A. Ikeda, MD, DMS,
Department of Neurology,
Kyoto University School of Medicine,
Shogoin, Sakyo-ku,
Kyoto, 606-8397,
Japan.
Tel.: (+00 81) 75 751 3772,
Fax: (+00 81) 75 751 9416.
<akio@kuhp.kyoto-u.ac.jp>

by, or at least closely related to, excitatory glutamate receptor activation.

Case report and methods

The patient was a 19-year-old Japanese woman who developed an acute high fever, confusion, and then incoherent speech and delusion within a day, and immediately thereafter, the patient developed generalized convulsions. On admission, the patient was in a state of stupor. Signs of meningeal irritation were present, and CSF examination showed elevated protein and cell counts, but normal glucose, suggesting aseptic encephalitis. CT and MRI showed significant brain edema. Later during the course, there were poorly enhanced, punctum lesions mainly in the white matter. No neurotropic virus titers were elevated in the acute stage, and thus ADEM was thought to be highly possible. In spite of treatment with pulse therapy of intravenous steroid, Acyclovir and high dose immunoglobulin, the patient became comatose and needed mechanical ventilation. Generalized convulsions, continuous or intermittent, massive, violent myoclonus involving the whole body or various parts of the body, and jerky nystagmus occurred spontaneously in both directions, and were often synchronized to the facial myoclonus, which were all poorly controlled even with large doses of multiple anticonvulsive agents including phenytoin 400 mg/day (blood level of 20.1 mg/L), valproic acid 1600 mg/day (29 mg/L), phenobarbital 150 mg/day (24.0 mg/L), lorazepam 3 mg/day and clonazepam 1 mg/day. The CSF and serum of this patient were positive for IgG and IgM types of autoantibodies against glutamate receptors (GluR ϵ 2 component) during the acute phase. The following, peculiar EEG pattern was seen during this period of the clinical course.

Results

The EEG was recorded repeatedly while the patient showed fragmented, multifocal myoclonus of the whole body (*figure 1A*). The patient was also receiving a continuous propofol injection of 200 mg/hour (= 4 mg/kg/hour) for more than 20 days, in addition to the anticonvulsive agents we described above. Generalized 1Hz, burst-and-slow-wave complexes were observed continuously. There were no convulsive movements in synchrony with the EEG discharges, except for fragmented, irregular myoclonus. This EEG activity was maximum at the bilateral fronto-central areas.

In order to delineate the difference in cortical excitability between the burst- and slow phase of this EEG pattern, somatosensory-evoked potentials (SEPs) to the median nerve stimulation were recorded separately during each

phase, by continuously monitoring EEG. The raw data were stored and the off-line average was obtained separately (SEP-burst and SEP-slow). The intervals of the median nerve stimuli between two consecutive stimuli were kept at least more than 1 sec. As a result, both SEP-burst and SEP-slow showed prolonged, but robust N20 and P25, and the amplitude of N20 was much smaller in SEP-slow (2.5 μ V) than in SEP-bursts (5 μ V) (*figure 1B*).

During the acute stage, the patient subsequently underwent barbiturate coma therapy on two occasions, for 2 and 3 days respectively, with an interval of 2 weeks. The burst and slow complex pattern gradually disappeared after the second barbiturate coma therapy, and clinically, the generalized seizures and multifocal, fragmented myoclonus also disappeared.

Discussion

The burst and slow complexes seen in the present patient could suggest extremely intensive, epileptic activities arising from the cerebral cortex for the following reasons:

- They were very frequently recorded while the patient showed highly intractable convulsions and fragmented, multifocal myoclonus of the whole body, before barbiturate coma therapy was started; this EEG pattern disappeared after the second barbiturate coma therapy when the seizures were clinically better controlled;
- The SEP-burst showed a larger N20 and the SEP-slow showed a smaller N20, suggesting cortical hyperexcitable and inhibitory states, respectively. This is consistent with the usual physiological property of the so-called spike-and-slow-wave complexes in clinical epilepsy;
- Autoantibodies against NMDA receptor (Takahashi *et al.* 2003) were positive in CSF and serum when this EEG pattern was seen, and it is most likely that clinically and EEG-wise, the frequent seizures resulted in the comatose state in the present patient.

It is worth here discussing the effects of drugs on EEG activity. Many anticonvulsants, such as phenytoin, valproic acid and phenobarbital, were introduced and sufficiently high, but not toxic, blood levels were achieved. There have been no reports suggesting that these drugs might cause this particular EEG pattern.

Propofol, an ultra-short-acting intravenous agent, works as a proconvulsant at lower doses of 0.5 to 1.5 mg/kg/hour, but as an anticonvulsant at higher doses of 2 to 4 mg/kg/hour. In our patient, propofol was continuously administered for more than 20 days at the rate of 4mg/kg/hour while this EEG pattern was intermittently observed. Propofol, in this patient, was thought to suppress epileptiform activities probably better than barbiturate (Van Cott and Brenner 2003). It has been reported that beta activity on scalp EEG was enhanced by propofol (Borgeat *et al.* 1991). When the propofol induced very

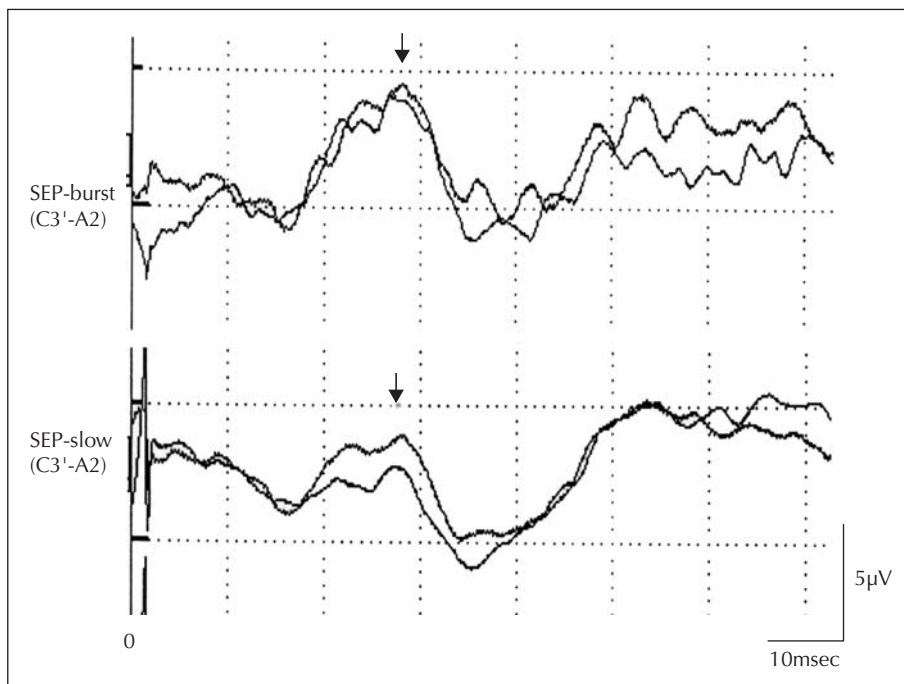
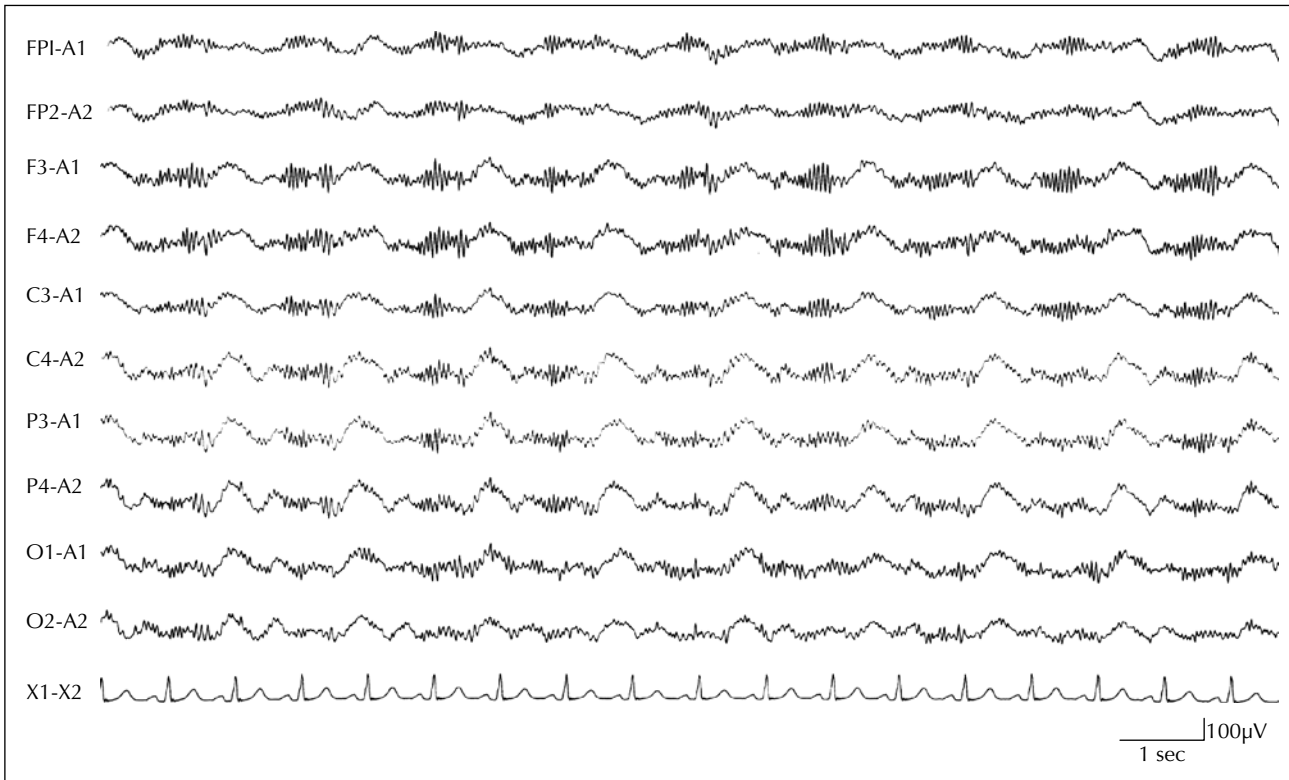


Figure 1. A) Generalized 1 Hz, brief burst-and-slow-wave complexes (burst and slow complexes) on scalp EEG. Bursts of about 30 Hz, fast activities with 50 μ V amplitude and 400 msec duration are always followed by negative, dome-like slow activity with duration of 400 msec. No robust bursts are overlaid on the slow wave components. **B)** Short latency SEPs to the right median nerve stimulation recorded from C3' of the scalp electrode. SEP-burst and SEPs-slow were recorded separately as described in the text. N20 amplitude in SEP-burst (5 μ V) is two fold greater than that in SEP-slow (2.5 μ V) (N20 amplitude was measured from the preceding peak of the opposite polarity. SEP-burst=SEPs obtained while bursts appeared on the scalp EEG, SEP-slow = SEPs obtained while slow components appeared on the scalp EEG. Peaks of N20 are shown by arrows). (Bandpass filter: 1.5-1500 Hz, N = 100 for each average, reference: right earlobe electrode).

light anesthesia, it was associated with slightly increased theta and beta activity power on the EEG. When propofol was used to induce deeper anesthesia, beta activity power decreased as compared with the awake or the very slight anesthetic state (Schultz *et al.* 2004). In the present patient, the delta frequency slow activity was predominant when propofol was injected, and thus it is unlikely that propofol itself caused this unusual EEG pattern.

The SEP finding showing the difference in cortical excitability between burst and slow phases is also probably an evidence against the notion that this EEG pattern was simply produced by propofol. However, the possibility that propofol may play a certain role in modulating the EEG pattern to produce this unique pattern can not be completely excluded. Furthermore, this patient showed positive NMDA receptor antibodies. The antibodies to NMDA receptors could, be not only a marker of the degree of abnormality or disease, but also the possible cause of or a modification/ potentiation factor for cortical hyperexcitability. It is not entirely clear whether any particular EEG pattern is produced under these pathophysiological conditions, and thus further observation is warranted. □

Acknowledgments. This study was partly supported by Grants-in-Aid for Scientific Research (C2) 15591520 from the Japan Ministry of Education, Culture, Sports, Science and Technology (MEXT), and the Research Grant for the Treatment of Intractable Epilepsy (16-1) from the Japan Ministry of Health, Labor and Welfare.

References

- Borgeat A, Dessibourg C, Popovic V, *et al.* Propofol and spontaneous movements: an EEG study. *Anesthesiology* 1991; 74: 24-7.
- Brenner RP, Atkinson R. Generalized paroxysmal fast activity: electroencephalographic and clinical features. *Ann Neurol* 1982; 11: 386-90.
- Engel Jr. J. Basic mechanisms of epilepsy. In: *Engel J Jr, ed. Seizures and epilepsy*. Philadelphia: F.A.Davis, 1989: 71-111.
- Engel Jr. J. Functional explorations of the human epileptic brain and their therapeutic implications. *Electroenceph clin Neurophysiol* 1990; 76: 296-316.
- Kaplan PW. Behavioral manifestations of nonconvulsive status epilepticus. *Epilepsy Behav* 2002; 3: 122-39.
- Niedermeyer E. Abnormal EEG pattern: epileptic and paroxysmal. In: Niedermeyer E, Lopes da Silva F, eds. *Electroencephalography. Basic principles, clinical applications, and related fields*. Baltimore: Williams Wilkins, 1996: 235-60.
- Schultz A, Crouven U, Zander I, *et al.* Age-related effects in the EEG during propofol anesthesia. *Acta Anesthesiol Scand* 2004; 48: 27-34.
- Takahashi Y, Mori H, Mishina M, *et al.* Autoantibodies to NMDA receptor in patients with chronic forms of epilepsy partialis continua. *Neurology* 2003; 61: 891-6.
- Van Cott AC, Brenner RP. Drug effects and toxic encephalopathy. In: Ebersole JS, Pedley TA, eds. *Current practice of clinical electroencephalography*. Philadelphia: Lippincott Williams Wilkins, 2003: 463-82.