

Coexistence of two distinct benign EEG variants in the same subject

Francesco Brigo, Paolo Manganotti, Antonio Fiaschi, Luigi Giuseppe Bongiovanni

Department of Neurological, Neuropsychological, Morphological and Movement Sciences, Section of Clinical Neurology, University of Verona, Italy

Received August 7, 2011; Accepted November 13, 2011

ABSTRACT – Rhythmic temporal theta bursts of drowsiness (RTTD), also known as “psychomotor variant”, and subclinical rhythmic EEG discharge of adults (SREDA) are two EEG patterns of uncertain significance that occur without any correlation with epilepsy. Each of these patterns has been described to occur alone and in the literature there are no previous reports of co-occurrence of the two distinct benign EEG variants in the same patient. We describe the coexistence of RTTD and SREDA in EEG recordings from the same subject. Although the coexistence of two distinct EEG variants in the same patient is a rarity, these patterns are not so infrequently encountered when present alone and should thus be promptly recognised in order to avoid misdiagnosis of epilepsy due to an over-interpretation of normal sharp patterns.

Key words: benign EEG variants, rhythmic temporal theta bursts of drowsiness, subclinical rhythmic EEG discharge of adults (SREDA)

Rhythmic temporal theta bursts of drowsiness (RTTD), also known as “psychomotor variant” or rhythmic midtemporal discharges, and subclinical rhythmic EEG discharge of adults (SREDA) are two EEG patterns of uncertain significance or “benign EEG variants” that occur without any correlation with epilepsy (Fisch, 1999; Mushtaq and Van Cott, 2005; Niedermeyer, 2005; Blume *et al.*, 2011). They are similar to each other in that they resemble epileptiform activity and are therefore likely to be misinterpreted as

true epileptiform patterns. As a consequence, it is important to properly recognise these variants in order to avoid misdiagnosis of epilepsy due to errors in EEG interpretation.

Each of these patterns has been described to occur alone and in the literature there are no previous reports of co-occurrence of the two distinct benign EEG variants in the same patient. Here, we describe the coexistence of RTTD and SREDA in EEG recordings from the same subject.

Correspondence:

Francesco Brigo
Department of Neurological,
Neuropsychological, Morphological
and Movement Sciences,
Section of Clinical Neurology,
University of Verona,
Piazzale LA Scuro,
10-37134 Verona, Italy
<dr.francescobrigo@gmail.com>

doi:10.1684/epd.2011.0471

Case report and description of EEG recordings

A 43-year-old woman was referred to our epilepsy centre for a diagnostic evaluation. Her medical history was unremarkable and neurological examination was normal. Some months before, she was referred to a neurologist because of some episodes of excessive daytime sleepiness occurring during a period of forced sleep deprivation. A standard and sleep EEG recording were performed and reported to be abnormal due to the presence of epileptiform left fronto-temporal discharges. Brain magnetic resonance imaging was completely normal. Despite the history, a diagnosis of probable epilepsy was made and an antiepileptic treatment with levetiracetam started.

In our EEG laboratory, the patient underwent an EEG recording which showed brief bursts of sharply contoured rhythmic and monomorphic waves at about 4-5 Hz, occurring prevalently in the left mid-anterior temporal region, and sometimes independently over contralateral homologous regions. These discharges lasted only a few seconds (mean: 3-4 seconds) (*figure 1A and B*), although sometimes in runs of longer duration (*figure 1C*), and occurred mostly during drowsiness without any variation in morphology, frequency or spatial distribution. They were identified as RTTD because they fulfilled the classic diagnostic criteria for this EEG variant (Westmoreland and Klass, 1990; Fisch, 1999; Mushtaq and Van Cott, 2005; Niedermeyer, 2005; Blume *et al.*, 2011). The same EEG pattern was recorded also in two subsequent standard and two sleep EEG recordings.

During a sleep EEG, in addition to RTTD, a completely different pattern was observed. This pattern consisted of an abrupt onset of monophasic, sharply-contoured delta (2-3 Hz) waveforms, prevalent in amplitude over parietal regions, which gradually evolved into a sustained rhythmic sinusoidal theta pattern (5-6 Hz). Amplitude was maximal from onset and remained constant. The average duration of the discharges was 20 seconds. The onset of this pattern was abrupt without postictal slowing or changes in EEG background activity. During the sleep EEG recording, this pattern occurred three times, twice during drowsiness (*figure 2A and B*) and once following a K complex with spindle (stage II NREM sleep) (*figure 2C*). This pattern, which had no evolution in frequency, morphology or distribution, was identified as SREDA since it fulfilled the classic diagnostic criteria for this pattern (Westmoreland and Klass, 1990; Fisch, 1999; Mushtaq and Van Cott *et al.*, 2005; Niedermeyer, 2005; Blume *et al.*, 2011).

Since the subject never had a seizure or any other episodes suggestive of an epileptic nature, and

because several EEG recordings never showed true epileptiform abnormalities, the diagnosis of epilepsy was reconsidered and questioned and levetiracetam was discontinued. At the most recent clinical visit, after 15 months follow-up, the woman reported that her daytime sleepiness ameliorated after levetiracetam withdrawal and normalisation of sleep-wake rhythm. The EEG recording showed exactly the same features as before.

Discussion

The co-occurrence of two normal EEG variants in the same subject has not previously been described in the literature. SREDA is a rare EEG pattern with a prevalence of 1 per 2500 recordings (Westmoreland and Klass, 1981), whereas RTTD is a more common EEG variant occurring in 0.1 to 2% of selected normal adults (Maulsby, 1979). Considering these epidemiological data, the coexistence of two distinct pseudoepileptiform variants may be indeed considered a rarity. In view of the fact that this appears to be the first report of the co-occurrence of these two benign EEG variants, the possibility of a causal association might be considered. Using Laplacian montages, O'Brien *et al.* (1998) demonstrated that the site of the SREDA activity is maximal in the parietal region or parieto-centrotemporal regions, whereas for non-SREDA discharges, including RTTD, it is maximal in the temporal or fronto-temporal regions. A subsequent source localisation study performed in a single patient (Zumsteg *et al.*, 2006) revealed a posterior hemispheric source localisation maximal in the parietal cortex bilaterally, in large part overlying the anatomical distribution of the vascular watershed areas. On the other hand, a magnetoencephalographic source modelling study (Lin *et al.*, 2003) indicated that the source of RTTD activity is located in the fissural cortex of the posterior inferior temporal region. As a consequence, is it reasonable to hypothesize that in our subject SREDA and RTTD originate from two different localised cortical generators.

The reported case is interesting not only for its EEG features, but also for its methodological implications concerning the reading and interpretation of the EEG, and illustrates the serious problem of over-interpretation of normal EEG patterns resulting in misdiagnoses of seizures. Prior to our investigation, misinterpretation of an otherwise normal EEG variant, despite the fact that the subject never had a seizure, led to a diagnosis of probable epilepsy. Diagnosing epilepsy without a consistent clinical history was indeed a mistake, however, the lack of recognition of a pseudoepileptiform benign EEG pattern was also a serious mistake which led to a

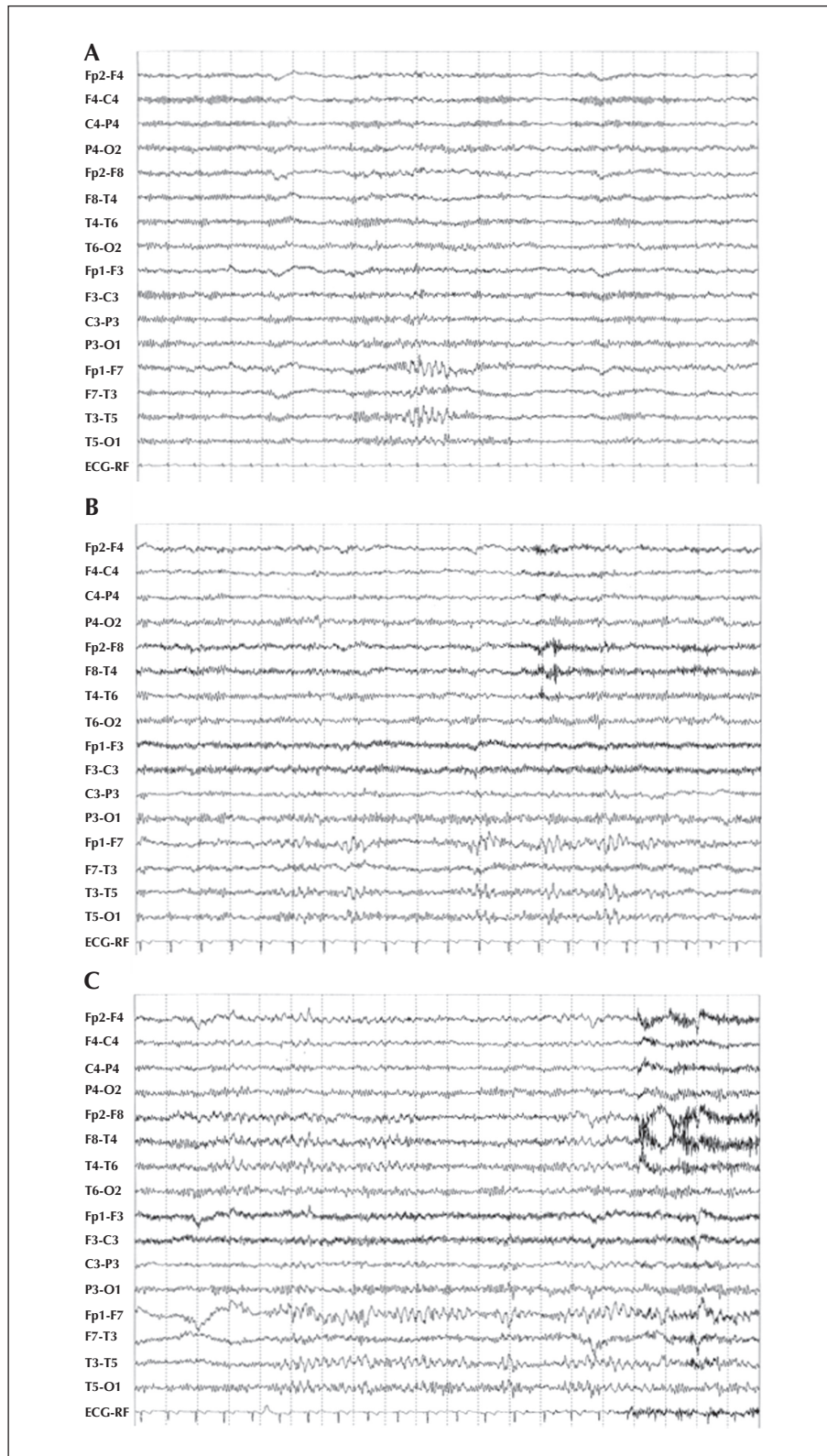


Figure 1. Examples of rhythmic temporal theta bursts of drowsiness lasting a few seconds (A and B) or occurring as runs of longer duration (C).
Speed: 20 sec/page; sensitivity: 7 $\mu\text{V}/\text{mm}$; HFF: 50 Hz; TC: 0.3 sec.

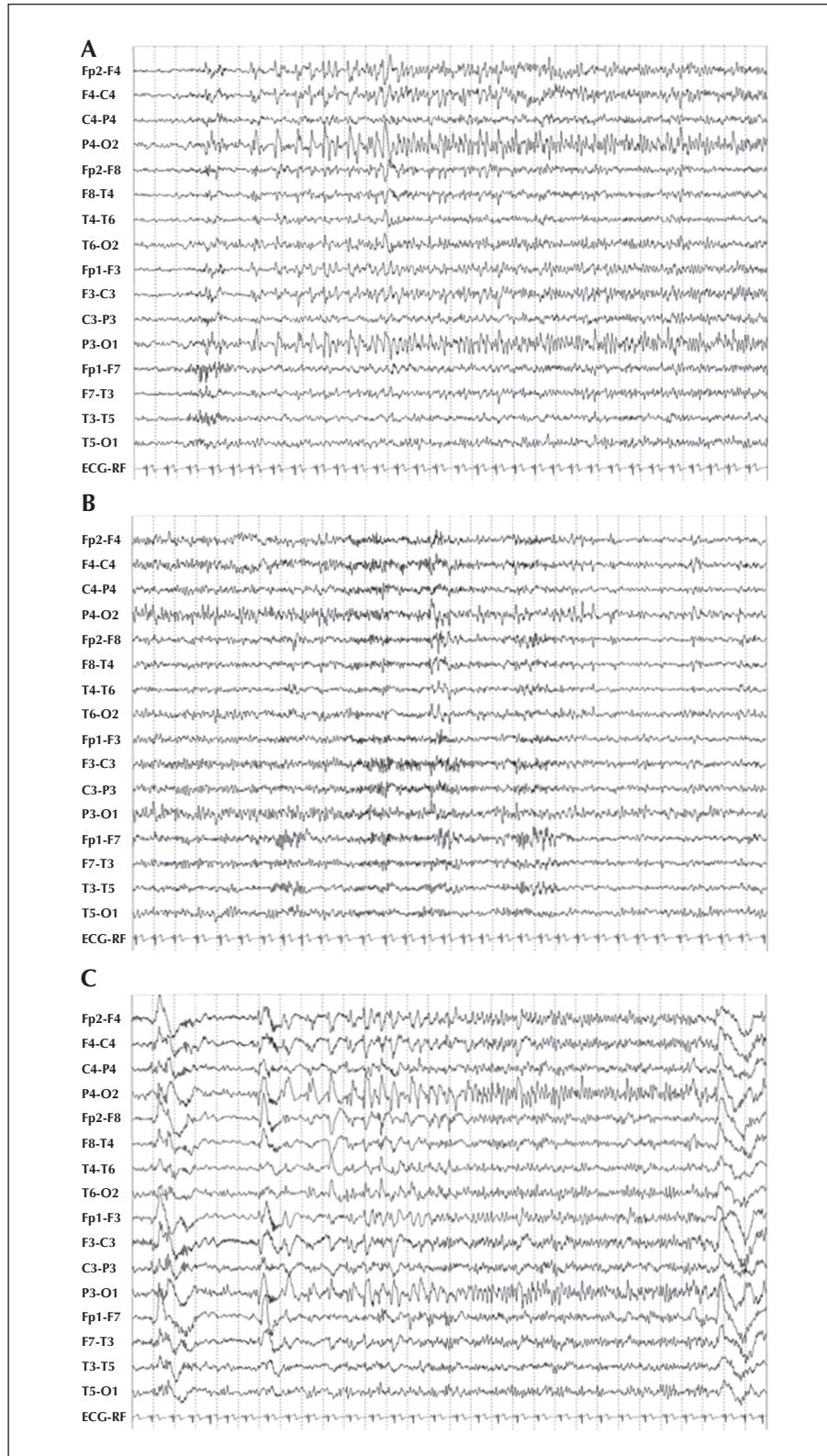


Figure 2. Subclinical rhythmic EEG discharge of adults occurring during drowsiness (A continuing into B) and stage II NREM sleep (C). Note the absence of changes in ECG rhythm. Speed: 30 sec/page; sensitivity: 7 μ V/mm; HFF: 50 Hz; TC: 0.3 sec.

misdiagnosis of epilepsy and ineffective, expensive and possibly harmful treatment. This case is therefore an example of misdiagnosis of epilepsy due to errors in EEG interpretation, a scenario often subsequently encountered at specialist epilepsy referral centres.

Misdiagnosis of epilepsy, in particular, may occur when the electroencephalographer reads the EEG with the knowledge of the patient's history, being therefore influenced and even biased by this information (so-called "history bias"), thus trying "too hard" to find EEG abnormalities (Benbadis, 2007). In this context, normal EEG patterns, such as those presented by our subject, may be erroneously over-read as true epileptiform discharges. To reduce the history bias, a relatively blind approach to EEG interpretation has been previously suggested and recommended; EEG should be initially read blind with regards to the patient's history (Benbadis, 2007; Brigo, 2011a; Brigo, 2011b) and the subsequent report interpreting the EEG findings should take full account of the history and context. Moreover, the EEG should be read by an expert electroencephalographer who is fully aware of the existence and EEG features of benign pseudoepileptiform patterns. A misdiagnosis of epilepsy may have serious clinical consequences; an "abnormal" EEG is too often considered as an irrevocable sentence of epilepsy, leading to antiepileptic treatment which is not only ineffective, but also expensive and sometimes harmful for the patient.

In conclusion, although the coexistence of two distinct EEG variants in the same patient is a rarity, these patterns are not so infrequently encountered when present alone and thus should promptly be recognised in order to avoid misdiagnosis of epilepsy due to an over-interpretation of normal sharp patterns. □

Disclosure.

None of the authors has any conflict of interest to disclose.

References

Benbadis SR. Errors in EEGs and the misdiagnosis of epilepsy: importance, causes, consequences, and proposed remedies. *Epilepsy Behav* 2007; 11: 257-62.

Blume WT, Holloway GM, Kaibara M, Young GB. Normal EEG. In: Blume WT, Holloway GM, Kaibara M, Young GB. *Atlas of Pediatric and Adult Electroencephalography*. Philadelphia: Lippincott Williams & Wilkins, 2011: 73-4.

Brigo F. We should not treat the EEG, but we should read it blind to the patient's history. *Epilepsy Behav* 2011a; 20: 146.

Brigo F. An evidence-based approach to proper diagnostic use of the electroencephalogram for suspected seizures. *Epilepsy Behav* 2011b; 21: 219-22.

Fisch BJ. Epileptiform patterns without proven relation to seizures. In: Fisch BJ. *Fisch & Spehlmann's EEG Primer: Basic Principles of Digital and Analog EEG*. Elsevier: Amsterdam, 1999: 336-48.

Lin YY, Wu ZA, Hsieh JC, et al. Magnetoencephalographic study of rhythmic mid-temporal discharges in non-epileptic and epileptic patients. *Seizure* 2003; 12: 220-5.

Maulsby RL. EEG patterns of uncertain diagnostic significance. In: Klass D. *Current Practice of Clinical Electroencephalography*. Raven Press: New York, 1979: 411-49.

Mushtaq R, Van Cott AC. Benign EEG variants. *Am J Electroneurodiagnostic Technol* 2005; 45: 88-101.

Niedermeyer E. Abnormal EEG Patterns: Epileptic and Paroxysmal. In: Niedermeyer E, Lopes da Silva F. *Electroencephalography: Basic Principles, Clinical Applications, and Related Fields*. Baltimore: Williams & Wilkins, 2005: 267-8.

O'Brien TJ, Sharbrough FW, Westmoreland BF, Busacker NE. Subclinical rhythmic electrographic discharges of adults (SREDA) revisited: a study using digital EEG analysis. *J Clin Neurophysiol* 1998; 15: 493-501.

Westmoreland BF, Klass DW. A distinctive rhythmic EEG discharge of adults. *Electroencephalogr Clin Neurophysiol* 1981; 51: 186-91.

Westmoreland BF, Klass DW. Unusual EEG patterns. *J Clin Neurophysiol* 1990; 7: 209-28.

Zumsteg D, Andrade DM, Del Campo JM, Wennberg R. Parietal lobe source localization and sensitivity to hyperventilation in a patient with subclinical rhythmic electrographic discharges of adults (SREDA). *Clin Neurophysiol* 2006; 117: 2257-63.