

# Electroclinical and cytogenetic features of epilepsy in cri-du-chat syndrome

Yukako Nakagami<sup>1,2</sup>, Kiyohito Terada<sup>1</sup>, Hitoshi Ikeda<sup>1</sup>, Toshio Hiyoshi<sup>1</sup>, Yushi Inoue<sup>1</sup>

<sup>1</sup> National Epilepsy Center, NHO Shizuoka Institute of Epilepsy, Neurological Disorders, Shizuoka

<sup>2</sup> Department of Psychiatry, Kyoto University Graduate School of Medicine, Kyoto, Japan

Received May 21, 2015; Accepted September 12, 2015

**ABSTRACT** – Cri-du-chat syndrome (CdCs) is caused by deletion in the short arm of chromosome 5, occurring in 1:15,000 to 1:50,000 live births. Recent genotype-phenotype correlation studies show the importance of 5p15.2 for facial dysmorphism and intellectual disability, and 5p15.3 for cat-like cry. Numerous reports have shown the relative rarity of epilepsy in this syndrome. We identified two cases with epilepsy in CdCs, and described their electroclinical and cytogenetic features. The first case was a 25-year-old female who had axial tonic seizures with flexion of the neck and shoulders. Interictal EEG was characterized by generalized spike-and-slow-wave complexes. Her ictal EEG started with diffuse electrodecremental pattern, followed by alpha-range activities. High-resolution banding analysis of chromosomes revealed a terminal deletion of 5p14.1. The second case was a 30-year-old female who had startle epilepsy with falling. Interictal EEG demonstrated generalized spike and slow waves. High-resolution banding analysis revealed a terminal deletion of 5p13.3 with additional chromosomal material of unknown origin. Based on the cases presented here, as well as those previously reported, the relationship between epilepsy and CdCs is discussed. The data suggests that although CdCs patients rarely suffer from epileptic seizures, the seizures may vary in type.

**Key words:** cri-du-chat syndrome, epilepsy, chromosomal disorder, cytogenetic analysis, electroclinical features, startle epilepsy

Cri-du-chat syndrome (CdCs), also referred to as 5p deletion syndrome, is a syndrome caused by total or partial deletion in the short arm of chromosome 5. Its rate of occurrence is estimated at 1:15,000 to 1:50,000 newborns (Rodriguez-Caballero *et al.*, 2010). The syndrome is named after its characteristic feature of a high-pitched cat-like cry, although this symptom usually diminishes in the first years

of life. In addition to this cat-like cry, there are various features of CdCs: a round face, separated eyes, epicanthic folds, small jaw, and developmental delay, including difficulties in mobility, dexterity, and verbal communication. Recently, genotype-phenotype correlation studies in CdCs have been performed. The deletion of 5p15.2 plays an important role in facial dysmorphism, neonatal hypotonia,

**Correspondence:**

Yukako Nakagami  
National Epilepsy Center,  
NHO Shizuoka Institute of Epilepsy and  
Neurological Disorders,  
Urushiyama 886, Aoi-ku,  
Shizuoka 420-8688, Japan  
<nakagami-kyt@umin.ac.jp>

intellectual disability, and growth retardation, while the deletion of 5p15.3 plays a role in the cat-like cry and speech delay. Two genes, semaphorin F (*SEMAF*) and  $\delta$ -catenin (*CTNND2*), believed to play a role in cerebral development (Cerruti Mainardi, 2006), are reported to be implicated in CdCs with intellectual disability.

However, in contrast to other genetic syndromes with intellectual disability, the concomitance of epilepsy or seizures with CdCs is reported at 0-16% and relatively rare (Niebuhr, 1978; Cornish and Pigram, 1996; Cerruti Mainardi et al., 2006; Rodriguez-Caballero et al., 2010), and only sporadic cases have previously been reported (Johnson et al., 2000; Kumada et al., 2005; Tsao et al., 2005).

In addition, we found only two cases of CdCs among over 800 epilepsy patients in our hospital who had undergone chromosomal analysis. Moreover, as far as we searched, there is no reported study on electro-clinical or cytogenetic features of epilepsy in CdCs. In order to investigate this, we report two patients and review the published cases.

## Case studies

The first case was a 25-year-old, ambidextrous female. Pregnancy was normal and the patient was born with a birth weight of 2,680 g at 38 weeks gestation. The baby began to crawl at 12 months and was able to pull herself up at 18 months, but did not begin to use words. Due to these developmental delays, she underwent a cytogenetic study and was diagnosed with CdCs. At the age of seven years, she developed her first generalized tonic-clonic seizure (GTCS), and antiepileptic drugs (AEDs) were administered. She reportedly presented with multiple seizure types, such as GTCSs, atonic seizures, and tonic seizures. At the time of her admission to our hospital at 25 years of age, axial tonic seizures still occurred everyday while she was taking phenytoin (PHT), levetiracetam (LEV), and gabapentin (GBP). She had a small head, a round face, and widely-set eyes. During wakefulness, she would typically swing her body to the right and left, silently, on hands and knees. She could walk but was unsteady. She could not understand or obey what was said to her. She had no pathological reflex, muscle weakness, or dysfunction of cranial nerves, however, precise evaluation was difficult due to severe intellectual disability.

Blood tests showed no abnormalities, and brain MRI showed only slight atrophy of the brainstem. High-resolution banding analysis revealed a terminal deletion of 5p14.1 (*figure 1A*), and fluorescence *in situ* hybridisation (FISH), using a probe directed to the CdCs locus at 5p15.2, showed this deletion (*figure 1B*).

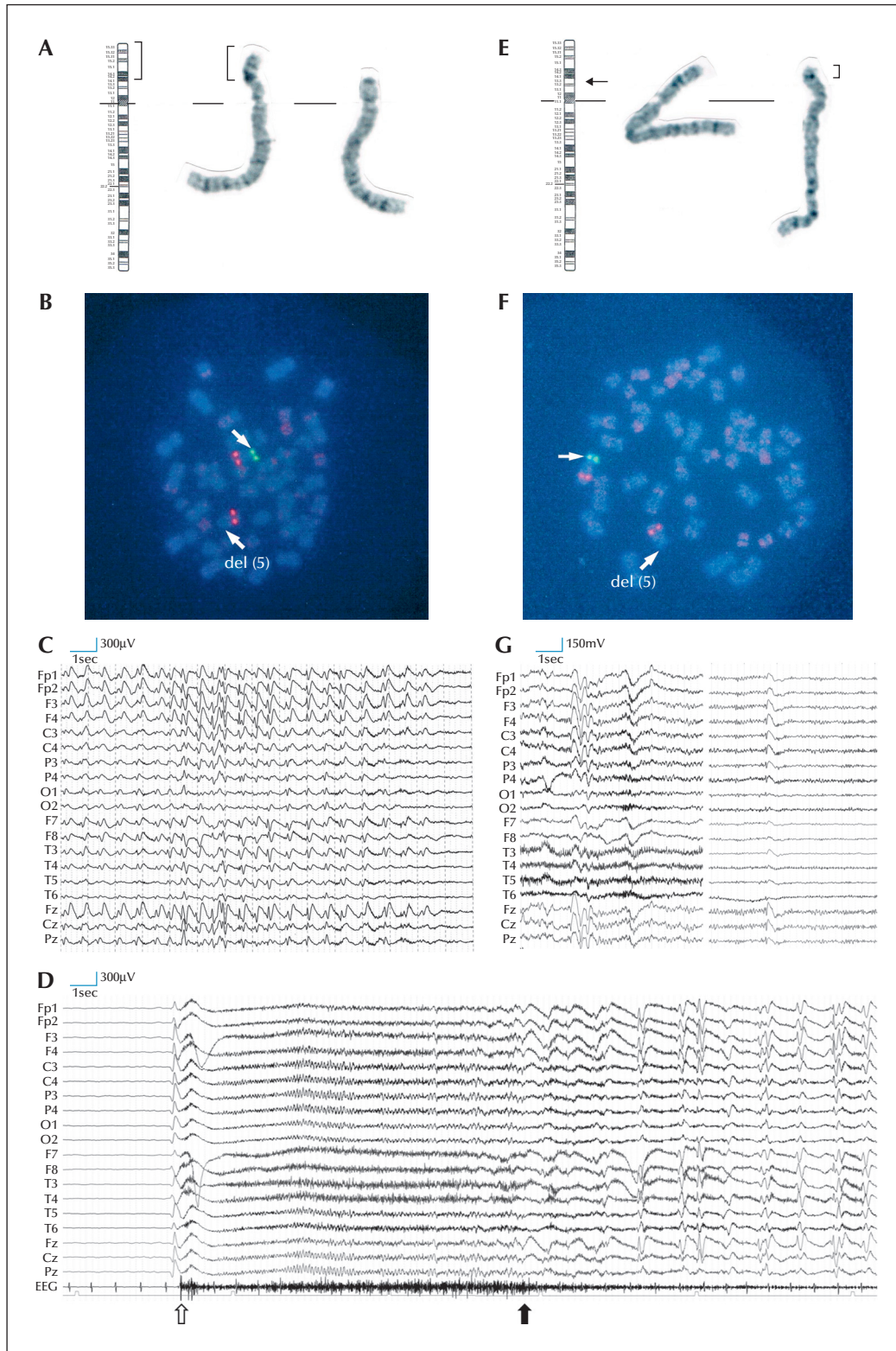
Video-EEG monitoring was conducted for 40 hours, and 27 seizures were captured which consisted of flexion of the neck and shoulders. An interictal EEG was characterized by the frequent high-amplitude generalized spike and slow wave bursts (*figure 1C*). Ictal EEGs started with asymmetric generalized slow waves followed by a diffuse electrodecremental pattern for a few seconds. Then, generalized alpha-range activities started with increasing amplitude and decreasing frequency. Finally, both the activity and the clinical symptom stopped at the same time (*figure 1D*). An adjustment of AEDs, including administration of valproate (VPA) and discontinuation of LEV and GBP, was effective, and her seizure frequency decreased from daily to weekly.

The second case was a 30-year-old, right-handed female, born uneventfully with a weight of 2,740 g and head circumference of 30.5 cm at 40 weeks gestation. She held up her head at five months, and began to walk at three years of age. These delays, along with a suckling disorder, prompted chromosomal analysis, and CdCs was diagnosed. She had a history of febrile convulsions and underwent cardiac surgery for patent ductus arteriosus at the age of two years. She also had a small head, a round face, and widely-set eyes, without apparent neurological abnormalities. Hyperactivity was prominent, and she had no meaningful utterance. She could walk, although unsteady, without any help, but sometimes she rushed forward. Brain computed tomography revealed no abnormalities. The score of developmental quotients (DQ) was 14 at age 20 years, indicating severe intellectual disability. High-resolution banding analysis revealed a terminal deletion of 5p13.3 with additional chromosomal material of unknown origin (*figure 1E*), and FISH analysis demonstrated the deletion of 5p15.2 (*figure 1F*).

From the age of 11 years, the patient had frequent falls when she was surprised by unexpected tactile or visual stimuli. Combination therapy, consisting of VPA and PHT, stopped the falls, while EEG continued to show generalized spike and slow waves (*figure 1G*). An attempt to reduce AEDs in response to requests from her parents resulted in the reappearance of seizures that were again well controlled by the administration of the same AEDs.

## Discussion

The risk of epilepsy varies among genetic disorders. The group with the highest risk (greater than 75%) includes disorders such as Angelman syndrome, Sturge-Weber syndrome, tuberous sclerosis, or MELAS syndrome.



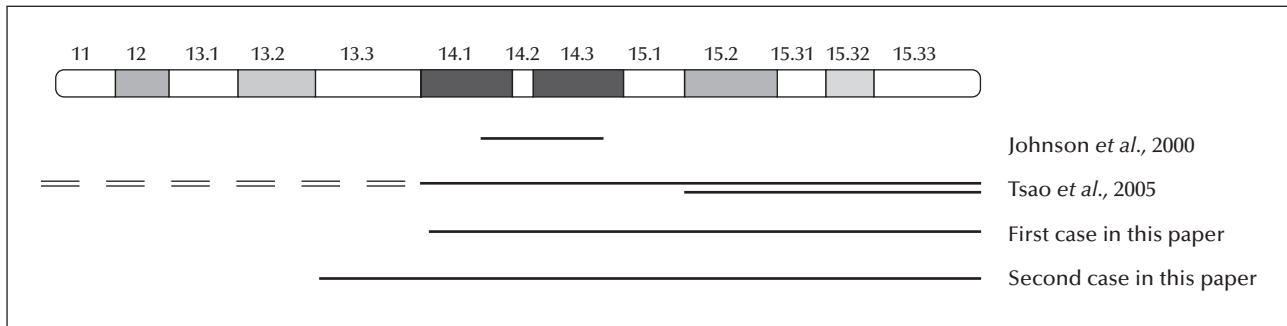
**Figure 1.** Cytogenetic analysis and EEG. (A) Case 1: high-resolution banding analysis indicated a terminal deletion of 5p14.1. (B) Case 1: FISH analysis of 5q31 (Red) and 5p15.2 (Green) revealed a deletion of 5p15.2. (C) Interictal EEG of Case 1: high-amplitude generalized spike and slow wave bursts. (D) Ictal EEG of Case 1: ictal EEG showed diffuse electrodecremental pattern after sudden asymmetric generalized slow waves. Then, alpha-range activity appears with increasing amplitude and decreasing frequency. Clinically, flexion of the neck and shoulders started. The onset is indicated with a white arrow. The alpha-range activity lasted about 11 seconds and

**Figure 1. (Continued)** suddenly stopped. At the same time, her clinical symptom also diminished, indicated by a black arrow. Then, high-amplitude generalized spike and slow wave bursts followed. (E) Case 2: high-resolution banding analysis revealed a terminal deletion of 5p13.3 with additional chromosomal material of unknown origin. (F) Case 2: FISH analysis of 5q31 (Red) and 5p15.2 (Green) revealed a deletion of 5p15.2. (G) Interictal EEG of Case 2: generalized spike and slow waves.

**Table 1.** Epileptological and cytogenetic features in cases related to 5p deletion.

Case	Age	Sex	Age at seizure onset	Seizure type	Interictal EEG	Ictal EEG	Cytogenetics	Reference
1	3y	M	17m	generalized tonic-clonic seizures	n.a	n.a	46,XY(1%)/46,XY,del(5)(p14)(99%); deletion between 5p14.1 and 14.3 (FISH)	Johnson <i>et al.</i> , 2000
2	13y	F	2y/2m	febrile seizures, complex partial seizures	multifocal spikes	n.a	46,XX,5p-	Kumada <i>et al.</i> , 2005
3	3y	F	8m	complex partial seizures (apnoea) and myoclonic seizures	bilateral occipital and diffuse spike and waves	n.a	46,XX, -5, +der(5)t(5;13)(p14.2;q31.1)	Kumada <i>et al.</i> , 2005
4	3y	F	3m	flexor spasms and generalized tonic-clonic seizures	hypsarrhythmia	electrodecremental pattern	mos46,XX, der(5)del(5)(p14)inv(5)(p14q32)[25]/46,XX,del(5)(p15.2)[7]; deletion of 5p15.2 (FISH)	Tsao <i>et al.</i> , 2005
5	25y	F	7y	generalized tonic-clonic seizures, atonic seizures and tonic seizures	generalized spike and slow wave bursts	asymmetric generalized slow waves followed by diffuse electrodecremental pattern	46,XX,del(5)(p14.1);terminal deletion of 5p14.1; deletion of 5p15.2 (FISH)	Case 1 (this report)
6	30y	F	11y	febrile seizures, startle seizures with falling	generalized spike and slow waves	n.a	46,XX,add(5)(p13.3); deletion of 5p15.2 (FISH)	Case 2 (this report)

n.a: not available; y: year; m: month; M: male; F: female.



**Figure 2.** Schematic representation of cases with epilepsy identified in this study and by Johnson *et al.* (2000) and Tsao *et al.* (2005). A case reported by Johnson *et al.* and Case 1 had generalized tonic-clonic seizures. Tsao *et al.* reported infantile spasms and hypsarrhythmia. Case 2 had startle epilepsy with falls. In the case reported by Tsao *et al.*, most of the cells examined exhibited terminal deletion at both ends distal to band 5p14 and pericentric inversion between 5p14 and 5q32 bands, while some had terminal deletion from 5p15.2.

In addition, disorders associated with specific chromosomal abnormalities, such as Wolf-Hirschhorn syndrome (4p-), inversion duplication 15 syndrome (IDIC15), and ring 14 and 20 syndromes, are strongly related to epilepsy (Engel, 2013). Some genetic disorders, on the other hand, are classified with no increased risk of epilepsy, including Lesh-Nyhan syndrome, mucopolysaccharidoses, Williams syndrome, sex chromosome aneuploidies, and CdCs (Bonkowsky *et al.*, 2008), however, 5p duplication, and not 5p deletion, is reported to be associated with seizures (Loscalzo *et al.*, 2008).

According to a survey in 1978, the prevalence of seizures was 2.7% based on 331 patients with CdCs (Niebuhr, 1978). However, according to a report from the Italian Register, 25 of 159 patients with CdCs developed seizures, with an occurrence rate of 15.7% (Cerruti Mainardi *et al.*, 2006). These studies showed the higher incidence of epilepsy in CdCs relative to the prevalence in an age-matched population (0.625% in the United States), however, CdCs is classically reported to have no associated risk of epilepsy (Bonkowsky *et al.*, 2008; Engel, 2013).

In order to reveal electroclinical and cytogenetic features of epilepsy in CdCs, we analysed published cases of epilepsy in CdCs patients. After exclusion of cases that lacked detailed information about epilepsy (including the previously mentioned cases from the Italian Register), there remained four published cases in addition to the two current cases (*table 1*) (Johnson *et al.*, 2000; Kumada *et al.*, 2005; Tsao *et al.*, 2005). In the six cases, electroclinical features varied so widely that it was difficult to determine any common features.

As for chromosomal analysis, four cases had abnormalities only on chromosome 5 which were described in detail (*figure 2*). Schematic representation and comparison revealed that all the cases with epilepsy included the deletion of 5p14. Thus, 5p14 is possibly related to

epilepsy in CdCs. However, as there is a report that families with interstitial deletion of 5p14 were completely asymptomatic (Overhauser *et al.*, 1986), and most cases of CdCs patients are free of seizures, further research is needed to identify more precisely the cause of epilepsy associated with this disorder. □

#### Supplementary data.

Summary didactic slides are available online on the [www.epilepticdisorders.com](http://www.epilepticdisorders.com) website.

#### Disclosures.

None of the authors have any conflict of interest to disclose.

#### References

- Bonkowsky JL, Nance MA, Hauser W, Anderson VE. Genetic diseases associated with epilepsy. In: Engel J, Pedley TA. *Epilepsy: A comprehensive textbook*. Second edition. Philadelphia Wolters Kluwer Health/Lippincott Williams & Wilkins, 2008: 183-93.
- Cerruti Mainardi P. Cri du chat syndrome. *Orphanet J Rare Dis* 2006; 1: 33.
- Cerruti Mainardi P, Pastore G, Castronovo C, *et al.* The natural history of cri du chat syndrome. A report from the Italian Register. *Eur J Med Genet* 2006; 49(5): 363-83.
- Cornish KM, Pigram J. Developmental and behavioural characteristics of cri du chat syndrome. *Arch Dis Child* 1996; 75(5): 448-50.
- Engel J. Causes of human epilepsy. In: Engel J. *Seizures and Epilepsy*. Second Edition. New York: Oxford University Press, 2013: 45-52, 157-90.
- Johnson EI, Marinescu RC, Punnett HH, Tenenholz B, Overhauser J. 5p14 deletion associated with microcephaly and seizures. *J Med Genet* 2000; 37(2): 125-7.
- Kumada T, Ito M, Miyajima T, *et al.* Multi-institutional study on the correlation between chromosomal abnormalities and epilepsy. *Brain Dev* 2005; 27(2): 127-34.

Loscalzo ML, Becker TA, Sutcliffe M. A patient with an interstitial duplication of chromosome 5p11-p13.3 further confirming a critical region for 5p duplication syndrome. *Eur J Med Genet* 2008; 51(1): 54-60.

Niebuhr E. The cri du chat syndrome: epidemiology, cytogenetics, and clinical features. *Hum Genet* 1978; 44(3): 227-75.

Overhauser J, Golbus MS, Schonberg SA, Wasmuth JJ. Molecular analysis of an unbalanced deletion of the short arm of chromosome 5 that produces no phenotype. *Am J Hum Genet* 1986; 39(1): 1-10.

Rodriguez-Caballero A, Torres-Lagares D, Rodriguez-Perez A, Serrera-Figallo MA, Hernandez-Guisado JM, Machuca-Portillo G. Cri du chat syndrome: a critical review. *Med Oral Patol Oral Cir Bucal* 2010; 15(3): e473-8.

Tsao CY, Wenger GD, Bartholomew DW. Cri du chat syndrome and complex karyotype in a patient with infantile spasms, hypsarrhythmia, nonketotic hyperglycemia, and heterotopia. *Am J Med Genet A* 2005; 134A(2): 198-201.

## TEST YOURSELF



- (1) What is the aetiology of cri-du-chat syndrome (CdCs)?
- (2) What is the incidence rate of epilepsy in patients with CdCs?
- (3) Is there clinical heterogeneity with regards to the epilepsy of patients with CdCs?

*Note: Reading the manuscript provides an answer to all questions. Correct answers may be accessed on the website, [www.epilepticdisorders.com](http://www.epilepticdisorders.com), under the section "The EpiCentre".*