

# Epileptic spasms: a previously unreported manifestation of *WDR45* gene mutation\*

Kathryn I Xixis<sup>1</sup>, Mohamad A Mikati<sup>2</sup>

<sup>1</sup> Division of Pediatric Neurology, Department of Pediatrics, Duke University Medical Center, Durham, North Carolina

<sup>2</sup> Division of Pediatric Neurology, Department of Pediatrics, Duke University Medical Center, Durham, North Carolina, USA

Received June 19, 2015; Accepted September 30, 2015

**ABSTRACT** – *WDR45* mutations cause neurodegeneration with brain iron accumulation, usually presenting with early childhood developmental delay and followed by early adulthood extrapyramidal symptoms. Although various seizure types may occur, epileptic spasms have not been reported for this disease. Our patient initially developed a prolonged, focal-onset seizure at three months of age and was subsequently noted to have psychomotor delay. At 11 months of age, she developed epileptic spasms. Her EEG showed hypsarrhythmia. An extensive neurogenetic workup and brain MRI, revealing normal data, ruled out other detectable causes of epileptic spasms. Whole-exome sequencing revealed a *de novo*, heterozygous deleterious mutation c.400C>T (p.R134X) in *WDR45*, previously reported to be disease-causing and associated with early childhood global developmental delay and seizures other than epileptic spasms. We conclude that *WDR45* mutations should be considered as a possible aetiology in infants with early-onset focal seizures and/or in otherwise undiagnosed cases of epileptic spasms.

**Key words:** *WDR45*, neurodegeneration with brain iron accumulation (NBIA), epileptic spasms, beta-propeller protein-associated neurodegeneration (BPAN)

The *WDR45* gene is one of several genes, of which the mutations are reported to cause neurodegeneration with brain iron accumulation (NBIA). This mutation results in an X-linked dominant disease subtype termed beta-propeller protein-associated neurodegeneration (BPAN) disease (Hayflick *et al.*, 2013). The typical presentation consists of

developmental delay, psychomotor slowing, and limitations in expressive language in early childhood. Later, dystonia, Parkinsonism, and epilepsy occur. Early in the disease course, brain imaging is normal. A review of the literature reveals various types of seizures including focal, absence, atonic, febrile, and myoclonic seizures (*table 1*).

**Correspondence:**

Mohamad A Mikati  
Division of Pediatric Neurology,  
Department of Pediatrics,  
Duke University Medical Center,  
DUMC 3936, Durham,  
North Carolina 27710, USA  
<mohamad.mikati@duke.edu>

\* This study was presented in the form of a poster presentation at the 13<sup>th</sup> International Child Neurology Congress in Brazil, in May 2014.

**Table 1.** Characteristics of seizures in patients with *WDR45* mutations.

Reference	Patient	Type of Seizures	Age at Onset of Seizures	Treatment of Seizures	Initial Presenting Symptom(s)
<b>Hayflick <i>et al.</i>, 2013<sup>a</sup></b>	Patients 1, 2, 3, 9, 10, 11, 13	Staring, absence, or atonic	Childhood	NA	NA
	Patients 4, 6, 7, 12	Febrile	Childhood	NA	NA
	Patient 5	Staring, absence, or atonic, febrile	Childhood	NA	NA
	Patient 8	Myoclonic	Childhood	NA	NA
<b>Verhoeven <i>et al.</i>, 2014</b>	Patient 1	Focal	Childhood	No treatment initiated	Slow motor development in infancy followed by suspicion of focal epileptic seizures in early childhood
	Patient 2	Absence in childhood, mixture of absence, tonic-clonic, and tonic in adulthood	13 years	Initially controlled on valproate, switched at age 47 to carbamazepine due to breakthrough seizures	Significant developmental delay and disinhibited behaviours in early childhood
<b>Saitou <i>et al.</i>, 2013<sup>b</sup></b>	Patients 1, 2, 3	Epileptic seizures	NA	NA	Psychomotor retardation
	Patient 4	Seizure in the setting of fever	NA	NA	Psychomotor retardation
<b>Rathore <i>et al.</i>, 2014<sup>c</sup></b>	Patient 1	Seizures	Childhood	NA	Global developmental delay, spastic quadriparesis at age 2
<b>Horvath, 2013<sup>c</sup></b>		Focal, atonic, absence, generalized tonic-clonic, myoclonic	Childhood	NA	
<b>Haack <i>et al.</i>, 2013<sup>c</sup></b>		Complex partial, atonic, absence, generalized tonic-clonic	Childhood	NA	

<sup>a</sup>Information on treatment of seizures was not included; patients were diagnosed with global developmental delay in infancy or early childhood, and symptom(s) that first brought patients to medical attention were not specified for each patient.

<sup>b</sup>Information regarding age at seizure onset and treatments for seizures were not included.

<sup>c</sup>Information on treatment of seizures was not included.

NA: Information was not available.

To date, epileptic spasms have not been reported to be associated with *WDR45* mutation. In this article, we report a patient with such a presentation.

## Case study

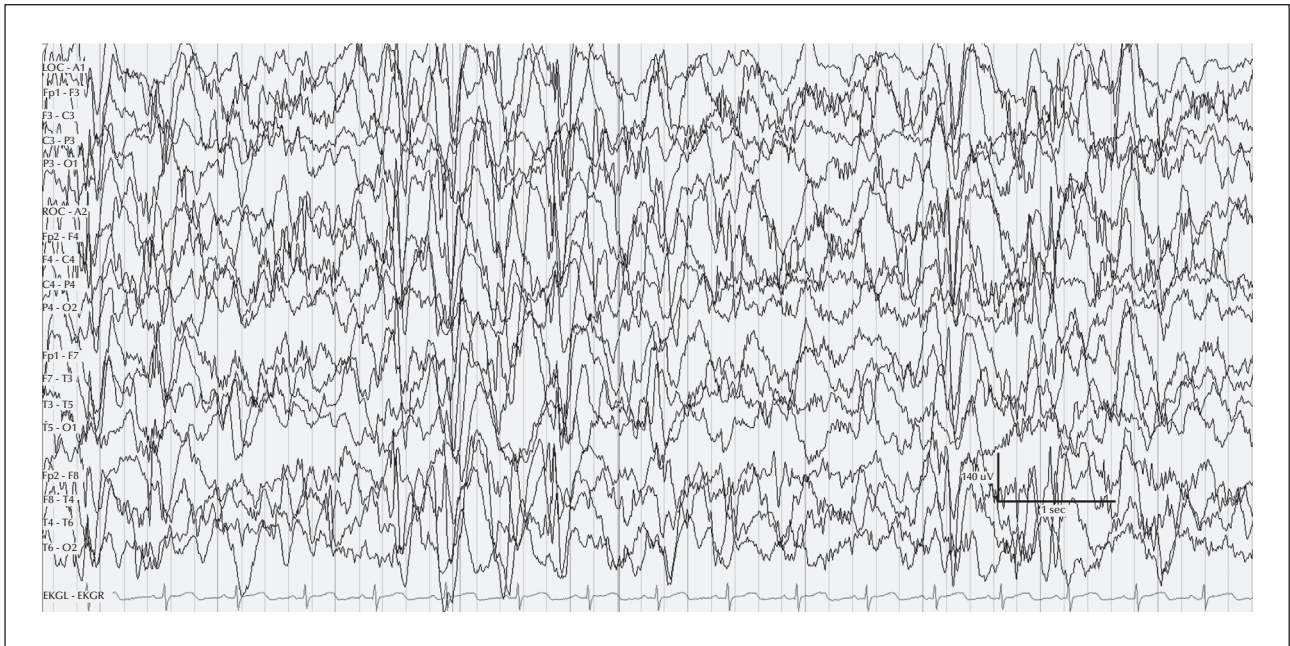
Our patient was a six-year-old female who was born at term with delivery complicated only by pre-eclampsia. The patient did well until the age of three months when she presented to a healthcare centre with a cluster of focal, febrile seizures consisting of right-sided, tonic-clonic activity, right gaze preference, and right-sided versive head deviation lasting several hours. The patient underwent a laboratory workup for infectious diseases and brain MRI without contrast, which were negative. A routine EEG showed left-sided slowing seizure activity. Phenobarbital was started but was subsequently weaned off three months later after a repeat routine EEG was normal. Despite seizure freedom, the patient was noted to have ongoing global developmental delay throughout her first year of life. At one year of age, the patient was unable to sit independently and was diffusely hypotonic. Additionally, her head circumference percentile was decreasing.

Epileptic spasms started at 11 months of age. These consisted of intermittent, isolated, brief episodes of stiffening and brief episodes of myoclonic jerking of the bilateral upper extremities, each lasting for one second or less. A repeat EEG showed a mixed-frequency, high-amplitude background with 3-5-Hertz activity predominating. During the subsequent months, these jerks persisted. By the age of 21 months, they were occurring in clusters of repetitive brief episodes of bilateral arm extension, two to three times per day, and most commonly upon awakening from sleep. These were initially treated with levetiracetam and then with zonisamide that was up-titrated to a dose of 13 mg/kg/day. The patient was also supplemented with high-dose vitamin B6 at a dose of 30 mg/kg/day. The patient responded with a reduction in the number of spasms per cluster but continued to have approximately four clusters per day with intervening periods of a few days to a few weeks without spasms. Developmentally, the patient began to make slow gains such that she eventually was able to start babbling, crawling, standing with assistance, pointing to indicate certain desires, feeding herself finger foods, and understanding “no” inconsistently. Given this improvement, the patient was tapered off vitamin B6 but was continued on zonisamide.

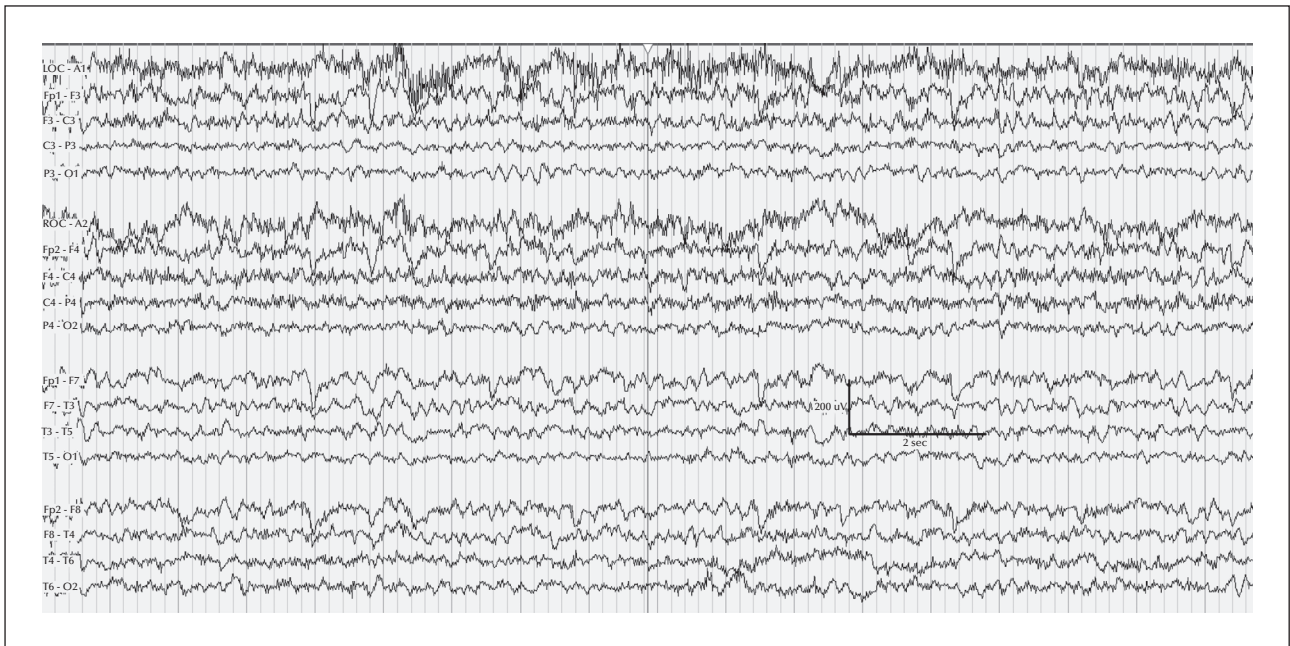
At the age of three years and eight months, the patient experienced an exacerbation with the recurrence of daily spasms. These consisted of head flexion with bilateral arm extension occurring in clusters of

approximately four spasms per cluster and seven to ten clusters per day. She also developed tonic seizures during sleep occurring once a week and consisting of full-body stiffening and facial grimacing, lasting a few seconds. The patient then presented to our institution for a second opinion. Her examination showed developmental delay as described above, no definite hand preference, and moderate central hypotonia. Reflexes were 2+ bilaterally and plantar responses were flexor. EEG showed hypsarrhythmia with a diffuse, high-voltage, disorganized, slow background and with multifocal spikes in wakefulness and sleep (*figure 1*). Parents declined steroid or vigabatrin therapy. Medication trials with topiramate, rufinamide, clobazam, and clonazepam failed to change the frequency of her spasms or her tonic seizures. EEG continued to show hypsarrhythmia in wakefulness and sleep. The patient's development was not progressing. She was thus started on the ketogenic diet which led to a significant decrease in spasms during the month following initiation of the diet, with continued reduction in spasms to seizure freedom by the sixth month of the diet. Her EEG, four months after starting the ketogenic diet, showed only bilateral, independent, interictal spike discharges in the right frontal and left temporal regions with mild bilateral slowing. After eight months on the ketogenic diet, the EEG showed only mild background slowing. The patient has currently been on the diet for 14 months and has continued to be spasm-free for the last eight months. She also is making developmental progress. She is now able to stand independently for five minutes, take one to two independent steps, recognize some people around her, and communicate with augmentative devices and signs. The patient's physical examination is unchanged except for a finding of mildly increased tone in the lower extremities. Her EEG at the time of the last follow-up visit at age six years showed only mild diffuse slowing and no hypsarrhythmia (*figure 2*).

Extensive laboratory workup to investigate the aetiology of the patient's seizures was unremarkable with the exception of whole-exome sequencing. This included tests for: CPK, lactate, ammonia, plasma amino acids, urine organic acids, acylcarnitine profile, biotinidase, carbohydrate deficient transferrin, urine creatine/guanidinoacetate, as well as karyotyping, chromosomal microarray, *SCN1A* gene sequencing, *MECP2* deletion/duplication testing, *MECP2* gene sequencing, Prader Willi and Angelman syndrome methylation tests, *TSC1* and *TSC2* gene sequencing, and cerebrospinal fluid studies for cell count, glucose (with normal CSF to serum ratio), protein, lactate, amino acids, neurotransmitter metabolites (5-HIAA, HVA, 3-O-methyldopa), tetrahydrobiopterin, neopterin, 5-methyltetrahydrofolate, and oligoclonal



**Figure 1.** EEG of the patient at three years and eight months showing hypsarrhythmia.



**Figure 2.** EEG of the patient at six years of age showing a background of only diffuse theta and no epileptiform activity.

bands. The presence of infectious diseases, including EBV, CMV, VZV, HSV, HHV6, enterovirus, and Cryptococcus antigen, were also investigated in CSF and were all negative. Whole-exome sequencing was significant for a heterozygous deleterious mutation c.400C>T (p.R134X) in *WDR45* which was not present in either of the patient’s parents and was therefore felt to arise *de*

*novo* in our patient. This specific mutation has been previously reported to be disease-causing in BPAN or NBIA5 with the accompanying phenotype of global developmental delay starting in early childhood, slow gains in motor and cognitive skills in adolescence, and progression to dystonia, Parkinsonism, and dementia in young adulthood (Haack *et al.*, 2012).

## Discussion

Since the discovery of the *WDR45* gene, studies have delineated the common phenotypic manifestations associated with mutation in this gene (Haack *et al.*, 2012; Haack *et al.*, 2013; Hayflick *et al.*, 2013). Our patient presented with many of the characteristics previously described in relation to this mutation. These included global developmental delay in childhood, limitations in expressive language, seizures, and abnormal tone. However, our patient also manifested epileptic spasms which have not previously been described as a phenotypic presentation associated with this mutation. Interestingly, our patient's spasms did not begin until 11 months of age which is slightly later than the classic onset of infantile spasms. Our patient's robust response to the ketogenic diet is encouraging but not surprising as the ketogenic diet is shown to be quite efficacious against epileptic spasms with a variety of aetiologies (Kossoff *et al.*, 2002; Pires *et al.*, 2013). Our patient does not show signs of progressive extrapyramidal symptoms yet, but this is classically described to start in early adulthood. Additionally, the two MRI examinations of our patient, obtained in early childhood, were normal. This is similar to the normal MRI during childhood of previously reported patients, and is not unexpected since brain MRI changes occur later during the course of the disease after significant neurodegeneration (Haack *et al.*, 2012). Likewise, although epileptic spasms have not previously been reported with this mutation, it is well-documented that various other seizure types do occur as an early manifestation of *WDR45* mutations. Previously reported seizure presentations associated with this mutation are outlined in *table 1*. Reported cases reference childhood onset of seizures but do not cite specific ages. Our patient initially presented with focal seizures in infancy at the age of three months. As such, our case is the earliest known presentation of a patient with a *WDR45* mutation. Furthermore, a recent article cited the *WDR45* gene as a gene of interest in infantile spasms as it was located in an area of duplication on the X chromosome in a patient with otherwise unexplained infantile spasms (Michaud *et al.*, 2014). This lends further support to *WDR45* gene mutation as the unifying abnormality responsible for the presentation of our patient. Given our experience, we conclude that BPAN should be considered during differential diagnosis for patients with otherwise unexplained early-onset focal seizures and otherwise unexplained epileptic spasms.

## Supplementary data.

Summary didactic slides are available on the [www.epilepticdisorders.com](http://www.epilepticdisorders.com) website.

## Acknowledgements and disclosures.

This study was completed at Duke University Medical Center, Division of Pediatric Neurology in Durham, North Carolina. The authors did not receive financial support for the authorship and/or publication of this article.

This manuscript represents the views of all listed authors. No duplicate or overlapping manuscripts have been submitted elsewhere for publication. The authors have no conflict of interest to disclose.

## References

- Haack T, Hogarth P, Kruer M, *et al.* Exome sequencing reveals *de novo* *WDR45* mutations causing a phenotypically distinct, X-linked dominant form of NBIA. *Am J Hum Genet* 2012; 91: 1144-9.
- Haack TB, Hogarth P, Gregory A, *et al.* BPAN: the only X-linked dominant NBIA disorder. *Int Rev Neurobiol* 2013; 110: 85-90.
- Hayflick S, Kruer M, Gregory A, *et al.* Beta-propeller protein-associated neurodegeneration: a new X-linked dominant disorder with brain iron accumulation. *Brain* 2013; 136(6): 1708-17.
- Horvath R. Brain iron takes off: a new propeller protein links neurodegeneration with autophagy. *Brain* 2013; 136(6): 1687-91.
- Kossoff EH, Pyzik P, McGrogan J, *et al.* Efficacy of the ketogenic diet for infantile spasms. *Pediatrics* 2002; 109(5): 780-3.
- Michaud JL, Lachance M, Hamdan FF, *et al.* The genetic landscape of infantile spasms. *Hum Mol Genet* 2014; 23(18): 4846-58.
- Pires ME, Ilea A, Bourel E, *et al.* Ketogenic diet for infantile spasms refractory to first line treatments: an open prospective study. *Epilepsy Res* 2013; 105(1-2): 189-94.
- Rathore G, Schaaf C, Stocco A. Novel mutation of the *WDR45* gene causing beta-propeller protein-associated neurodegeneration. *Mov Disord* 2014; 29(4): 574-5.
- Saito H, Nishimura T, Muramatsu K, *et al.* *De novo* mutations in the autophagy gene *WDR45* cause static encephalopathy of childhood with neurodegeneration in adulthood. *Nat Genet*, 2013; 45(4): 445-9, 449e1.
- Verhoeven W, Egger J, Koolen D, *et al.* Beta-propeller protein-associated neurodegeneration (BPAN), a rare form of NBIA: novel mutations and neuropsychiatric phenotype in three adult patients. *Parkinsonism Relat Disord* 2014; 20(3): 332-6.

## TEST YOURSELF



- (1) What are the seizure manifestations of *WDR45* mutation?
- (2) Can epileptic spasms be a presenting symptom of a patient with a *WDR45* mutation?

*Note: Reading the manuscript provides an answer to all questions. Correct answers may be accessed on the website, [www.epilepticdisorders.com](http://www.epilepticdisorders.com), under the section "The EpiCentre".*