

Hypothalamic hamartoma and epilepsy in children: illustrative cases of possible evolutions

Alexis A. Arzimanoglou¹, Edouard Hirsch², Jean Aicardi¹

1. Epilepsy Unit, Child Neurology and Metabolic Diseases Department, University Hospital Robert Debré, Paris

2. Neurology Department, University Hospital of Strasbourg, France

ABSTRACT – The progresses of neuroimaging have allowed an earlier detection of hypothalamic hamartoma in children presenting with gelastic or dacrystic seizures. Associated symptoms can include other types of seizures, precocious puberty, and behavioral or cognitive deterioration. Combination of all these features is not constant and, when present, their evolution may be variable. When epilepsy proves intractable, surgery may be a solution but is not without risks. Therefore, it can only be justified on the basis of a considerable degree of certainty on the progressive character of the disorder, both in terms of epilepsy and global development.

Even though epilepsy is a major and usually the most important problem, it is not always possible to predict its course and to be able to evaluate its potential effects on development. Available data suggests that deterioration is partly related to the epileptogenic activity.

We reviewed data from 16 personal cases and discussed the possible evolutions of the epilepsy syndrome on the basis of 6 illustrative cases and a review of the literature. We point out that seizures may start early in life and evolve either towards a catastrophic encephalopathy or may be transiently severe and will progressively settle down. Intermediate situations also exist as well as cases presenting with a mild epilepsy. In almost all cases cognitive difficulties are present and may be associated with behavioral disturbances. They are of variable severity, usually in relation to the severity of the epilepsy and the evolution of the EEG abnormalities. Some of our cases also illustrate that, in young children whose seizures are limited to “a sensation of a pleasant feeling”, “a pressure to laugh” or “smiling”, early detection of the hamartoma may still be difficult and the epilepsy pattern may be misdiagnosed as an epilepsy temporal or frontal origin. Detailed analysis of the electro-clinical evolution of representative cases highlights the variable expression of the epilepsy syndrome and renders difficult any dogmatic position on early surgery. However, recent data suggests that a surgical solution must be sought early. Prospective studies are needed to evaluate, not only outcome in terms of control the seizures without unacceptable side effects but also on the evolution of the cognitive and behavioral profile of children with HH and epilepsy are needed. [*published with videosequences*]

KEY WORDS: hypothalamic hamartoma, epilepsy, child, epileptic, encephalopathy



Correspondence:

A.A. Arzimanoglou
Head of Epilepsy Program
Child Neurology and Metabolic Diseases Dpt,
University Hospital Robert-Debré
48, bd Sérurier, 75019 Paris, France
Tel: + 33 1 40 03 19 69
Fax: + 33 1 40 03 20 44
E-mail:
alexis.arzimanoglou@rdb.ap-hop-paris.fr

Presented at the International Symposium on Hypothalamic Hamartoma and Epilepsy, Montreal Neurological Institute, Montreal, Canada, November 29th 2001.

Hypothalamic hamartomas (HH) are ectopic masses of neuronal and glial tissue, which may be small and pedunculated or sessile and relatively large. Their histological structure resembles that of grey matter with varying proportions of neurons, glia and fiber bundles [1]. They do not behave as true tumors. Rather they grow at approximately the same rate as the rest of the encephalon and never produce symptoms or signs of nerve tissue compression [2], in the classical sense of the term. The embryological development of the hypothalamus and the anatomical correlations of the hamartoma are thoroughly discussed by Freeman *et al.* [3].

The association of gelastic and/or dacrystic seizures with HH represents a puzzling etiological entity. The epilepsy syndrome is now well recognized [4-5]. Associated symptoms can include other seizure types, precocious puberty, behavioral disturbances and progressive cognitive deterioration [4-6]. However, the presence of an HH is not always related to the development of the full clinical picture. Clinically, some may remain neurologically asymptomatic or they may be associated with precocious isosexual puberty of central origin.

When seizures develop in association with HH, and although review of the literature suggests a spectrum of epilepsy severity, cognitive deterioration of variable degree and behavioral difficulties are almost constant features. Mullatti *et al.* [7-8] recently reported cases with onset of epilepsy in adulthood. However, in the majority of cases, epilepsy begins during the neonatal or early childhood period, usually in the form of laughter seizures.

We reviewed 16 personal cases with epilepsy and HH. The diagnosis of the hamartoma was based on MRI. All 16 initially presented with gelastic seizures. Despite a long follow-up and several treatment trials with AEDs, in various combinations and at optimal doses, none became seizure free.

As demonstrated by the following 6 illustrative cases, evolution of the epilepsy may be variable, rendering any dogmatic treatment decision-making difficult. In a small number of cases epilepsy may run a smooth course, seizures being rather rare and cognitive development allowing full social integration. Other patients will rapidly develop transiently intractable epilepsy with an acceptable outcome later in life. In the majority of patients epilepsy will prove to be drug-resistant, manifesting with multiple seizure types and progressive cognitive and developmental deterioration. This evolution has been proposed as a model for both progressive epilepsy and pervasive developmental disorders of childhood [5; 9-10].

Illustrative case reports

Patient 1

A 23 year-old man with an unremarkable personal and family history, presented at the age of 4, with episodes of

laughter. At onset, these episodes were rare (up to 3 per month) and a brief alteration of consciousness could be occasionally associated. Psychomotor development and neurological examination were normal. At that time a CT scan and repeated EEGs showed no abnormality. By the age of 8 years, episodes of laughter increased in frequency, to become daily and were almost always associated to an alteration of consciousness. The patient had a first tonic-clonic seizure at the age of 13. Two years later, he experienced a clear-cut aggravation of his epilepsy. A video-EEG recording allowed identification of 3 seizure patterns: serial gelastic seizures, characterized by laughter without loss of contact, redness of the face and mydriasis; episodes qualified as "minor", isolated or following a gelastic seizure, characterized by alteration of consciousness for more than a minute, gestural automatisms, head and eye deviation to the left; episodes qualified as "major", usually continuing "minor seizures" and characterized by a confusional state, automatisms, perambulation, incontinence and, occasionally a tonic contraction of the legs with fall on the ground. Scalp EEGs evidenced, on a normal background activity, a left fronto-temporal spike-wave focus. Ictal EEG was characterized by a diffuse flattening, lasting 6 to 8 seconds, that preceded a discharge of slow waves in the anterior regions associated to some spikes on the left. MRI showed a one cm diameter HH, impinging on the floor of the 3rd ventricle and situated just behind the left optic tract (*figure 1*). His epilepsy proved extremely resistant to drugs for several years, despite adequate treatment [11]. We followed the patient since 1998, when he moved to Paris. At that time, the frequency of the gelastic seizures was evaluated up to 600 per month; "major seizures" were relatively rare (1 to 5 per month) and "minor seizures" were almost daily (10 to 32 per month). Possibilities for a surgical treatment have been presented to the patient and his family. Taking into account a globally favorable cognitive profile it was decided to further discuss the issue at the end of his school years. His epilepsy stabilized 18 months later, when he progressively reached a treatment limited to sodium valproate and lamotrigine association. "Major" and "minor" seizures stopped, while gelastic seizures persisted. They became less frequent (up to 5 per month), characterized by episodes of uncontrolled laughter, often preceded by a sensation of low dose electrocution "as if I touched the protective fence of a courtyard". Occasionally he also described episodes of "pressure to laugh". During the next 4 years, no change was observed following increase of lamotrigine doses or addition of a third AED (topiramate or levetiracetam). Decrease in doses of lamotrigine or sodium valproate was always followed by an increase in frequency of gelastic seizures. Several EEGs never showed the development of a bilateral, or diffuse spike-polyspike activity. The patient recently obtained his high school diploma and he has a regular employment. He mainly complains of slowness and lack of reactivity.

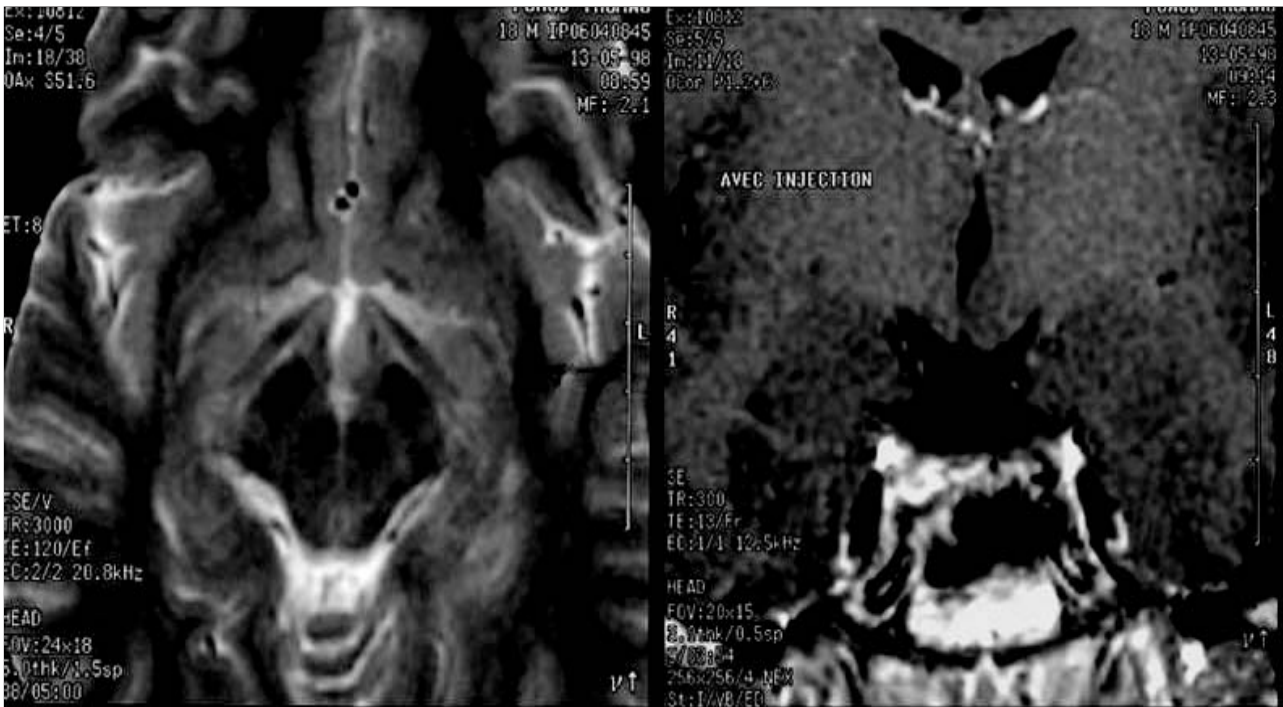

Figure 1. Hypothalamic hamartoma of a relatively small size impinging on the left side of the 3rd ventricle (Patient 1).

Patient 2

A 17 year-old girl, presented at the age of six years with gelastic and partial seizures with secondary generalization. EEGs at onset showed a left temporal focus and a few generalized abnormalities on a normal background activity. MRI evidenced a small in size hamartoma (figure 2). Gelastic seizures were occasionally preceded by an abdominal sensation or could be limited to a smile with right deviation of the corner of the mouth; partial seizures manifested as rotation of the head to the right, followed by

a scream and occasionally clonic jerks of the right arm. Consciousness seemed altered. AEDs, in several associations and at optimal doses, remained without effect. A 24 hours video-EEG at the age of 15 years showed bursts of diffuse spike-waves of large amplitude, more marked on the frontal regions with a left predominance. These were accentuated during sleep and two seizures were recorded. Co-morbidity (hereditary angioneurotic edema) rendered a surgical option difficult. Her epilepsy being highly intractable, she was submitted to gamma-knife radiosurgery.

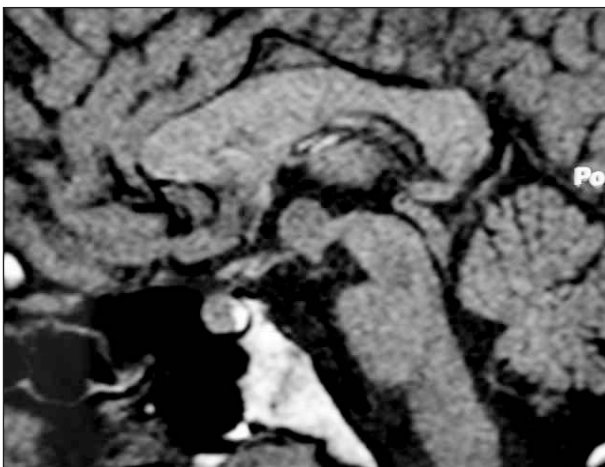


Figure 2. Sagittal view of the HH before radiosurgery (patient 2).

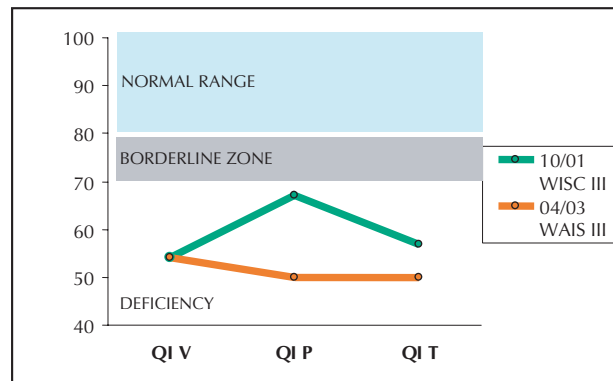


Figure 3. Evolution of verbal and performance IQ in patient 2, evaluated after an 18 months interval. Despite radiosurgery her verbal capacities remained stable while her non verbal performances deteriorated (Courtesy Agathe Laurent, Neuropsychologist, Robert Debré Hospital)

At 12 months following radiosurgery she experienced an episode of severe status epilepticus. Her cognitive capacities further declined (figure 3). At 24 months from gamma-knife surgery, seizure frequency remains unchanged.

Patient 3

A 25 year-old boy experienced his first seizures at the age of 24 months. HH was detected at the age of 8 years. His epilepsy always had a very fluctuating course. His first seizures were considered as atypical absences. Gelastic seizures were diagnosed at the age of 6 years and a few months later he also had generalized tonic-clonic seizures, almost always preceded by an episode of laughter. EEGs also showed a fluctuating evolution alternatively being either normal or characterized by diffuse bursts of spikes and polyspikes. Treatment never influenced the course of his epilepsy, since under the same drug combination he could remain seizure-free for 3 to 5 months only to develop numerous seizures in the following weeks. Cognitive difficulties were evidenced early in the course of his epilepsy. By the age of 14 years he also experienced periods characterized by frequent atonic falls. Injury was not rare. Progressively, behavioral problems came to the first plan. Behavioral instability led to his exclusion from the specialized center he was attending. He is a candidate to radiosurgery.

Patient 4

A 9 year-old girl presented with signs of precocious puberty at the age of 10 months. MRI evidenced the presence

of an oversized HH (figure 4) and she was prescribed hormonal therapy. According to the parents she already at that time presented with episodes of uncontrolled laughter but her EEGs were normal and she didn't receive antiepileptic treatment. When she was 3 years, she moved to Montevideo. A year later episodes of laughter became more frequent and longer in duration, often followed by partial seizures with alteration of consciousness. She was then diagnosed as having epilepsy (*Dr Ruggia*) and started on carbamazepine. Her epilepsy is relatively well controlled during the last 3 years and she attends regular school. However, behavioral problems are at the front scene and she is also under a low dose of risperidone. We became aware of her clinical history when her parents and doctors looked for advice on surgical possibilities. Given the size of the hamartoma complete resection could not be guaranteed and the risk for endocrinology complications and persistence of seizures seemed elevated. Taking into account favorable developmental progression and relative rarity of seizures we advised abstention and a regular neuropsychological assessment.

Patient 5

A 14 year-old boy with an unremarkable personal and family history, presented at age of 2 years, with episodes of laughter. At onset, these episodes were rare and not considered as seizures. At the age of 3, language development was considered delayed and speech therapy was started. Behavioral problems, mainly aggressiveness and anxiety,

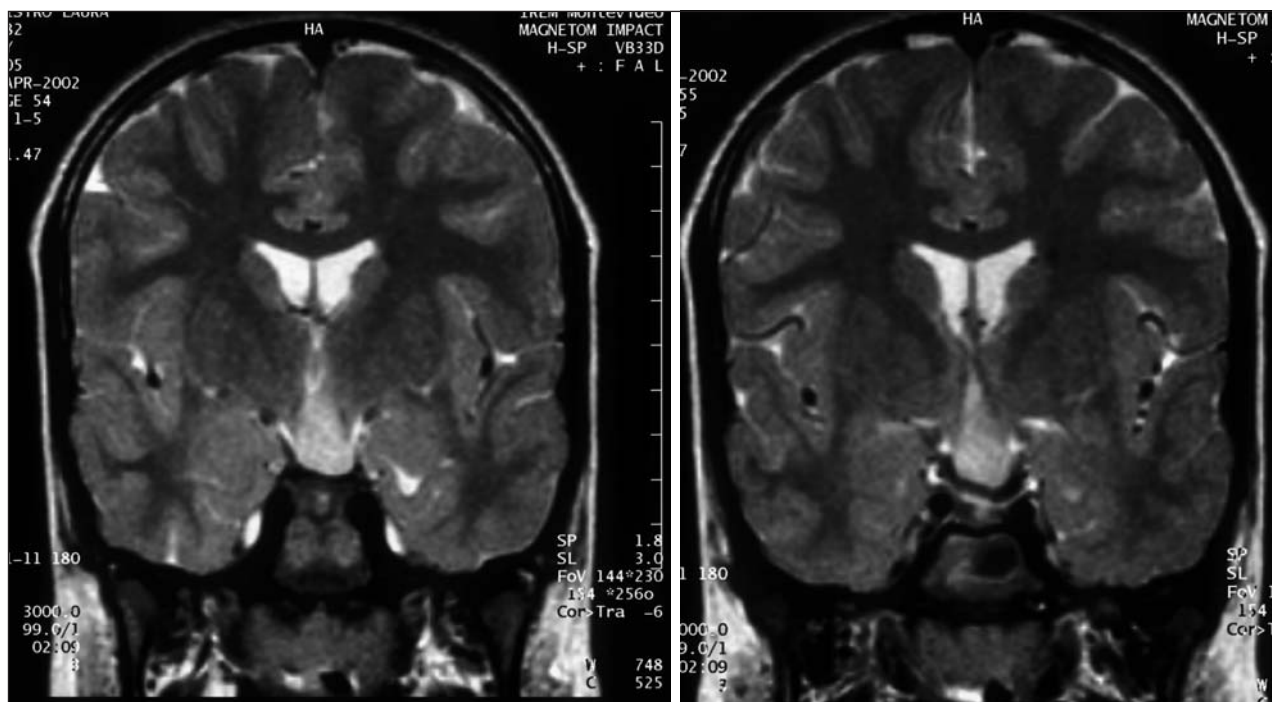


Figure 4. Despite of the size of the HH, evolution of the epilepsy in patient 4 remains relatively benign (Courtesy Drs Ruggia and Diamant, Uruguay).

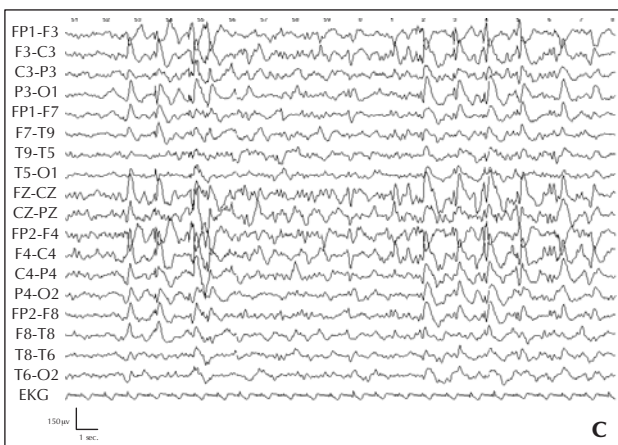
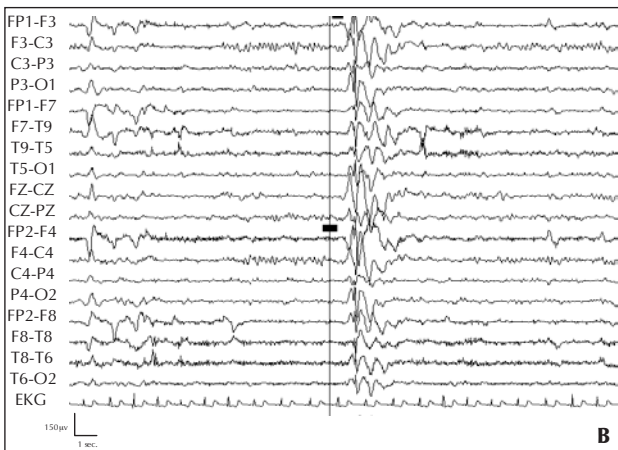
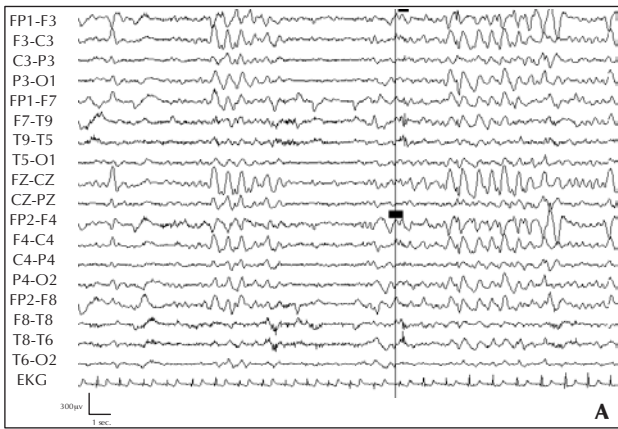

Figure 5. Patient 5. **A:** EEG performed at age 10, awake, showing bilateral fronto-central asymmetric spike-waves discharges, with a left predominance. **B:** EEG performed at age 10, awake, showing bilateral polyspike-waves on a normal background activity. **C:** Sleep EEG performed at age 10, showing bilateral fronto-central spike-waves during Stage 2-3 NREM sleep.

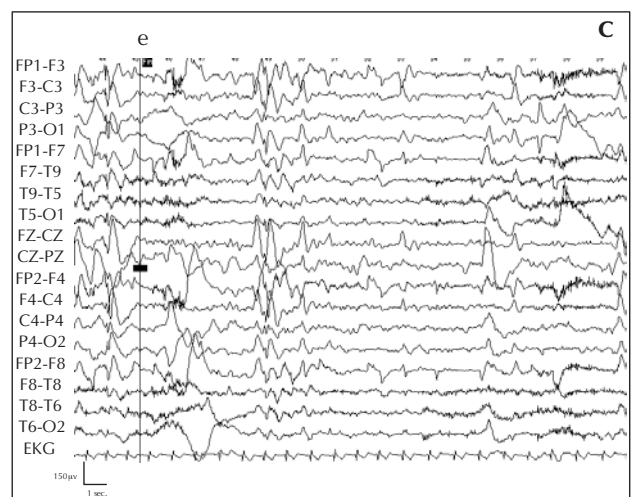
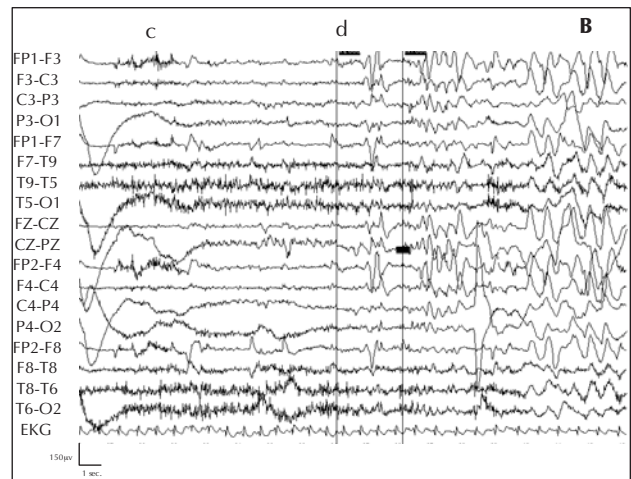
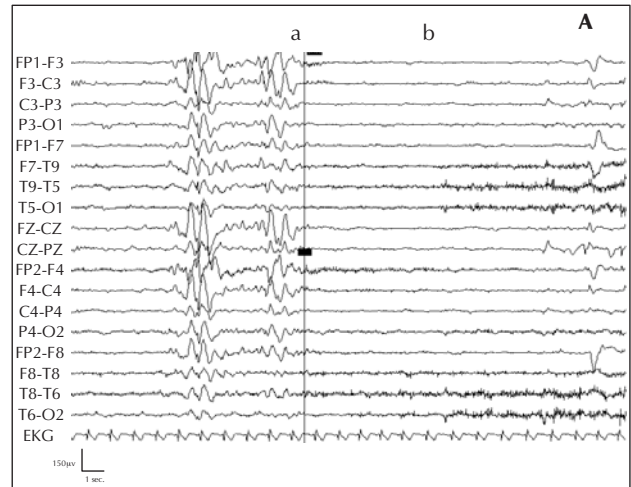


Figure 6. Patient 5. **A:** Ictal EEG performed awake, at age 10 years: a) gelastic seizure onset with bilateral flattening of EEG activity, b) smiling; **B:** c) laughing, d) Injection of ECD for SPECT; **C:** e) end of seizure.

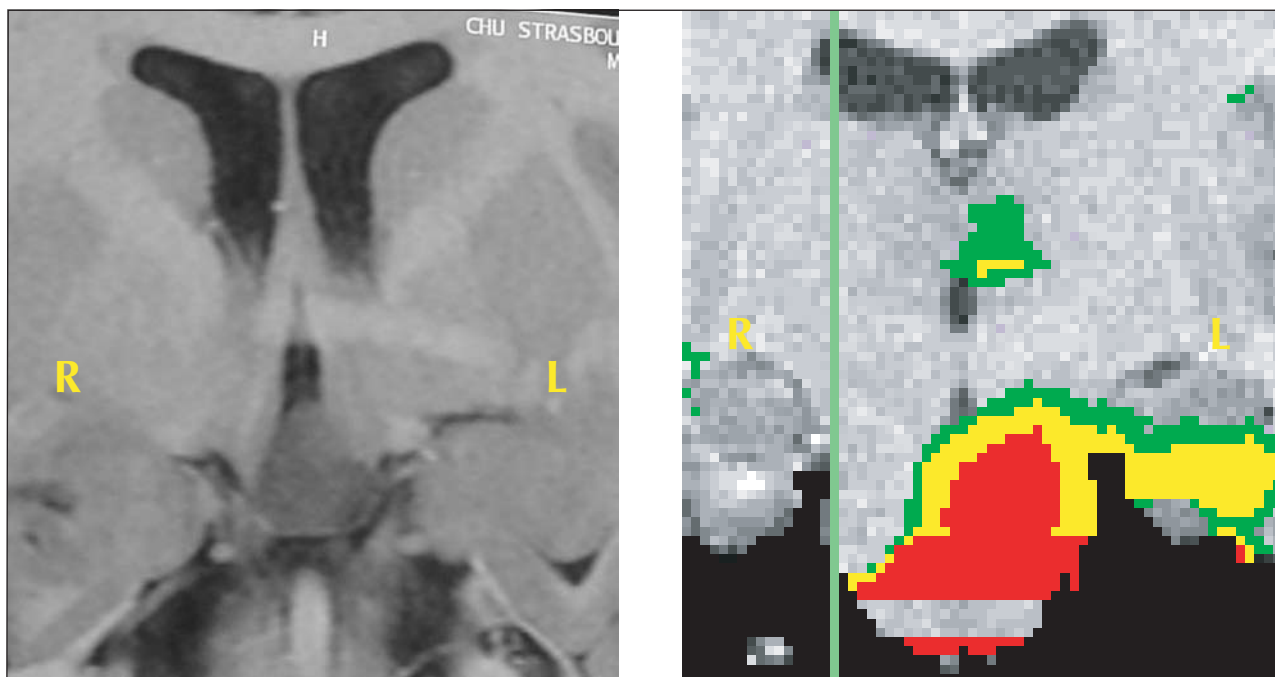


Figure 7. Patient 5. Left, Inversion Recovery MRI Coronal section, hypothalamic hamartoma in the floor of the third ventricle. Right, SISCOM (Subtraction Ictal SPECT Coregistered to MRI) showed increased blood flow in the hamartoma and the amygdala.

were noticed since the age of 5 and he integrated a special education school program. The episodes of laughter were diagnosed as being epileptic seizures by the age of 6 years. Some were associated to flushing of the face, alteration of consciousness, automatisms and hypotonia (**video 1**). He initially received treatment with sodium valproate and, later on, an association of sodium valproate and carbamazepine. Scalp EEGs showed bilateral spike-wave discharges predominant in the left fronto-temporal regions (*figure 5a-b*) that increased during sleep (*figure 5c*). A first MRI was performed at age of 8 and was considered normal. Precocious puberty was observed at age 9. Video-EEG recordings allowed identification of gelastic seizures (**video 2** and *figure 6*) and an ictal SPECT (*figure 8*) was performed showing HH blood flow increased. A new MRI evidenced an HH (1 cm diameter), occupying the floor of the III ventricle and impinging on the left mammillary body (*figure 7*). Neurological examination remained normal. Initial neuropsychological evaluation was not conclusive for IQ, because of behavioral problems. A gamma knife treatment was performed at age of 11 years. Following gamma knife treatment, pharmacological treatment was kept unchanged. During the 3 years follow-up, seizures are rare limited to a modification of the facial expression. The last cognitive evaluation (WISC-III) showed a global IQ of 70 (Verbal 54, Performance 93). The behavioral problems are less disabling and partial integration to normal schooling became possible, coupled to special education support.

Patient 6

At the age of 10 years the patient had a first tonic-clonic seizure during a febrile episode. At history taking, he recalled daily episodes of a pleasant feeling, of short duration, apparently present since the age of 3 years. Otherwise, family and personal history were unremarkable and these episodes were not considered as seizures. Two years later, the family reported seizures characterized by loss of contact, oro-alimentary automatisms, some-

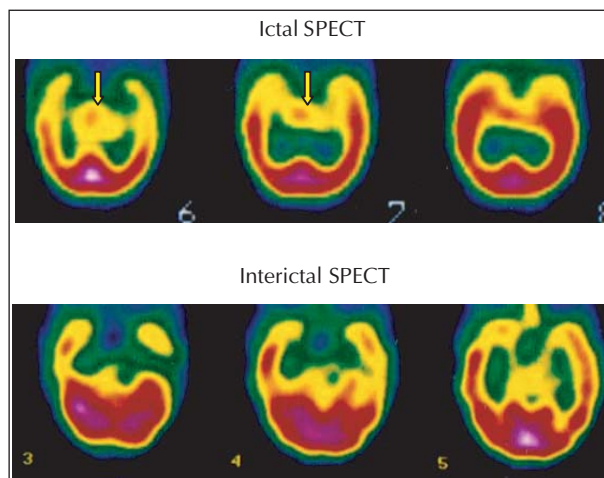


Figure 8. SPECT with ECD, axial section, evidenced focal subcortical increase in blood flow at the level of the hypothalamus.

times followed by a motor seizure (jerks of the right lip, extension of the right arm). A second type of seizures was described as “a prolonged pressure to laugh” or “a pleasant feeling”. His epilepsy, although of relatively late onset, proved resistant to several antiepileptic drugs. Precocious puberty was not observed. At age of 28 years, the patient developed signs of a psychotic behavior with anxiety, aggressiveness and he was put on neuroleptic medication. MRI was performed for the first time at age of 26 years and controlled when 32 years. It was considered normal with the exception of a non-significant abnormal signal of the left amygdala on T2 sequences. At age of 38 years, a new MRI evidenced a very small HH, adjacent to the left wall of the third ventricle (*figure 9*). Video-EEG recording allowed identification of two types of seizures: several episodes of a prolonged pleasant feeling with pressure to laugh (**Video 3**), and a seizure mimicking temporal lobe seizures (**Video 4**). Inter-ictal SPECT (*figure 10*) showed left temporal pole decrease of blood flow. Interictal EEG demonstrated rare left temporal spikes (*figure 11*). Ictal EEG confirmed the occurrence of two types of seizures (gelastic seizure in *figure 12*). Neurological examination was normal. His global IQ (WAIS-R) was of 86 (verbal 81, performance 94). A year later the patient was submitted to gamma knife radiosurgery. A year later, an increase in frequency of the “pleasant feeling” seizures was noted.

One of the episodes evolved to a tonic-clonic status. Treatment was changed to a combination of phenobarbital and lamotrigine. We dispose of a three years follow-up following radiosurgery. Seizures with a temporal semiology are relatively rare (once a month), while episodes of “pleasant feeling” remain daily. The last cognitive evaluation (WAIS-R) showed no further cognitive decline. Behavioral problems rather stabilized, as aggressiveness and psychotic traits progressively regressed but he is still under regular psychiatric follow-up for anxiety. He is working as a qualified manual worker.”

Discussion

In the last few years an increasing number of papers dealt with the epilepsy characteristics in children with hypothalamic hamartoma [4-6; 12-26]. Although a bias cannot be excluded, refractory or surgical cases being reported more frequently, experience of child neurologists confirms the fact that in the majority of cases epilepsy proves to be intractable. Cases evolving towards a seizure-free state are exceptional.

The clinical spectrum of epilepsy

As illustrated by the present cases, severity of the epilepsy is variable. Three of our cases progressively developed an

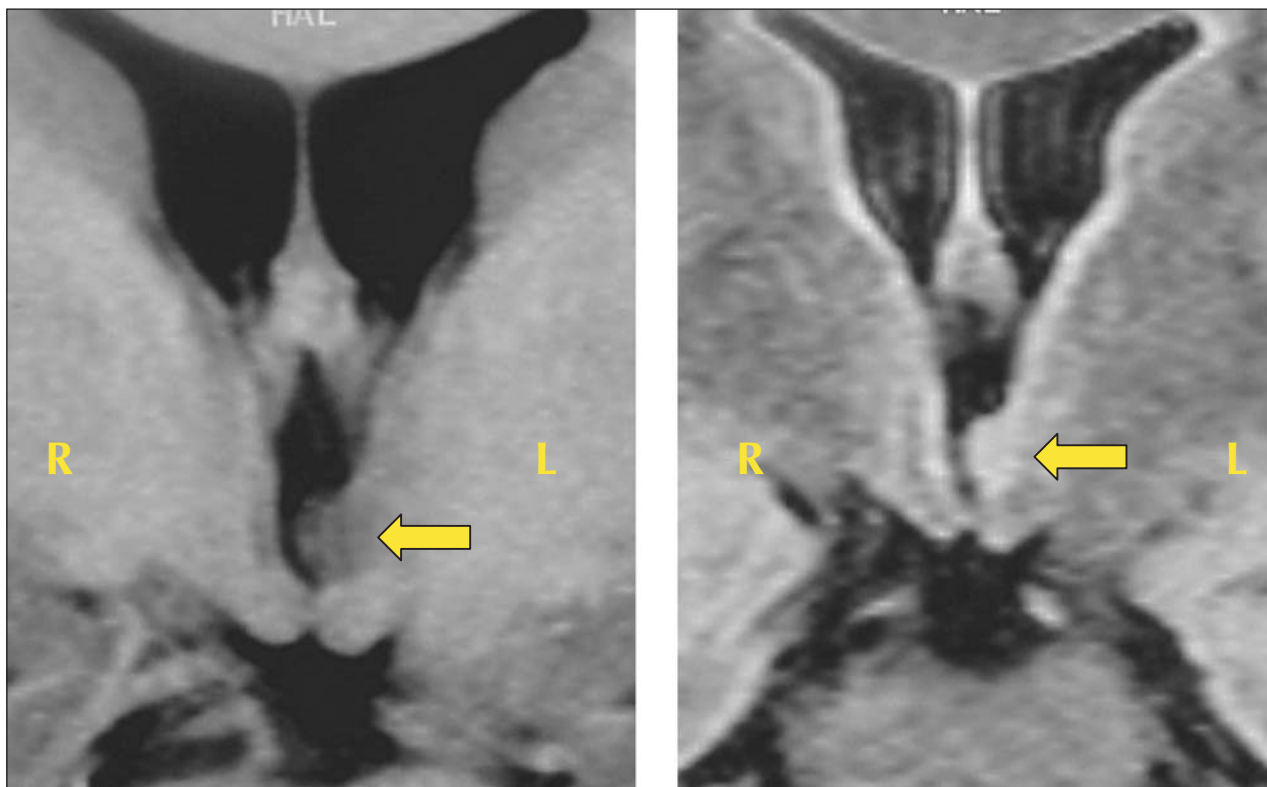


Figure 9. Patient 6. MRI Coronal section, hypothalamic hamartoma on the left wall of the third ventricle, Left, Inversion Recovery, Right, FLAIR.

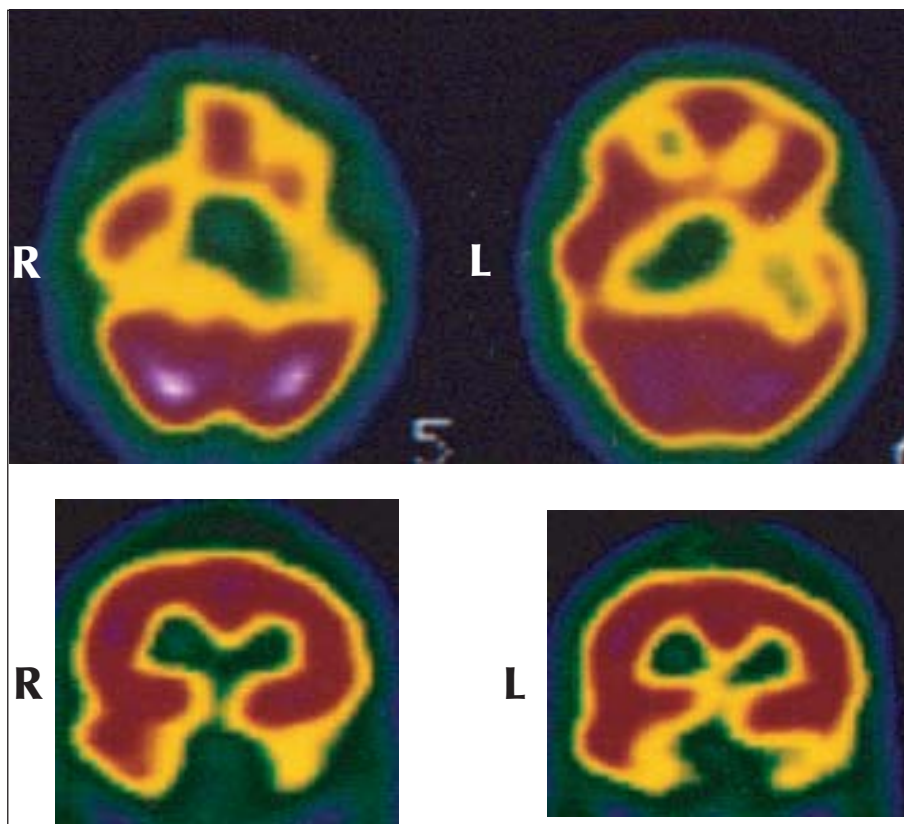


Figure 10. Patient 6. Interictal SPECT showing left temporal pole decrease of blood flow.

epileptic encephalopathy and partial control was obtained in two others following an initial, relatively long period of intractability. They did not develop behavioral problems and cognitive capacities remained relatively preserved, although they both encountered some difficulties. Two other patients always had a mild epilepsy course. Review of the literature concerning children with HH and seizures supports the above data.

In a book chapter on gelastic seizures, Tassinari et al. [4] published the most exhaustive review of cases reported up to 1993, including 4 of his own cases. In the first part of his paper 60 cases with gelastic seizures not associated with HH were reviewed, suggesting that ictal laughter is not pathognomonic of HH. The epilepsy characteristics of 60 cases selected on the presence of gelastic seizures in the presence of an HH were discussed in the second part. For 51 of them, epilepsy began with brief gelastic seizures, occurring several times a day and apparently not accompanied by loss of consciousness. In the series of 19 patients reported by Mullatti et al. [7], gelastic seizures, when present (in 16 out of 19) were the first type of seizures to manifest in 14. Gelastic seizures were not reported by any of the 3 out of 19 patients with adult-onset epilepsy. Gelastic seizures were the first type to be observed in all our patients.

In the 51 cases reviewed by Tassinari et al. [4], age at onset of seizures ranged from 1 day (3 patients) to 15 years (1 patient); mean age of onset for the remaining 47 being 2.8 years. Age of onset range was similar in the majority of series or case reports published since 1993, including ours.

As illustrated by Cases 4 and 6, particularly in young children laughing attacks can be very similar to normal laughing, rendering early diagnosis difficult. A consistent clinical and neurophysiologic pattern of temporal or frontal involvement depending on whether the hamartoma connects to the mamillary bodies or the medial hypothalamus was recently suggested by Leal et al. [27...]. In Mullatti's series [7-8], detection of the HH was made only in adult life in 50 per cent of the 16 patients with early-onset epilepsy and gelastic seizures. Delays in detection of the HH will probably become shorter with the wider use of higher sensitivity MRI scans. To our opinion, repetition of a high quality MRI should be requested for adult patients having had a normal MRI in the past and presenting with intractable epilepsy associating gelastic seizures.

Parallel to the evolution of the epilepsy syndrome, the clinical characteristics of gelastic seizures progressively become more sophisticated or complex, to associate alteration of consciousness of variable degree and duration,

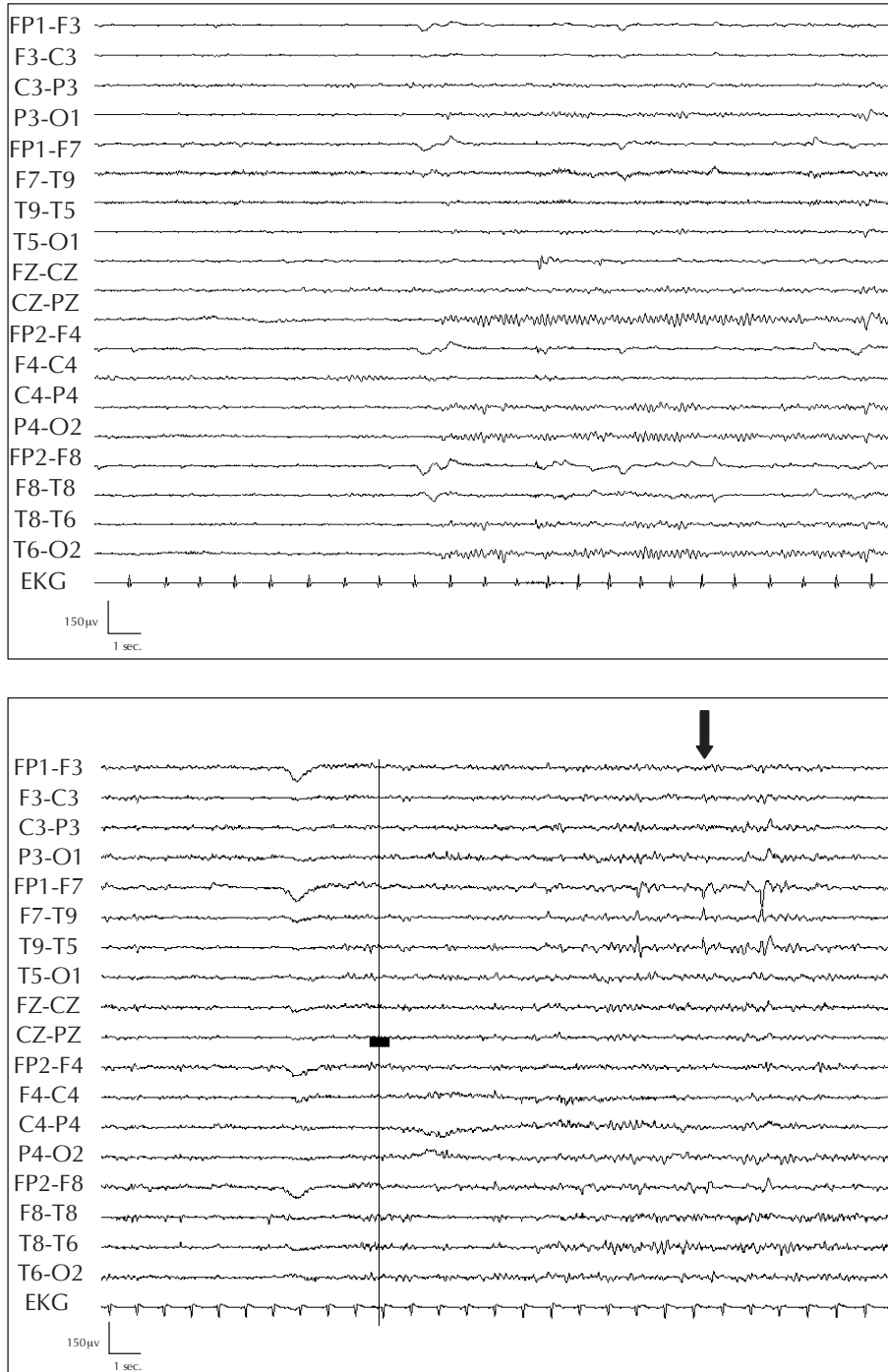


Figure 11. Interictal EEG of patient 6 showing left temporal spikes.

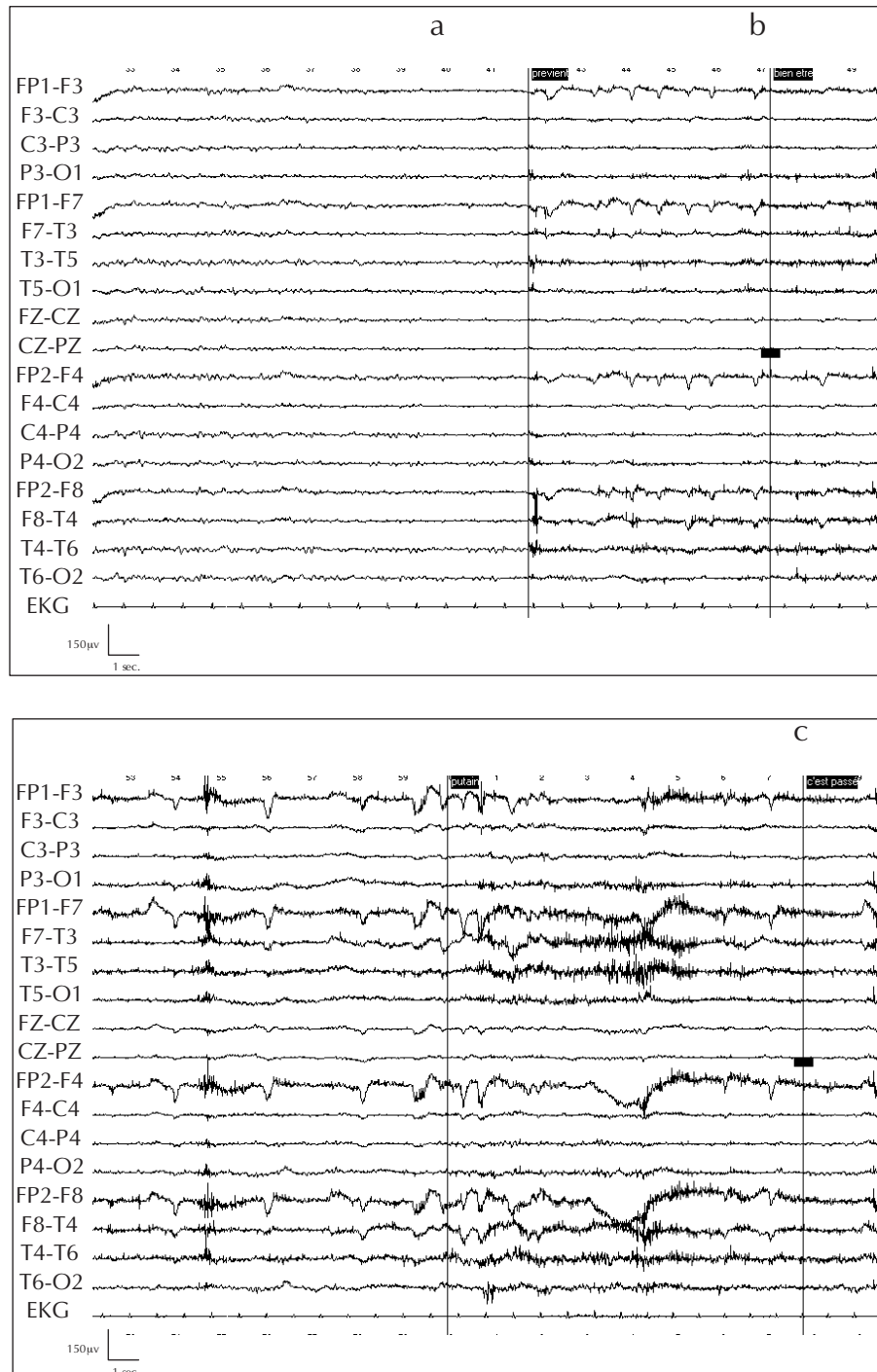


Figure 12. Ictal EEG of a "pleasant feeling" seizure in patient 6. The only abnormality observed is that of a flattening of background EEG activity at seizure onset (a, b pleasant feeling; c end of seizure).

automatisms or facial twitching. However, as illustrated by our cases 1 and 3, their evolution is quite variable. Later in life, frequency and intensity may remain unchanged (4 out of 8 adult patients in Mullatti's series), completely disappear (2 out of 8) or their expression reduced to mere "feelings of an urge to laugh" (2 patients).

Gelastic seizures, although common, are not the only type of seizure observed in patients with HH and are only exceptionally the sole type. Tassinari *et al.* [4] found other intractable seizures in 75% of the patients. Complex partial seizures with or without secondary generalization were present in 35.5 per cent, tonic-clonic seizures in 15.1 per cent, tonic seizures in 17.7 per cent and falling seizures in 33.3 per cent. Mullatti *et al.* [7] reported two to five seizure types present in 18 out of 19 patients: atypical absences in 9, drop attacks in five; partial motor in four; brief, sleep-related tonic seizures in seven; complex partial seizures of temporal lobe type in 11 and generalized convulsions in eight. Three of the 8 children evaluated by Frattali *et al.* [24] for their cognitive deficit, all 3 younger than 11 year-old, presented only gelastic seizures. The remaining five also experienced generalized tonic-clonic seizures (5 children) and atonic seizures (4 children). Leal *et al.* [27] reported postural seizures (2 patients), partial complex seizures (4 patients) and atonic seizures (3 patients) in a series of 7 patients (all but one aged less than 11 years). Other seizure types were present in all of our six patients (partial seizures implicating the temporal lobe in 3, drop attacks in two, atypical absences in 3). The presence of other types of seizures is usually the sign of aggravation of the epilepsy.

Onset of epilepsy in adulthood is probably rare [7; 26]. As discussed by Mullatti [8], patients with adult-onset epilepsy seem to have a milder form of partial epilepsy and, when still present gelastic seizures are less prominent.

Evolution of EEG patterns

For non-operated cases, evolution of EEG activity is only rarely reported in detail [4]. The background EEG activity at initial assessment is normal or shows a slight slowing. This was the case in 11 out of 19 patients, all younger than 10 years when recorded, in Mullatti's series [7] and in 12 (20%) of 19, of the 60 patients for whom data was known, in Tassinari's review [4]. They were considered normal in all of our cases.

Leal *et al.* [27] reported that interictal EEG reveals a consistent lobar involvement. This was temporal in 3 and/or frontal in five in their series of seven patients. Tassinari *et al.* [4] resumed interictal EEG abnormalities as reported in 45 of the 60 cases reviewed. The EEG was normal only in one case [13]. Diffuse spikes and spike-waves were found in 21 patients, focal abnormalities (temporal, frontal or fronto-temporal) in 15 and bilateral in eight.

Progressive increase of EEG abnormalities in patients with HH and intractable epilepsy is a common finding in the majority of reported cases [4; 13; 16-18]. The appearance of diffuse or bilateral low-voltage fast activity or flattening of the tracings, as well as of diffuse or bilateral spike-polyspike waves, characterizes this pattern and is usually considered as a sign of aggravation. In cases 3 and 5 of our series the early behavioral problems were concomitant with bilateral fronto-temporal EEG discharges that increased during sleep.

Mental impairment and abnormal behavior

A cognitive deficit is an almost constant feature in patients with HH and epilepsy. This is usually the result of a slowly progressive decline in intellectual capacities, appearing in children initially considered normal or only slightly retarded. Worsening of epilepsy usually follows a parallel curve. Mental impairment was reported in 49 patients (81.6%) of Tassinari's review [4]. Behavioural disturbances were also present in 34% of the cases. In the series of 8 children reported by Frattali *et al.* [24] and evaluated for cognitive deficits, gelastic and partial seizure severity was correlated with broad cognitive ability standard scores. Deonna and Ziegler [10] reported a detailed longitudinal study of a single case showing that the installation of a pervasive developmental disorder and an attention deficit could be considered as a direct effect of the seizures. All of our patients with a catastrophic epilepsy pattern progressively developed signs of cognitive and behavioral deterioration. In cases with transiently intractable epilepsy, global cognitive evolution was rather favorable although they all presented with some difficulties.

Although prospective studies are lacking, cognitive and behavioral problems seem not to be an issue in children with HH and precocious puberty not associated with epilepsy. In children, precocious puberty (PP), defined as the development of secondary sexual characteristics in girls younger than 8 and boys younger than 9 years of age, is one of the symptoms of tumors and other lesions or malformations localized in the sellar, suprasellar and pineal areas. In a recent study [28], PP was the presenting clinical disturbance, before any therapeutic procedure was carried out, in 26% of a series of 115 children younger than 8/9 years of age with images of suprasellar or pineal lesions. When looking at the type of the lesion in the whole series (n = 115), it was found that 100% of the 11 patients with HH and the 4 patients with subarachnoid cysts or arachnoidocele presented with PP. None of the 36 patients with craniopharyngioma had PP before surgery or radiotherapy. Mean age at onset of PP was between 5 and 6 years old for all types of midline lesions studied, except for HH (2.25 ± 0.98 years; $p < 0.001$). Similarly, in the NIH series [29] an HH was diagnosed in one-half of their patients with organic central precocious puberty and a midline lesion. In an Italian retrospective study [30], investigating on etiology of central PP in 45 males, 40%

were considered as having neurogenic central PP, related in six (33%) to the presence of an HH.

Conclusions

The association of hypothalamic hamartoma, gelastic and/or dacrystic seizures, other seizure types, precocious puberty, behavioral disturbances and progressive cognitive deterioration can be considered as a well-defined epilepsy syndrome. However, the cases selected from our personal experience clearly show that diagnosis may be difficult at onset, as all signs and symptoms are not yet necessarily present, and that the natural evolution of both the seizures and the neuropsychological profile may be variable.

Evolution towards intractable epilepsy and stagnation-regression of cognitive development are not a constant but certainly a frequent feature in children with HH and seizures. In our series of 16 patients epilepsy proved highly intractable in 5, had a globally mild evolution in 7 and was relatively well controlled after some years of intractability in 4.

Persistent epileptogenic activity could be at least partly responsible for such an evolution and deterioration of EEG recordings proved to be a relatively consistent finding in cases with unfavorable evolution. However, we do not dispose yet of clear-cut parameters, allowing us to predict global evolution.

Recent data suggests that resection of the lesion, provided that the specific approach is tailored according to the surgical anatomy and performed by experienced neurosurgeons, seems less hazardous than in the past [31-38]. Outcome following radiosurgery is still under evaluation [39-41].

Prospective studies focusing on the behavioral and cognitive evolution of children operated-on early in the course of their disease are necessary. □

References

- Russel DS, Rubinstein LJ (eds). Pathology of tumours of the Nervous System 5th Edn. 1989; London: Edward Arnold.
- Turjman F, Xavier JL, Froment JC, Tran-Minh VA, David L, Lapras C. Late MR follow-up of hypothalamic hamartomas. *Childs Nerv Syst* 1996; 12: 63-8.
- Freeman JL. The anatomy and embryology of the hypothalamus in relation to hypothalamic hamartomas. *Epileptic Disord* 2003; 5: xx-yy (pages of this issue/to be completed)
- Tassinari CA, Riguzzi P, Rizzi R, et al. Gelastic Seizures. In: Tuxhorn I, Holthausen H, Boenigk K (eds). In: Paediatric Epilepsy Syndromes and Their Surgical treatment. London, John Libbey, 1997 pp 429-46.
- Berkovic SF, Arzimanoglou A, Kuzniecky R, Harvey S, Palmini A, Andermann F. Hypothalamic hamartoma and seizures: a treatable epileptic encephalopathy. *Epilepsia* 2003; 44: 969-73.
- Berkovic SF, Andermann F, Melanson D, Ethier RE, Feindel W, Gloor P. Hypothalamic hamartomas and ictal laughter: Evolution of a characteristic epileptic syndrome and diagnostic value of magnetic resonance imaging. *Ann Neurol* 1988; 23: 429-39.
- Mullatti N, Selway R, Nashef L, Elwes R, Honavar M, Chandler C, Morris R, Jarosz J, Buchanan C, Polkey C. The clinical spectrum of epilepsy in children and adults with hypothalamic hamartoma. *Epilepsia* 2003; 44: 1310-9.
- Mullatti N. Hypothalamic hamartoma in adults. *Epileptic Disord* 2003; 5: xx-yy (pages of this issue/to be completed)
- Berkovic SF, Kuzniecky RI, Andermann F. Human epileptogenesis and hypothalamic hamartomas: New lessons from an experiment of nature. *Epilepsia* 1997; 38: 1-3.
- Deonna T, Ziegler AL. Hypothalamic hamartoma, precocious puberty and gelastic seizures: a special model of "epileptic" developmental disorder. *Epileptic Disord* 2000; 2: 33-7.
- Schaff JL, Vignal JP, Biraben A, Vespignani H, Chauvel P, Weber M. Crises de fou rire chez un jeune garçon épileptique. *Epilepsies* 1997; 9: 183-9.
- Plouin P, Ponsot G, Dulac O, Diebler C, Arthuis M. Hamartomes hypothalamiques et crises de rire. *Rev EEG Neurophysiol* 1983; 13: 312-6.
- Ponsot G, Diebler P, Plouin P, et al. Hamartomes hypothalamiques et crises de rire: à propos de 7 observations. *Arch Fr Pediatr* 1983; 40: 757-61.
- Machado HR, Hoffman HJ, Hwang PA. Gelastic seizures treated by resection of a hypothalamic hamartoma. *Child Nerv Syst* 1991; 7: 462-5.
- Arroyo S, Lesser RP, Gordon B, Uematsu S, Hart J, Schwerdt P, Andreasson K, Fisher RS. Mirth, laughter, and gelastic seizures. *Brain* 1993; 116: 757-80.
- Cascino GD, Andermann F, Berkovic SF et al. Gelastic seizures and hypothalamic hamartomas: evaluation of patients undergoing chronic intracranial EEG monitoring and outcome of surgical treatment. *Neurology* 1993; 43: 747-50.
- Kahane P., Tassi L., Hoffmann D., Francione S., Gratadou-Juery G., Pasquier B., Munari C. Crises dacrystiques et hamartome hypothalamique: à propos d'une observation vidéo-stéréo-EEG. *Epilepsies* 1994; 6: 259-79.
- Munari C, Kahane P, Francione S, et al. Role of the hypothalamic hamartoma in the genesis of gelastic fits (a video-stereo-EEG study). *Electroencephalogr Clin Neurophysiol* 1995; 95: 154-60.
- Arroyo S, Santamaría J, Sanmartí F, Lomena F, Catafau A, Casamitjana R, Setoain J, Tolosa E. Ictal laughter associated with paroxysmal hypothalamopituitary dysfunction. *Epilepsia* 1997; 38: 114-17.
- Kahane P, Munari C, Minotti L, Hoffmann D, Tassi L, Pasquier B, Grand S, Benabib AL. The role of the hypothalamic hamartoma in the genesis of gelastic and dacrystic seizures. In: Tuxhorn I, Holthausen H, Boenigk K (eds), Paediatric Epilepsy Syndromes and Their Surgical Treatment. London, John Libbey, 1997: 447-61.
- Kuzniecky R, Guthrie B, Mountz J, et al. Intrinsic epileptogenicity of hypothalamic hamartomas in gelastic epilepsy. *Ann Neurol* 1997; 42: 60-7.

22. Sturm JW, Andermann F, Berkovic SF. "Pressure to laugh": an unusual epileptic symptom associated with small hypothalamic hamartomas. *Neurology* 2000; 54: 971-3.
23. Meyer MA. Temporal lobe hypometabolism ipsilateral to a hypothalamic mass. Relationship to gelastic seizures. *Clin Positron Imaging* 2000; 3: 75-7.
24. Frattali CM, Liow K, Craig GH, Korenman LM, Makhoul F, Sato S, Biesecker LG, Theodore WH. Cognitive deficits in children with hypothalamic hamartoma. *Neurology* 2001; 57: 43-6.
25. Perez-Jimenez A, Villarejo FJ, Fournier del Castillo MC, Garcia-Penas JJ, Carreno M. Continuous giggling and autistic disorder associated with hypothalamic hamartoma. *Epileptic Disord* 2003; 5: 31-7.
26. Striano S, Striano P, Cirillo S, Nocerino C, Bilo L, Meo R, Ruosi P, Boccella P, Briganti F. Small hypothalamic hamartomas and gelastic seizures. *Epileptic Disord* 2002; 4: 129-33.
27. Leal AJ, Moreira A, Robalo C, Ribeiro C. Different electroclinical manifestations of the epilepsy associated with hamartomas connecting to the middle or posterior hypothalamus. *Epilepsia* 2003; 44: 1191-5.
28. Rivarola, Belgorosky A, Mendilaharsu H, Vidal G. Precocious puberty in children with tumours of the suprasellar and pineal areas: organic central precocious puberty. *Acta Paediatr* 2001; 90: 751-6.
29. Pescovitz OH, Comite F, Hench K, Barnes K, McNemar A, Foster C, Kenigsberg D, Loriaux DL, Cutler GB Jr. The NIH experience with precocious puberty: diagnostic subgroups and response to short-term luteinizing hormone releasing hormone analogue therapy. *J Pediatr* 1986; 108: 47-54.
30. De Sanctis V, Corrias A, Rizzo V, Bertelloni S, Urso L, Galluzzi F, Pasquino AM, Pozzan G, Guarneri MP, Cisternino M, De Luca F, Gargantini L, Pilotta A, Sposito M, Tonini G. Etiology of central precocious puberty in males: the results of the Italian Study Group for Physiopathology of Puberty. *J Pediatr Endocrinol Metab* 2000; 13 Suppl 1: 687-93.
31. Valdueza JM, Cristante L, Dammann O, et al. Hypothalamic hamartomas: with special reference to gelastic epilepsy and surgery. *Neurosurgery* 1994; 34: 949-58.
32. Nishio S, Morioka T, Fukui M, Goto Y. Surgical treatment of intractable seizures due to hypothalamic hamartoma. *Epilepsia* 1994; 35: 514-9.
33. Stewart LS, Steinbok P, Daaboul J. Role of surgical resection in the treatment of HH causing precocious puberty. *J Neurosurg* 1998; 88: 340-5.
34. Rosenfeld JV, Harvey AS, Wrennall J, Zacharin M, Berkovic SF. Transcallosal resection of hypothalamic hamartomas, with control of seizures, in children with refractory epilepsy. *Neurosurgery* 2001; 48: 108-18.
35. Palmieri A, Chandler C, Andermann F, et al. Resection of the lesion in patients with hypothalamic hamartomas and catastrophic epilepsy. *Neurology* 2002; 58: 1338-47.
36. Delalande O, Fohlen M. Disconnecting surgical treatment of hypothalamic hamartoma in children and adults with refractory epilepsy and proposal of a new classification. *Neurol Med Chir (Tokyo)*. 2003; 43: 61-8.
37. Freeman JL, Harvey AS, Rosenfeld JV, Wrennall JA, Bailey CA, Berkovic SF. Generalized epilepsy in hypothalamic hamartoma: evolution and postoperative resolution. *Neurology* 2003 11; 60: 762-7.
38. Polkey C. Resective surgery for hypothalamic hamartoma. *Epileptic Disord* 2003; 5: xx-yy to be completed/this issue
39. Regis J, Bartolomei F, de Toffol B, et al. Gamma knife surgery for epilepsy related to hypothalamic hamartomas. *Neurosurgery* 2000; 47: 1343-51.
40. Unger F, Schrottner O, Haselsberger K, et al. Gamma knife radiosurgery for hypothalamic hamartomas in patients with medically intractable epilepsy and precocious puberty. Report of two cases. *J Neurosurg* 2000; 92: 726-31.
41. Regis J, Bartolomei F, Hayashi M, Roberts D, Chauvel P, Peragut JC. The role of gamma knife surgery in the treatment of severe epilepsies. *Epileptic Disord* 2000; 2: 113-22.