

Limited resection of focal cortical dysplasia and associated epileptogenic cortex may lead to positive surgical outcome

Kyriakos Garganis¹, Vasileios Kokkinos¹, Basilios Zountsas²

¹Epilepsy Monitoring Unit

²Neurosurgery Department, "St. Luke's" Hospital, Thessaloniki, Panorama, Greece

Received August 20, 2010; Accepted November 24, 2011

ABSTRACT – A drug-resistant epilepsy patient with premotor type IIb focal cortical dysplasia is described with a positive postoperative outcome following partial resection of the lesion and epileptogenic zone. Presurgical fMRI of the sensorimotor areas showed haemodynamic responses over the posterior border of the lesion and ictal EEG-fMRI revealed activation of both the primary sensorimotor strip and premotor lesion area. Almost continuous 1-2 Hz interictal spiking was recorded during a chronic ECoG study over the primary sensorimotor cortex. Following partial resection of the lesion, an acute ECoG revealed marked reduction of epileptic activity over the sensorimotor area. Post-operatively, seizure control was significantly improved (class IV ILAE outcome). Although partial FCD resections predict a worse postoperative outcome, individual patients may still respond favourably. The type of lesion, resected portion, and histopathology may be included among factors related to successful outcome.

Key words: epilepsy surgery, intracranial EEG, EEG-fMRI, fMRI, cortical electrical stimulation

Epilepsy surgery for focal cortical dysplasia (FCD) associated with intractable seizures is becoming increasingly common following recent achievements in imaging (Colombo *et al.*, 2009; Focke *et al.*, 2008; Woermann and Volmar, 2009) and the increasing use of invasive EEG and electrical cortical stimulation. Factors significantly related to a successful surgical outcome are resection of the complete lesion,

along with resection of the ictal onset zone and highly active interictal cortical areas, as derived from invasive EEG (Palmieri *et al.*, 1995; Kim *et al.*, 2009; Widdess-Walsh *et al.*, 2007). Incomplete resection of either the highly epileptogenic cortex or the MRI lesion predicts a less satisfactory postoperative outcome, which is even worse for incomplete resections of both (Perry *et al.*, 2010). However, surgery "against the

Correspondence:

Kyriakos Garganis
Epilepsy Monitoring Unit,
"St. Luke's" Hospital, 55236,
Panorama, Thessaloniki, Greece
<gkkap@the.forthnet.gr>

odds", especially in cases with frequent incapacitating seizures, may still be accompanied by positive outcomes and thus be an option, as shown in this case report.

Case report: clinical data

A 32-year-old, right-handed man of Caucasian origin, presented with a history of intractable epilepsy since the age of 10. He was the product of a full-term normal pregnancy and delivery. Developmental milestones were appropriately achieved and cognitive status was normal, without any family or personal history of risk factors for epilepsy.

Seizure semiology was reported to be stereotyped throughout history. Events occurred both during wakefulness and sleep; the patient recognised an aura of "stiffening sensation" over the trunk and thorax, and arms assumed tonic positions, with the left arm often jerking immediately thereafter. If standing, he would collapse. He was unable to either talk or follow commands during the event but the level of consciousness was minimally disturbed, as he often precisely recalled things that happened during the seizure. Seizure duration was 10-20 seconds. During more prolonged episodes, late hyperactive behaviours (gross whole body movements and kicking) could occur.

Neurological examination revealed a mild left hand drift and a superimposed mild fast tremor, with no functional compromise. Repeated routine EEGs and brain MRI were unrevealing. The disease had followed a protracted course with daily multiple seizures. To date, the last three years were the worst with an average of 20-30 events per day. He had had very frequent drops with minor injuries, lacerations, and bone fractures. Daily activities were greatly reduced and he was eventually restricted at home.

He had had multiple adequate and unsuccessful drug trials. At the time of presurgical evaluation, he was taking phenytoin at 300 mg/24hr, levetiracetam at 4,000 mg/24hr, oxcarbazepine at 2,100 mg/24hr, phenobarbital at 150 mg/24hr and clobazam at 40 mg/24hr. He also experienced significant medication side effects (dizziness, lack of coordination, and depression).

Case report: investigations

Video-EEG was performed using a 32-channel system, extendable to 128 channels for invasive recordings. Structural and functional imaging was performed on a 1.5T MR scanner. A 32-channel MR-compatible system (amplifier and cap) was used for EEG-fMRI. Functional data were pre-processed and statistically analysed by SPM8. Electrical cortical stimulation (ECS) was per-

formed by a current-controlled stimulator through subdural grid electrodes (see Addendum for a detailed description).

Case report: results

Surface video-EEG revealed interictal sharply-contoured theta waves over Cz (*figure 1A*) and less frequently over P4 (*figure 1B*). Ictal EEG consisted of a low-amplitude fast frequency (14-16 Hz) discharge over the anterior midline (Fz/Cz) and fronto-central electrodes (F3/F4 and C3/C4) with a right-sided predominance for most events (*figure 1C*). A recent MRI scan revealed an abnormality of the right premotor region, consisting of cortical thickening, blurring of the grey to white matter transition and hyperintense white matter signal, assuming a conical shape with the base lying at the cortical lesion and tip reaching the lateral ventricle across the white matter (*figure 2A₁, A₂*). fMRI of the sensorimotor areas disclosed close proximity of the lesion to the anterior border of the activated cortical areas (*figure 2B₁, B₂*; in green). EEG-fMRI revealed minor interictal spiking-triggered BOLD changes over the primary motor area (*figure 2B₁, B₂*; in blue), however, a typical seizure recorded during the scan demonstrated activation of both the primary sensorimotor strip and posterior lesion area (*figure 2B₁, B₂*; in red). Invasive EEG was suggested after thorough discussion with the patient regarding the significant risk of not being able to fully resect the epileptogenic region (or not being able to proceed to any resection at all).

The patient was implanted with a subdural 8 × 6 grid over the right superior, lateral fronto-central and parietal area, covering the MRI-visible lesion, and two 1 × 6 strips placed over the medial hemispheric surface covering the superior frontal, supplementary motor and primary medial sensorimotor cortex (electrodes 28, 29, 30, 36, 37, 38, 44, 45, and 46 were covering the dysplastic area) (*figure 2C*). Almost continuous 1-2 Hz interictal spiking was recorded over contacts 25 to 28, 33 to 37, 41-44 (all overlying primary sensorimotor cortex, confirmed by ECS), and over medial strip contacts 61 to 63 (overlying primary sensorimotor [leg] cortex, confirmed by ECS) (*figure 3A*). Multiple typical seizures were recorded, with ictal EEG onset consisting of an initial attenuation of background activity and evolution of low-voltage fast rhythms, initially involving grid contacts 41-44, 25-28, 33-37, rapidly propagating to medial central (61-63) contacts (*figure 3B*). Onset of clinical manifestations was synchronous with initial electrocorticographic change, consisting of face grimacing, tonic posturing of both arms, tonic trunk flexion and, within the second second of the EEG change, clonic left arm activity.

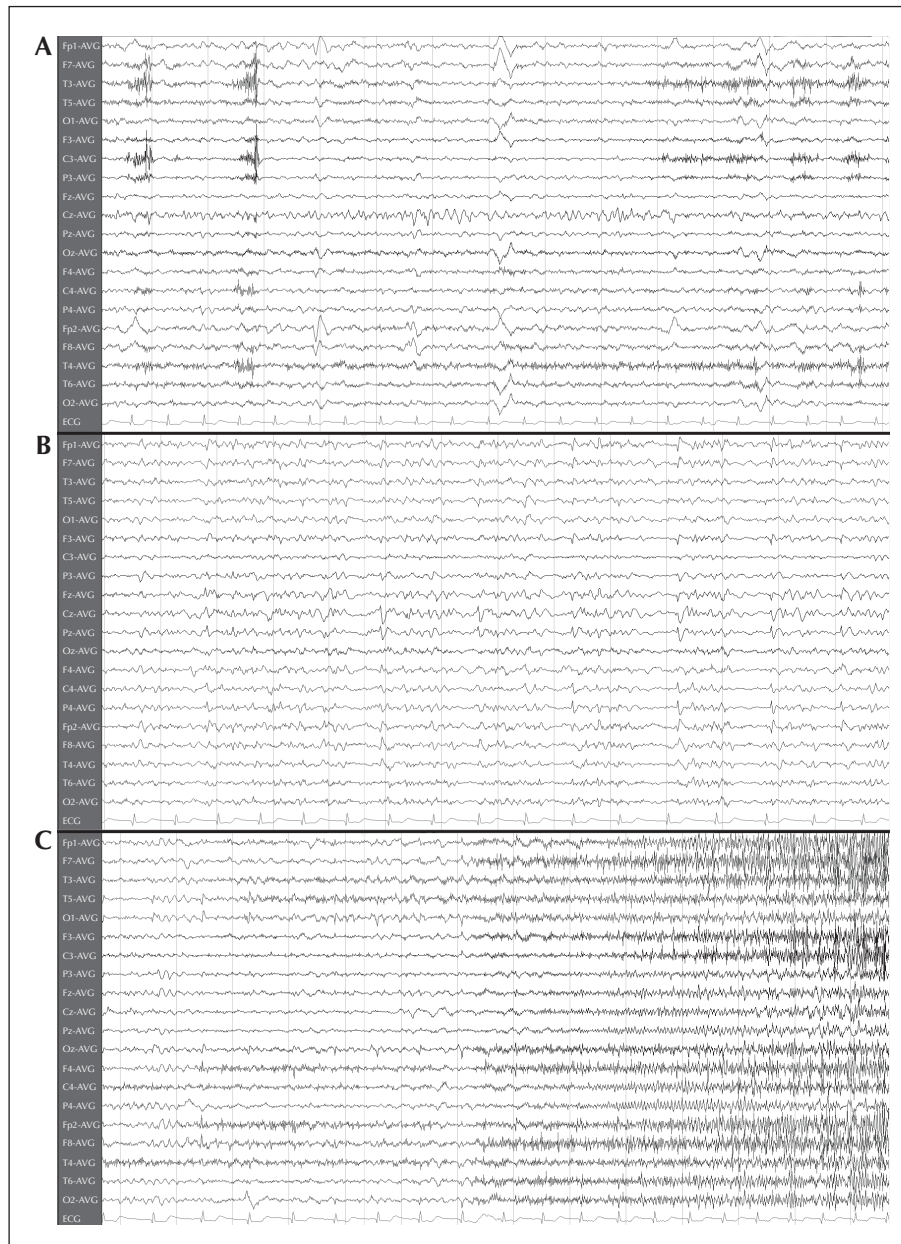


Figure 1. Non-invasive EEG study.

(A) Interictal surface EEG showing sharply-contoured theta waves over Cz, and (B) less frequent P4 spiking. (C) Ictal scalp EEG showing a diffuse EEG attenuation before the appearance of a fast rhythmic activity with a right-sided predominance.

Given the overlap between interictal spiking over the sensorimotor strip and early ictal ECoG onset changes, a decision was taken for a limited resection of the lesion and epileptogenic zone (*figure 3D*). This involved the anterior part of the malformation, corresponding to electrodes 21-23, 29-31, 37-39, being secondarily involved with ictal activity. Acute post-resection ECoG revealed gross reduction of epileptic activity over the sensorimotor area and preservation of

epileptic activity over the non-resected medial hemispheric areas (*figure 3C*). Histopathology revealed type IIb FCD (Palmini *et al.*, 2004; Blümcke *et al.*, 2011). On postoperative days one to three, the patient had multiple acute seizures. He then remained seizure-free until postoperative month 10, with occasional seizures associated with reductions in drug dosage. Due to troublesome medication side effects, levetiracetam was discontinued by month 10 and oxcarbazepine total

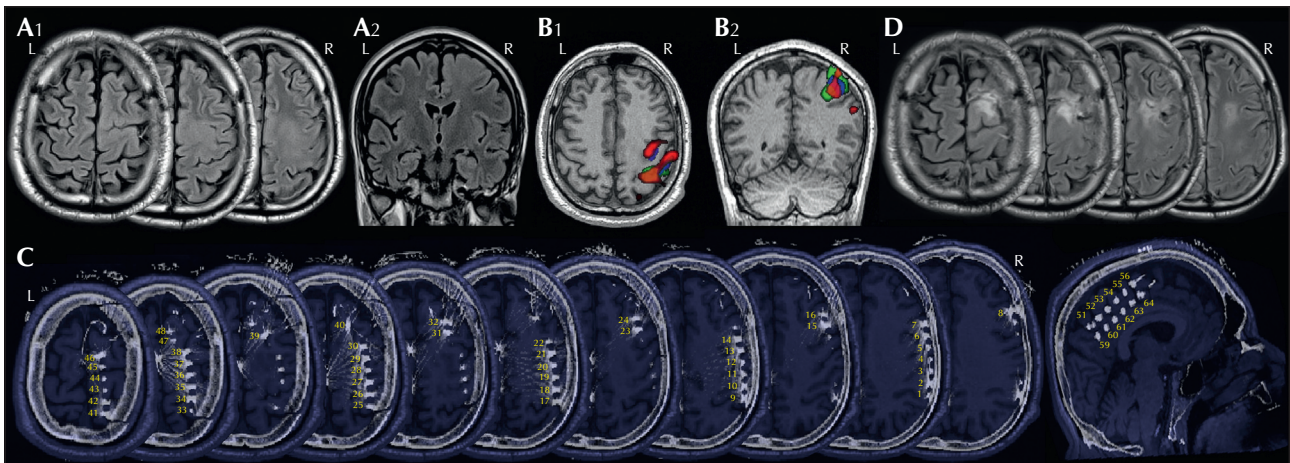


Figure 2. Imaging and invasive ECoG study.

(A₁) Pre-operative axial FLAIR MRI slices showing the FCD site over the right pre-motor and motor areas. (A₂) Pre-operative coronal FLAIR MRI slices highlighting the transmantle sign of the FCD. (B₁) Axial view overlapping functional data: left hand motor task BOLD response highlighting the primary motor cortex is shown in green, BOLD response of the interictal Cz theta waves over the primary motor cortex (plus a minor premotor activation) is depicted in blue, and ictal BOLD response maximising in the posterior border of the premotor area, with a secondary activation over the primary motor region, in red. (B₂) Coronal view overlapped by functional data. (C) Presurgical T1 3D isotropic MR sequence co-registered with post-implantation 3D isotropic CT image showing intraoperative subdural grid electrode positioning covering sensorimotor-premotor areas over the lesion area, and strip electrode positions over the medial hemispheric fronto-central cortex. (D) Post-operative axial FLAIR MRI showing partial FCD resection which included the area of maximum ictal EEG-fMRI (note that the orientation of post-surgical slices is slightly different from that of the pre-surgical slices).

daily dosage reduced to 1,500 mg by month 11. In his current state at 15 months post-surgery, he is experiencing, on average, 1-2 simple partial seizures per week with much less intensity and no falls. There has been no change in his neurological examination compared to pre-operative status.

Discussion

Our case supports the possibility that positive outcome following FCD epilepsy surgery may be achieved even after partial removal of the epileptogenic zone and lesion. Full resection of both the MRI abnormality and epileptogenic zone in FCD epilepsy surgery is associated with a better postoperative outcome and seizure-free rates ranging between 70 and 80%. Following partial FCD resection only, seizure-free outcomes vary between 20 and 40% (Kim *et al.*, 2009; Krsek *et al.*, 2009a; Krsek *et al.*, 2009b; Perry *et al.*, 2010; Chang *et al.*, 2011), demonstrating that among patients offered partial resections there are some that, “against the odds”, respond favourably. We recognise that our patient is not completely seizure-free, however he enjoys a greater than 90% seizure reduction compared to his pre-operative status, the seizures are much less intense, he has had no further injuries since surgery and was able to reduce drug-load and get considerable relief from side effects. Given that the rationale of the intervention was to offer the patient a

better quality of life and limit seizure-related injuries rather than complete seizure freedom, the surgical outcome so far was deemed successful. It could be argued that a better result may be achieved by a more extensive resection of the lesion to include the anterior dorso-medial part; this was avoided, however, due to concerns about damaging leg motor areas given the positive motor responses to ECS of nearby medial strip electrodes.

Pre- or peri-operative features predictive of a successful outcome with limited resections are not known. It is reasonable to assume that even partial removal of epileptogenic areas, may, in some circumstances, reduce excitatory inputs critical for seizure generation. Inhibitory influences arising from brain areas adjacent to, or remote to the epileptogenic zone, may also play a role. In a recent report (Palmini, 2010), release of inhibitory mechanisms between rolandic regions was proposed to account for two cases of *de novo* intractable rolandic seizures, following an initial FCD resection from the contralateral rolandic region. Our patient, in spite of having a long history of very frequent simple partial seizures, had had only occasional secondary generalised seizures and no episodes of status epilepticus. Whatever the mechanism, this might be indicative of efficient inhibition, somehow constraining ictal propagation.

With regards to histopathology subtype, a better outcome is predicted, in general, for type IIb FCD, compared to non-balloon cell FCD, given complete




Figure 3. Intracranial ECoG study.

(A) Interictal spiking recorded over the primary sensorimotor cortex (intracranial grid contacts 25 through 28 and 33 through 37), anterior to the primary sensorimotor strip (over contacts 41 through 45), and over the medial strip contacts 61 through 63. (B) Intracranial ictal EEG pattern involving sensorimotor cortex grid contacts (25-28 and 33-37), rapidly propagating to premotor (41-45) and medial central (61-63) contacts. (C) Post-resection intracranial EEG, showing gross reduction of epileptic activity over the sensorimotor region and preservation of epileptic activity over the non-resected medial hemispheric areas (non-detecting electrodes were either over the resected area or made poor contact after the resection).

resection of the lesion and epileptogenic zone is provided (Tassi *et al.*, 2002; Urbach *et al.*, 2002; Lerner *et al.*, 2009; Sarkis *et al.*, 2010); however, it is not known if this holds true following partial resections only.

There are some interesting features regarding the presurgical evaluation of data with implications for prognosis. In our case, both subdural electrode monitoring and interictal/ictal EEG-fMRI suggested only partial, nevertheless congruent, involvement of the

posterior part of the lesion and normal appearance on MRI adjacent sensorimotor cortex. Subdural electrodes over the medial part of the lesion recorded prominent epileptic activity, nevertheless without concomitant BOLD changes on EEG-fMRI. The reverse was true for the malformed portion, anterior to the sensorimotor strip, which did not produce prominent spiking; ictal events during EEG-fMRI showed BOLD increases over this portion, accompanied by concomitant BOLD changes over the sensorimotor cortex.

Our findings are in agreement with acute intraoperative ECoG data (Palmini *et al.*, 1995), reporting robust and continuous spiking not only from the visible cortical dysplasia itself but, in addition, from adjacent seemingly normal cortical areas. Our findings are also in agreement with chronic subdural recording data (Boonyapisit *et al.*, 2003; Marusic *et al.*, 2002), suggesting that the epileptogenic potential is not uniform all over the FCD surface; these studies present evidence that areas overlying balloon cells (type IIb pathology) may be non-epileptogenic and functionally inactive, while main generators of interictal spiking and ictal onsets are found to be balloon cell-devoid dysplastic areas. Evidence against a major contribution of balloon cells to epileptogenicity is also provided by basic neuroscience data (Cepeda *et al.*, 2003).

In contrast to the above mentioned reports, studies based on sEEG monitoring with intralesional recordings (Chassoux *et al.*, 2000; Tassi *et al.*, 2002; Francione *et al.*, 2003) have documented almost continuous spiking and epileptogenic zone localisation within type IIb FCD. Discrepancies between sEEG/intralesional and subdural recordings in detecting abnormal activity from FCD might be related to different sensitivities of each technique, as they target different parts of the lesion. Depending on the location and configuration of FCD, subdural electrodes may not detect abnormal activity arising from within the lesion and the deeper parts of the lesion, as they provide only superficial coverage of the cortical surface. Depth electrodes might therefore be more advantageously placed to sample abnormal activity in such cases, albeit with a compromise for superficial coverage, especially with extensive lesions.

Interictal EEG-fMRI studies in a, as yet, limited number of FCD cases have consistently reported BOLD signal increases within the FCD and variable effects in adja-

cent or remote cortical regions, including decreases or no changes at all from peri-lesional adjacent cortex (Federico *et al.*, 2005) or signal increases in adjacent or remote functionally connected or non-connected regions (Tyvaert *et al.*, 2008). In this regard, it is important to note, based on the ictal EEG-fMRI of our case, the co-activation of both sensorimotor strip and the anterior-lateral part of the lesion which was not highly active during subdural ECoG recordings. This area was grossly included in the resection, and this may be possibly related to the positive outcome. Ictal EEG-fMRI might be helpful, in this regard, for shaping the limits of resection, by revealing epileptogenic cortex not clearly appreciated or not covered by intracranial electrodes. This should be verified in prospective studies.

We certainly do not suggest that surgery should be performed for every case of FCD, even if only partial resection is feasible. We stress that the most significant factor predictive of a better outcome, *i.e.* feasibility of complete resection of lesion and epileptogenic zone, should guide the presurgical evaluation process and the surgical strategy. We have found our case to be instructive in two respects. First, even seemingly fully resectable FCD (by MRI criteria) may ultimately prove more complicated with regards to the organisation of the epileptogenic zone, especially in the vicinity of eloquent cortex, often resulting in an inability to fully resect the epileptogenic substrate. Second, our case provides clues that EEG-fMRI might be helpful in revealing, pre-operatively, epileptogenic areas distant from the principal MRI lesion and thus aid the assessment for an optimal resection, as well as guide intracranial electrode placement and shape the limits of resection if an invasive investigation is decided. □

Disclosure.

The authors acknowledge the contribution of neuropathologist Ingmar Blümcke of the University of Erlagen, neuroradiologist Stefanos Finitis, the radiology technicians of "St. Louke's" Hospital: Konstantinos Anthis, Michalis Bakaloudis, Georgios Chatzifetkos, Christos Zacharias, and the neurosurgical team: Konstantinos Kontogiannis and Anthi Stamkopoulou. We thank Dr Helmut Laufs of the University of the Johann Wolfgang Goethe University for licensing the use of MatLab scripts for EEG-fMRI analysis.

None of the authors has any conflict of interest to disclosure.

Addendum: methods

Thirty-two-channel video-EEG signals were AC recorded, amplified by x1000 (Pro Amp, LaMont Medical Inc., Wisconsin, USA), band-pass filtered at 0.1-500 Hz, digitised at 16-bits, sampled at 2 kHz by Harmonie (Stellate, Montreal, QC, Canada), and stored on hard disk along with concurrent video streams. Invasive EEG recordings were performed by the same system extended to 128 channels, sampling the cortex through intracranial subdural electrode grids (Dixi Microtechniques, Besançon, France).

Functional imaging was comprised of gradient-echo T2*-weighted single-shot echo-planar images (45 2.5 mm slices of 0.3 mm interslice distance, TE/TR: 45/4000 msec, 90° flip angle, FOV 240 cm², 96 × 96 matrix, iPAT), acquired by a 1.5T Avanto scanner (Siemens AG, Germany). Structural MRI T1 and FLAIR sequences were sampled by the same MR scanner. CT images were acquired by a Somatom Definition scanner (Siemens AG, Germany). A 32-channel MR-compatible electrode cap (BrainCap MR, Easycap, Herrsching-Breitbrunn, Germany) was used for EEG-fMRI, signals were amplified by x1500, band-pass filtered at 0.01 Hz-1 kHz, digitised at 16-bit and sampled at 5 kHz by a MR-compatible BrainAmp system (BrainAmp MR plus, Brain Products, Munich, Germany). Statistical Parametric Mapping (SPM8; <http://www.fil.ion.ucl.ac.uk/spm/>) was used for analysis, after pre-processing (realignment to the mean by 2.5 mm B-Spline interpolation, 8 mm Gaussian kernel smoothing) at a threshold of $P < 0.001$ (uncorrected). Overlap of functional data was performed by means of MRICron. Co-registration of MR with CT was realised with Brain Voyager QX (Brain Innovation, Maastricht, Netherlands).

Electrical Cortical Stimulation (ECS) was performed by a Nimbus constant-current cortical stimulator (Newmedic, Labège, France). Stimulation comprised of 50 Hz pulses for 5 sec at intensity steps of 1 mA (beginning from 1 mA) until clinical symptoms appeared or after discharges.

References

- Blümcke I, Thom M, Aronica E, et al. The clinicopathologic spectrum of focal cortical dysplasias: A consensus classification proposed by an ad-hoc Task Force of the ILAE Diagnostic Methods Commission. *Epilepsia* 2011;52: 158-74.
- Boonyapisit K, Najm I, Klem G, et al. Epileptogenicity of focal cortical malformations due to abnormal development: Direct electrocorticographic-histopathologic correlations. *Epilepsia* 2003; 44: 69-76.
- Cepeda C, Hurst RS, Flores-Hernandez J, et al. Morphological and electrophysiological characterization of abnormal cell types in pediatric cortical dysplasia. *J Neurosci Res* 2003;72: 472-86.
- Chang E, Wang D, Barkovich J, et al. Predictors of seizure freedom after surgery for malformations of cortical development. *Ann Neurol* 2011;70: 151-62.
- Chassoux F, Devau B, Landre E, et al. Stereoelectroencephalography in focal cortical dysplasia. A 3D approach to delineating the dysplastic cortex. *Brain* 2000;123: 1733-51.
- Colombo N, Salamon N, Raybaud C, Ozkara G, Barkovich JA. Imaging of malformations of cortical development. *Epileptic Disord* 2009; 11: 194-205.
- Federico P, Archer JS, Abbott DF, Jackson GD. Cortical/subcortical BOLD changes associated with epileptic discharges. *Neurology* 2005; 64: 1125-30.
- Focke NK, Symms MR, Burdett JL, Duncan JS. Voxel-based analysis of whole brain FLAIR at 3T detects focal cortical dysplasia. *Epilepsia* 2008; 49: 786-93.
- Francione S, Nobili L, Cardinale F, Citterio A, Galli C, Tassi L. Intra-lesional stereo-EEG activity in Taylor's focal cortical dysplasia. *Epileptic Disord* 2003; 5: 105-14.
- Kim DW, Lee SK, Chu KI, et al. Predictors of surgical outcome and pathologic considerations in focal cortical dysplasia. *Neurology* 2009;72: 211-6.
- Krsek P, Pieper T, Karlmeier A, et al. Different presurgical characteristics and seizure outcomes in children with focal cortical dysplasia type I or II. *Epilepsia* 2009a;50: 125-37.
- Krsek P, Maton B, Jayakar P, et al. Incomplete resection of focal cortical dysplasia is the main predictor of poor surgical outcome. *Neurology* 2009b; 72: 217-23.
- Lerner JT, Salamon N, Hauptman JS, et al. Assessment and surgical outcomes for mild type I and severe type II cortical dysplasia: A critical review and the UCLA experience. *Epilepsia* 2009;50: 1310-35.
- Marusic P, Najm I, Ying Z, et al. Focal Cortical Dysplasias in eloquent cortex: Functional characteristics and correlation with MRI and histopathologic findings. *Epilepsia* 2002; 43: 27-32.
- Palmini A. Electrophysiology of the focal cortical dysplasias. *Epilepsia* 2010;51: 23-6.
- Palmini A, Gambardella A, Andermann F, et al. Intrinsic epileptogenicity of human dysplastic cortex as suggested by electrocorticography and surgical results. *Ann Neurol* 1995;37: 476-87.
- Palmini A, Najm I, Avanzini G, et al. Terminology and classification of the cortical dysplasias. *Neurology* 2004; 62: S2-S8.
- Perry MS, Dunoyer C, Dean P, et al. Predictors of seizure freedom after incomplete resection in children. *Neurology* 2010;75: 1448-53.
- Sarkis RA, Jehi LA, Bingaman WE, Najm IM. Surgical outcome following resection of rolandic focal cortical dysplasia. *Epilepsy Res* 2010; 90: 240-7.

Tassi L, Colombo N, Garbelli R, *et al.* Focal cortical dysplasia: Neuropathological subtypes, EEG, neuroimaging and surgical outcome. *Brain* 2002; 125: 1719-32.

Tyvaert L, Hawco C, Kobayashi E, LeVan P, Dubeau F, Gotman J. Different structures involved during ictal and interictal activity in malformations of cortical development: an EEG-fMRI study. *Brain* 2008; 131: 2042-60.

Urbach H, Scheffler B, Heinrichsmeier T, *et al.* Focal Cortical Dysplasia of Taylor's balloon-cell type: a clinicopathological

entity with characteristic neuroimaging and histopathological features and favorable post-surgical outcome. *Epilepsia* 2002; 34: 33-40.

Widdess-Walsh P, Jeha L, Nair D, Kotagal P, Bingaman W, Najm I. Subdural electrode analysis in focal cortical dysplasia: predictors of surgical outcome. *Neurology* 2007; 69: 660-7.

Woermann FG, Volmar C. Clinical MRI in children and adults with focal epilepsy: A critical review. *Epilepsy Behav* 2009; 15: 40-9.