

Partial seizures triggering infantile spasms in the presence of a basal ganglia glioma

Rajesh RamachandranNair¹, Ayako Ochi¹, Tomoyuki Akiyama¹, David J. Buckley², Teesta B. Soman¹, Shelly K. Weiss¹, Hiroshi Otsubo¹

¹ Division of Neurology, The Hospital for Sick Children, University of Toronto, Canada

² Division of Pediatric Neurology, Janeway Children's Health and Rehabilitation Centre, Canada

Received March 7, 2005; Accepted August 10, 2005

ABSTRACT – Infantile spasms associated with brain tumors have been reported. A focal cortical lesion can induce infantile spasms by triggering the brainstem and basal ganglia in this vulnerable age group. We report the case of a female infant with a low-grade glioma in the right basal ganglia, spreading to the cortical area. She presented at the age of five months with left hemiparesis and partial seizures. She developed infantile spasms at the age of 12 months. This is the first video clip report of partial seizures triggering symmetrical spasms in series, secondary to a basal ganglia glioma extending to the cortex.

[Published with video sequences]

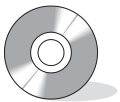
Key words: infantile spasms, partial seizures, basal ganglia glioma, tumor

Sixteen cases of infantile spasms associated with brain tumors have been reported (table 1). Structural lesions in the brain cause focal neurological deficits and partial seizures. The fundamental pathogenesis of infantile spasms is still unknown (Frost and Hrachovy 2005). A focal cortical lesion can induce infantile spasms by triggering the brainstem and basal ganglia at a vulnerable age (Yamamoto *et al.* 1988). We report the case of a baby girl with a low-grade glioma in the basal ganglia, spreading to the cortical area. It presented as hemiparesis, partial seizures and later, infantile spasms. This is the first video clip report of a glioma in the basal ganglia extending to the cortex producing infantile spasms combined with partial seizures.

Case report

A 17-month-old girl was evaluated for intractable epilepsy and developmental delay. She was born at term to non-consanguineous parents. There was no family history of seizures or mental retardation. Birth weight was 2.8 kg and the Apgar score was 10 at five minutes. She attained social smile at eight weeks, head control at four months and was able to roll from supine to prone position at five months. Mother had noticed paucity of movements of the left upper and lower extremities since three months. She had an early right-hand preference.

At the age of five months, she had a partial seizure involving the left side of body with secondary generalization



Correspondence:

H. Otsubo MD
Division of Neurology,
The Hospital for Sick Children,
University of Toronto,
555 University Avenue,
Toronto,
Canada M5G 1X8.
Tel.: (+00 1) 416 813 6660
Fax: (+00 1) 416 813 6334
<hiroshi.otsubo@sickkids.ca>

Table 1. Brain tumors associated with infantile spasms.

Patient No	Authors	Age at onset	Type of Sz	EEG	Pathology	Location
1	Aktan <i>et al.</i> 1997	15 mo	IS	No HA	Medullary epithelioma	Posterior fossa
2	Asanuma <i>et al.</i> 1995	6 mo	IS	HA	Hamartoma	Hypothalamus
3	Asanuma <i>et al.</i> 1995	7 mo	IS	HA	Oligoastrocytoma	R-temporal
4	Askenasi and Snead 1991	4 mo	IS, CPS (at 7 yrs)	No HA	Ganglioglioma	R-frontal
5	Branch and Dyken 1979	7 mo	IS	HA	Choroid plexus papilloma	L-lat ventricle
6	Gabriel 1980	13 weeks	IS; PS	No HA	Glioma	R-hemispheric
7	Gastaut <i>et al.</i> 1978	ND	IS	ND	? Calcified mass	Basal ganglia
8	Kurokawa <i>et al.</i> 1980	ND	IS	ND	Glioma	Optic nerve
9	Mimaki <i>et al.</i> 1983	19 mo	IS	HA	Astrocytoma	L-temporal
10	Ohtahara <i>et al.</i> 1993	ND	IS	HA	Cavernous angioma	Frontotemporal
11	Otsubo <i>et al.</i> 1999	30 mo	IS, PS (at 5 yrs)	No HA	Glioma	R-temporal
12	Ruggieri <i>et al.</i> 1989	4.5 mo	IS; PS	HA	Glioma	R-thalamus
13	Ruggieri <i>et al.</i> 1989	7 mo	IS	HA	Ependymoma	R-FTP
14	Shields <i>et al.</i> 1992	ND	IS	ND	Glioma	L-parietal
15	Wyllie <i>et al.</i> 1996	14 mo	IS	HA	Astrocytoma	L-temporal
16	Ohtsuka <i>et al.</i> 1996	ND	IS, PS	HA	Ganglioglioma	L-frontal
17	RamachandranNair <i>et al.</i>	5 mo	PS, IS	HA	Glioma	R-basal ganglia

Sz- seizure, mo- months, IS- infantile spasm, PS- partial seizures, CPS- complex partial seizures, HA- hypsarhythmia, ND-no details, R- right, L- left, FTP- frontotemporoparietal, Lat- lateral.

for 30 minutes without fever. Subsequently she had recurrent partial seizures with variable frequency and duration. The partial seizures consisted of facial and eye deviation to the left side with tonic posturing followed by clonic movements of the left extremities.

At the age of 12 months, flexor spasms of upper extremities began in addition to the partial seizures. Partial seizures failed to respond to phenobarbital and oxcarbazepine. The spasms did not respond to pyridoxine and vigabatrin. At 17 months, she was able to sit for a few seconds without support and speak in disyllables. Her head circumference was 45 cm (50%). She had left hemiparesis. There were no neurocutaneous markers.

At the age of 16 months, a prolonged scalp video EEG (VEEG) monitoring was performed. Three clusters of seizures were captured over 3 days and all the seizures were identical. At the beginning of seizure No 3 (see video sequence), she was unresponsive, with her eyes open and resting left arm and leg. Automatisms of her right arm and leg followed. She regained consciousness and began to move her left limbs, 20 seconds after the beginning of seizure. Sixty seconds after the seizure onset, brief spasms consisting of quasiperiodic axial flexion, extension of arms and legs started at intervals of 10-15 seconds. The symptom of spasms was bilateral, but more prominent on the right side, presumably due to left hemiparesis. This series of spasms lasted around 2 minutes.

Seizure No 3 showed diffuse 2-2.5 Hz high amplitude spike-wave discharges and slow waves for one second at

the beginning (*figure 1A*). Diffuse voltage attenuation of 15-20 Hz low amplitude fast activities followed. The frequency and amount of fast activities gradually decreased and were replaced by diffuse 2-3 Hz delta slow waves, 20 seconds after the beginning. Sixty seconds after the seizure onset, diffuse 2-3 Hz high amplitude slow waves started with superimposed 20 Hz fast waves at times, followed by low voltage, attenuated electrodecremental activities (*figure 1B*). These complexes of slow and superimposed fast waves appeared quasiperiodically at intervals of 10-15 seconds, corresponding to each epileptic spasm. There were no asymmetrical EEG findings during the series of epileptic spasms.

High amplitude independent spike or sharp and slow waves were seen over the bilateral fronto-centro-temporal regions, at times synchronized, and followed by low amplitude voltage attenuation of electrodecremental periods. The chaotic interictal epileptiform discharges were consistent with modified hypsarhythmia. Over the right hemisphere, polymorphic delta slow waves were intermittently seen corresponding to the structural abnormality. Four to 5 Hz theta wave background activity was preserved on the left hemisphere.

MR images (Signa GE Medical systems, 1.5 Tesla) at 11 months showed a lesion involving the right globus pallidus and lentiform nucleus, extending to the right external capsule and adjacent cortical region. The lesion was hypointense on T₁-weighted images and hyperintense on T₂ and fluid attenuated inversion recovery (FLAIR) T₂ se-

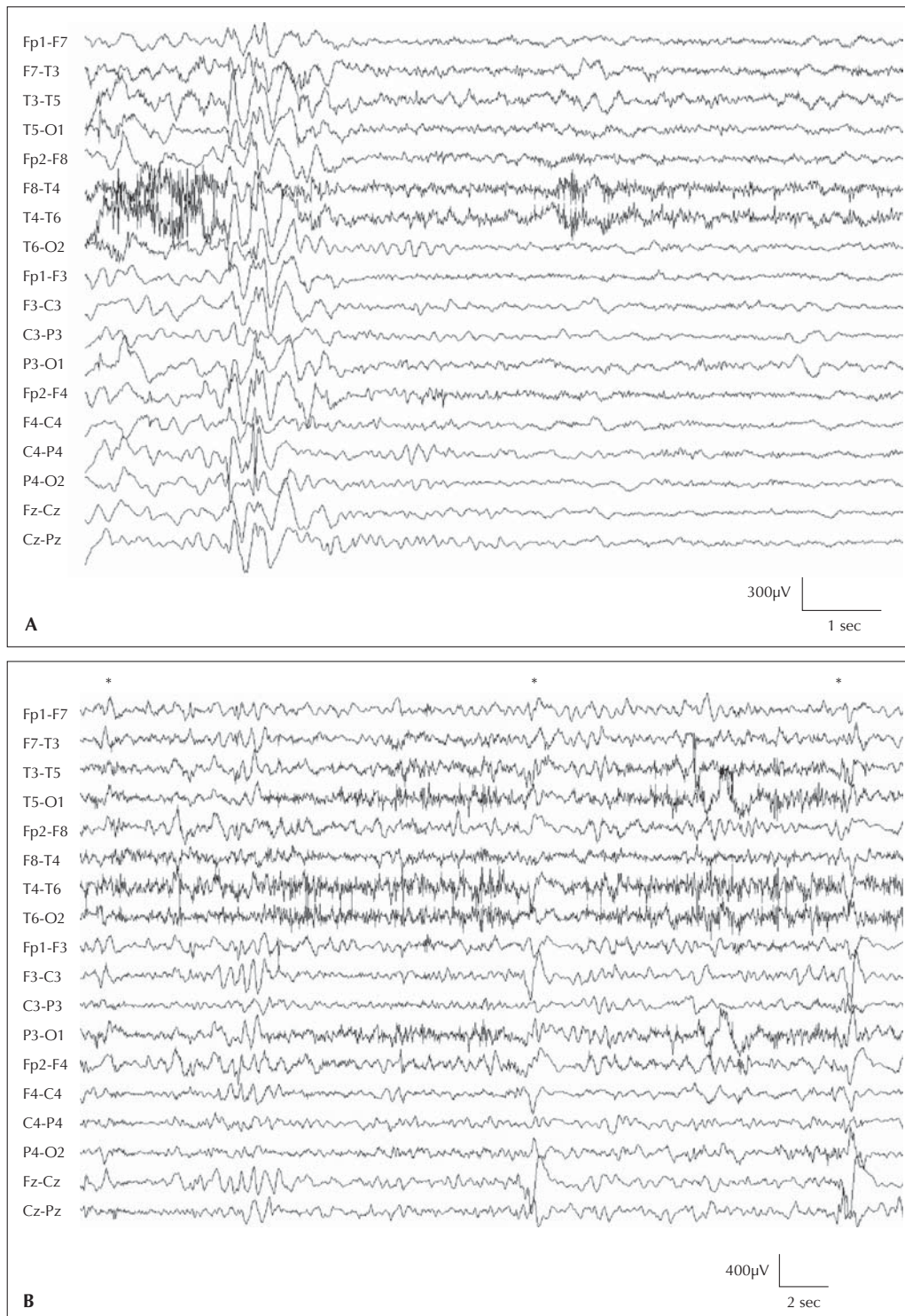


Figure 1. A) EEG showed diffuse 2-2.5 Hz high amplitude spike-wave discharges and slow waves for one second at the beginning of the seizure. Diffuse voltage attenuation of 15-20 Hz low amplitude fast activities followed. The frequency and amount of fast activities gradually decreased and the fast activities were replaced by diffuse 2-3 Hz delta slow waves 20 seconds after the beginning of seizure (low frequency filter 1.6Hz, high frequency filter 70Hz, Notch filter 60Hz). **B)** Sixty seconds after the seizure onset, diffuse 2-3 Hz high amplitude slow waves (*) started with superimposed 20 Hz fast waves at times, followed by low voltage, attenuated electrodecremental activity. These complexes of slow and fast waves appeared quasiperiodically at intervals of 10-15 seconds, corresponding to each epileptic spasm. There were no asymmetrical EEG findings during the series of epileptic spasms (low frequency filter 1.6Hz, high frequency filter 70Hz, Notch filter 60Hz).

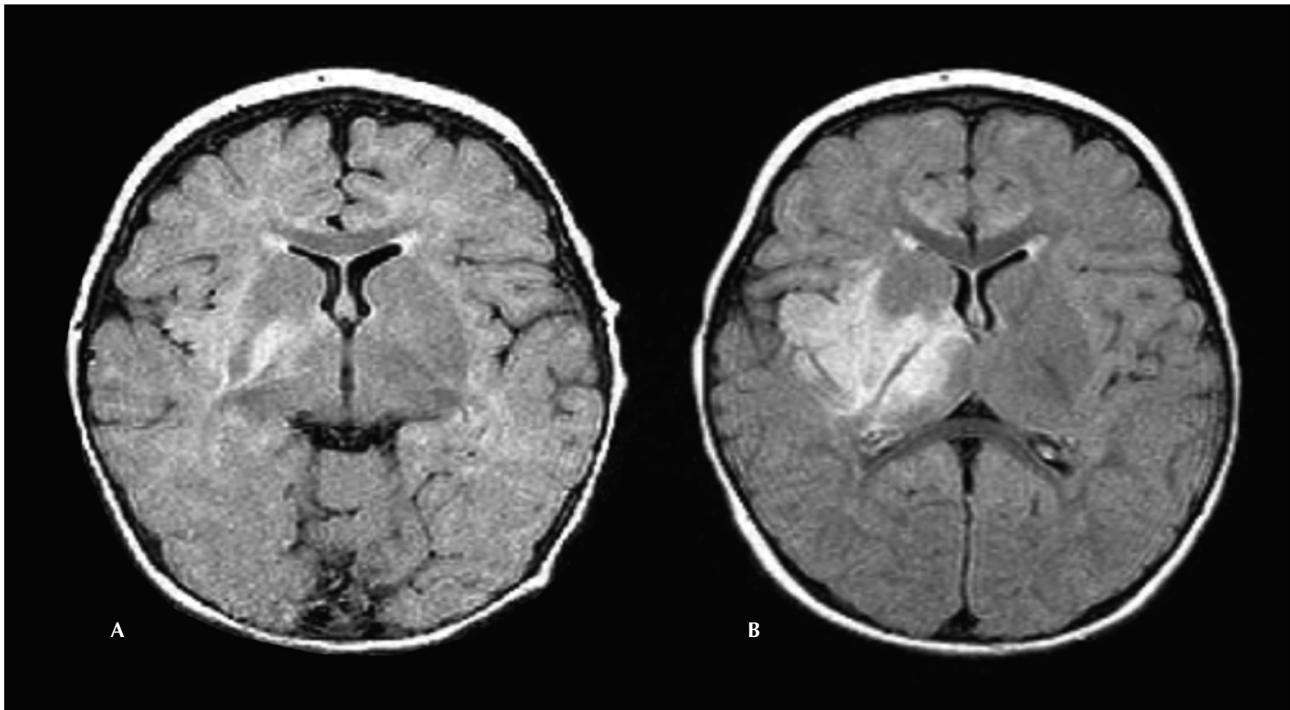


Figure 2. **A)** MRI brain; FLAIR images (TR 9002, TE 129.7, inversion time 2200) at 11 months showing the lesion involving the right globus pallidus and lentiform nucleus, which extended to the right external capsule and adjacent cortical region. **B)** Repeat MRI brain FLAIR images at 17 months shows the lesion to involve the right putamen, pallidum, thalamus, peri-Sylvian region extending into the adjacent posterior right frontal and mesial right temporal lobes with mild mass effect.

quences (*figure 2A*). Repeat MR images of brain at 17 months showed the lesion to involve the right putamen, pallidum, thalamus, peri-Sylvian region extending into the adjacent posterior right frontal and mesial right temporal lobes with mild mass effect and minimal patchy enhancement on contrast administration (*figure 2B*). A stereotaxic biopsy from the right basal ganglia at 17 months revealed a grade 2 glioma (WHO classification). The patient was started on chemotherapy, as the tumor was inoperable. She continued to have partial seizures and epileptic spasms. Topiramate was added to oxcarbazepine.

Discussion

Tumors are rare causes of infantile spasms. This is the first case of a child with infantile spasms secondary to a basal ganglia glioma spreading to the cortex. *Table 1* describes 16 cases of infantile spasms associated with brain tumors reported in the English language indexed journals. Gastaut *et al.* reported a child with infantile spasms and a calcified brain mass in the basal ganglia detected by CT brain (patient 7) (Gastaut *et al.* 1978). However, the pathology of this calcified mass was not reported. The extensive lesion of the right basal ganglia was stereotactically biopsied, confirming a low grade glioma. Although chemotherapy was started, seizures persisted in this child. The

location and type of brain tumor associated with infantile spasms may vary and can include ganglioma, ganglioglioma, glioma, ependymoma, choroid plexus papilloma, cavernous angioma and hypothalamic hamartoma (*table 1*). Glioma is the most common brain tumor in infants (Di Rocco *et al.* 1991). A low grade glioma in the basal ganglia extending to the cortex producing initial partial seizures and consecutive infantile spasms is reported for the first time.

In some children with infantile spasms, cortical lesions can induce both partial seizures and spasms (Ohtsuka *et al.* 1996). Ohtsuka *et al.* reported 18 children who had partial seizures when they had spasms. Spasms in series coexisted, preceded or were followed by partial seizures (Ohtsuka *et al.* 1996). Yamamoto *et al.* (1988) reported four cases with partial seizures evolving into infantile spasms. However, none of these children had a brain tumor. The incidence of partial seizures in infantile spasms was as high as 31% (Yamamoto *et al.* 1988, Donat and Wright 1991). Among the 16 children with infantile spasms and brain tumors, five had partial seizures (patients 4, 6, 11, 12, 16) (Askenasi and Snead 1991, Gabriel 1980, Otsubo *et al.* 1999, Ruggieri *et al.* 1989, Ohtsuka *et al.* 1996). Only 2 children (patients 6, 16) (Gabriel 1980, Ohtsuka *et al.* 1996) had spasms and partial seizures

during the same period. Seizures developed after the infantile spasms in other children (patients 4, 11, 12) (Askenasi and Snead 1991, Otsubo *et al.* 1999, Ruggieri *et al.* 1989). In our child, partial seizures developed 7 months prior to the onset of spasms. Partial seizures triggered the spasms in series with modified hypsarrhythmia since the age of 12 months.

The origin of the spasms remains uncertain. Chugani (2002) postulated a cortical- subcortical interaction as the pathogenesis, based on PET results that patients with infantile spasms had hypermetabolism in the lenticular nuclei and brainstem and hypometabolism in focal cortical areas. There were strong arguments against a major contribution of the cortex to physiological mechanism of spasms; however, cortical or hemispheric resection provided good seizure control (Chugani 2002). Ten of the 16 children became seizure-free following excision of the tumor (patients 2, 4, 5, 9-11, 13-16) (table 1). Our previous report proved that interhemispheric interactions were led by the tumor side by coherence analysis during flexor spasms (Otsubo *et al.* 1999). The early right hemispheric activation was caused by the more excitable cortex, with the glioma extending from the right basal ganglia, in this child. Furthermore, bilateral modified hypsarrhythmia was recorded since infantile spasms appeared at the age of 12 months. The basal ganglia was damaged by the main part of the tumor. Hypsarrhythmia resulted from a cortico-subcortical diffusion of interictal epileptogenic phenomena. The infantile spasms in West syndrome seem to be the final manifestation of various processes, but are believed to start on a cortical level (Vigevano *et al.* 2001). The appearance of symmetrical spasms preceded by partial seizures in this child indicated that the epileptogenic cortex was the primary driver of the infantile spasms.

Conclusion

This is the first video clip report of infantile spasms in a child with a glioma of the basal ganglia. Symmetrical

infantile spasms can originate from a focal lesion and be triggered by partial seizures at certain infantile ages. □

References

- Aktan G, Simsek A, Aysun S. Brainstem tumor with infantile spasms. *J Child Neurol* 1997; 12: 152-4.
- Asanuma H, Wakai S, Tanaka T, Chiba S. Brain tumors associated with infantile spasms. *Pediatr Neurol* 1995; 12: 361-4.
- Askenasi A, Snead 3rd OC. Infantile spasms secondary to a brain tumor. *J Child Neurol* 1991; 6: 180-2.
- Branch CE, Dyken PR. Choroid plexus papilloma and infantile spasms. *Ann Neurol* 1979; 5: 302-4.
- Chugani HT. Pathophysiology of infantile spasms. *Adv Exp Med Biol* 2002; 497: 111-21.
- Di Rocco C, Iannelli A, Ceddia A. Intracranial tumors of the first year of life. A cooperative survey of the 1986-1987 Education Committee of the ISPN. *Childs Nerv Syst* 1991; 7: 150-3.
- Donat JF, Wright FS. Simultaneous infantile spasms and partial seizures. *J Child Neurol* 1991; 6: 246-50.
- Frost JD, Hrachovy RA. Pathogenesis of infantile spasms: A model based on developmental desynchronization. *J Clin Neurophysiol* 2005; 22: 25-36.
- Gabriel YH. Unilateral hemispheric ganglioglioma with infantile spasms. *Ann Neurol* 1980; 7: 287-8.
- Gastaut H, Gastaut JL, Regis H, *et al.* Computerized tomography in the study of West's syndrome. *Dev Med Child Neurol* 1978; 20: 21-7.
- Kurokawa T, Goya N, Fukuyama Y, *et al.* West syndrome and Lennox-Gastaut syndrome: a survey of natural history. *Pediatrics* 1980; 65: 81-8.
- Mimaki T, Ono J, Yabuuchi H. Temporal lobe astrocytoma with infantile spasms. *Ann Neurol* 1983; 14: 695-6.
- Ohtahara S, Ohtsuka Y, Yamatogi Y, *et al.* Prenatal etiologies of West syndrome. *Epilepsia* 1993; 34: 716-22.
- Ohtsuka Y, Murashima I, Asano T, *et al.* Partial seizures in West syndrome. *Epilepsia* 1996; 11: 1060-7.
- Otsubo H, Steinlin M, Shirasawa A, *et al.* Interhemispheric interactions analyzed by coherence during flexor spasms. *Clin Neurophysiol* 1999; 110: 374-7.
- Ruggieri V, Caraballo R, Fejerman N. Intracranial tumors and West syndrome. *Pediatr Neurol* 1989; 5: 327-9.
- Shields WD, Shewmon DA, Chugani HT, *et al.* Treatment of infantile spasms: medical or surgical? *Epilepsia* 1992; 33(Suppl 4): S26-S31.
- Vigevano F, Fusco L, Pachatz C. Neurophysiology of spasms. *Brain Dev* 2001; 23: 467-72.
- Wyllie E, Comair YG, Kotagal P, *et al.* Epilepsy surgery in infants. *Epilepsia* 1996; 37: 625-37.
- Yamamoto N, Watanabe K, Negoro T, *et al.* Partial seizures evolving to infantile spasms. *Epilepsia* 1988; 29: 34-40.

Legend for video sequence

This segment begins with the child sitting in the lap of her grandmother. At the beginning of the seizure (video time 00:09), the patient was unresponsive, with her eyes open and resting her left arm and leg. Automatisms of her right arm and leg were subsequently seen (00:11). The patient regained consciousness and began to move her left limbs (00:40). Brief spasms consisting of quasi-periodic axial flexion, extension of arms and legs started (01:06) and quasiperiodically continued with intervals of 10-15 seconds (01:22, 34, 46). The symptom of spasms was bilateral but more prominent on the right side. These series of spasms lasted around 2 minutes.