

Pathways of seizure propagation from the temporal to the occipital lobe

Julia Jacobs, François Dubeau, André Olivier, Frederick Andermann

Montreal Neurological Institute and Hospital, Montreal, Canada

Received July 18, 2007; Accepted September 8, 2008

ABSTRACT – Propagation of ictal epileptic discharges influences the clinical appearance of seizures. Fast propagation from the occipital to temporal lobe has been well described, but until now the reverse direction of spread has not been emphasized. We describe two patients who experienced ictal propagation from temporal to occipital regions. One case presented with amaurosis during a seizure with temporal onset and temporal-occipital spread. In the second, temporal-occipital spread was documented during a seizure, which continued in the occipital lobe for six minutes. Depth electrode studies suggested the temporal ictal onset of seizures in both patients. Propagation from temporal to occipital lobe structures must be considered in the assessment of patients who have seizures with both temporal and occipital features. The propagation may have predictive value for their surgical outcome. The underlying anatomical structure might be the inferior longitudinal fasciculus.

Key words: occipital lobe epilepsy, temporal lobe epilepsy, seizure propagation, intracranial EEG, seizure spread

Clinically similar seizures may arise from epileptic foci at different sites. The actual seizure focus might be obscured by rapid propagation of the ictal epileptic activity from one brain region to another.

This has been described in patients with occipital lobe seizures spreading to the temporal lobe (Palmini *et al.* 1993). Although there are typical clinical features of occipital lobe attacks such as visual hallucinations, ictal blindness and oculomotor symptoms, patients with occipital lobe epilepsy (OLE) may also have features of temporal or frontoparietal epilepsy (Williamson *et al.* 1981). Localized occipital lobe seizures are rare, but

rapid propagation to other brain areas has been confirmed with surface as well as intracranial electrodes (Williamson *et al.* 1992, Palmini *et al.* 1993). In 50% of patients with OLE, temporal lobe automatisms have been seen (Salanova *et al.* 1992), probably related to rapid propagation from the occipital lobe to anterior temporal regions (Williamson *et al.* 1992). This pathway of propagation involves the inferior longitudinal fasciculus (Collins and Caston 1979, Olivier *et al.* 1982).

Patients with temporal lobe epilepsy (TLE) typically experience auras (e.g. epigastric and auditory), altered consciousness, automatisms and auto-

Correspondence:

J. Jacobs, MD
Montreal Neurological Institute and Hospital,
3801 University Street,
Montreal, QC, H3A2B4, Canada
<julia.jacobs@gmx.de>

mic changes (Williamson and Engel 1998). Temporal lobe seizures most commonly propagate to the contralateral side, and sometimes show secondary generalization. Additionally, propagation to the parietal and frontal cortex has often been described. However, in contrast to occipital-temporal spread, retrograde discharge from temporal to occipital areas has not been described. We report two patients where propagation of ictal discharges from the temporal to occipital structures has been documented, and discuss the clinical significance of this finding.

Case study

Patient 1

This 30-year-old man had experienced neonatal seizures due to hypoglycaemia following normal delivery, and one febrile convulsion at 19 months of age. Epilepsy started at age 18 years and typical seizures consisted of altered consciousness and automatisms of the right arm, followed by postictal headache and fatigue. He described an inconsistent aura of an anxious feeling with tachycardia, and occasionally a visual scotoma consisting of flashes. An-MRI was normal. He had a global IQ of 107, with difficulties performing the abstract verbal tasks and discrete impairment of sensory-motor function of the left hand. Fourteen attacks recorded during telemetry originated in the right hemisphere: seven started from the mesiobasal temporal region, and in the other seven onset was less well localized. Five seizures remained confined to the right hemisphere, seven showed propagation to the left and two were secondarily generalized. Interictal discharges occurred bilaterally over the temporal lobes, predominantly over the right, with phase reversal at F8-T4 and SP2-T4. To confirm the region of seizure-onset, four depth electrodes were implanted stereotactically using a tangential approach aiming at the amygdala, the anterior and posterior hippocampus, as well as the temporo-occipital junction in each temporal lobe. Epidural contacts covered the first temporal gyrus, the posterior temporal area and the supramarginal and angular gyri on both sides. Twenty-eight clinical and EEG seizures were recorded showing a regional temporal onset, 46% of them (13/28) with posterior temporal neocortical accentuation. Twenty-two propagated to the left temporal areas. Interictal spikes were seen over the right hippocampus as well as the right posterior temporal neocortex. A typical seizure could be triggered by stimulating the right anterior hippocampus at 0.5 mA. Based on these findings, a palliative, selective amygdalo-hippocampectomy was proposed to the patient, following which the patient continued to have fewer, smaller seizures.

Temporo-occipital propagation of the ictal epileptic discharges: this was recorded on one occasion by surface EEG. The seizure started over the right posterior temporal region. Eye and head deviation to the left were the first

clinical symptoms. After five seconds, the ictal discharge propagated to the anterior temporal region. At this point the patient awoke and was able to answer questions while the seizure continued. This was followed by rapid spread of the seizure to the ipsilateral occipital lobe. Within seconds he complained of sudden blindness and was unable to see and identify objects presented by the EEG technician. Ictal amaurosis persisted for a minute until the seizure ended (*figure 1*). In no other seizure had he described ictal amaurosis. During that seizure, HMPAO was injected for an ictal SPECT, which revealed tracer enhancement in the right temporal lobe with extension to the occipital lobe (*figure 2*).

Patient 2

This 25-year-old woman presented with a history of perinatal asphyxia, mild developmental delay and left hemiparesis. MRI showed extensive atrophy of the right hemisphere, with a porencephalic cyst. Typical seizures started with an auditory aura accompanied by a bad smell and a warm sensation in the left arm, followed by impaired consciousness, automatisms consisting mostly of pointing of the right arm, and secondary generalization.

During telemetry, three ictal events were localized to the right temporo-fronto-central region, followed by rhythmic sharp waves over the anterior temporal region. In the interictal EEG, discharges were observed over the right hemisphere with a predominance in the right temporal region.

She underwent a depth electrode investigation with electrodes implanted tangentially in the right amygdala, Heschl's gyrus, anterior and posterior hippocampus. Epidural electrodes covered the central region, and angular and supramarginal gyri. Four seizures originated in the hippocampus: one electrographic seizure propagated exclusively to the posterior hippocampus and three clinical seizures spread to Heschl's gyrus and the temporo-parietal junction. Interictal spike-wave and polyspike waves were observed in the posterior portion of the hippocampus. Spikes were also recorded in the amygdala and anterior hippocampal electrode, but none in Heschl's gyrus. A typical seizure was evoked by stimulating the anterior hippocampus at 1.6 mA. The patient underwent selective amygdalo-hippocampectomy, but continued to have seizures, although seizure frequency was reduced by about 80%. After a second surgery, with more extensive removal of the neocortical temporal structures nine months before this report was written, the patient became seizure-free.

Temporo-occipital propagation of the ictal epileptic discharges: this was observed in one nocturnal event during scalp-EEG. The first EEG changes consisted of irregular sharp waves over the right temporal lobe. She awoke, had automatisms consisting of pointing with the right hand with vocalizations. Afterwards, she laid back and showed clonic movements of both arms. She turned her head to the left and propagation from the temporal to the ipsilat-

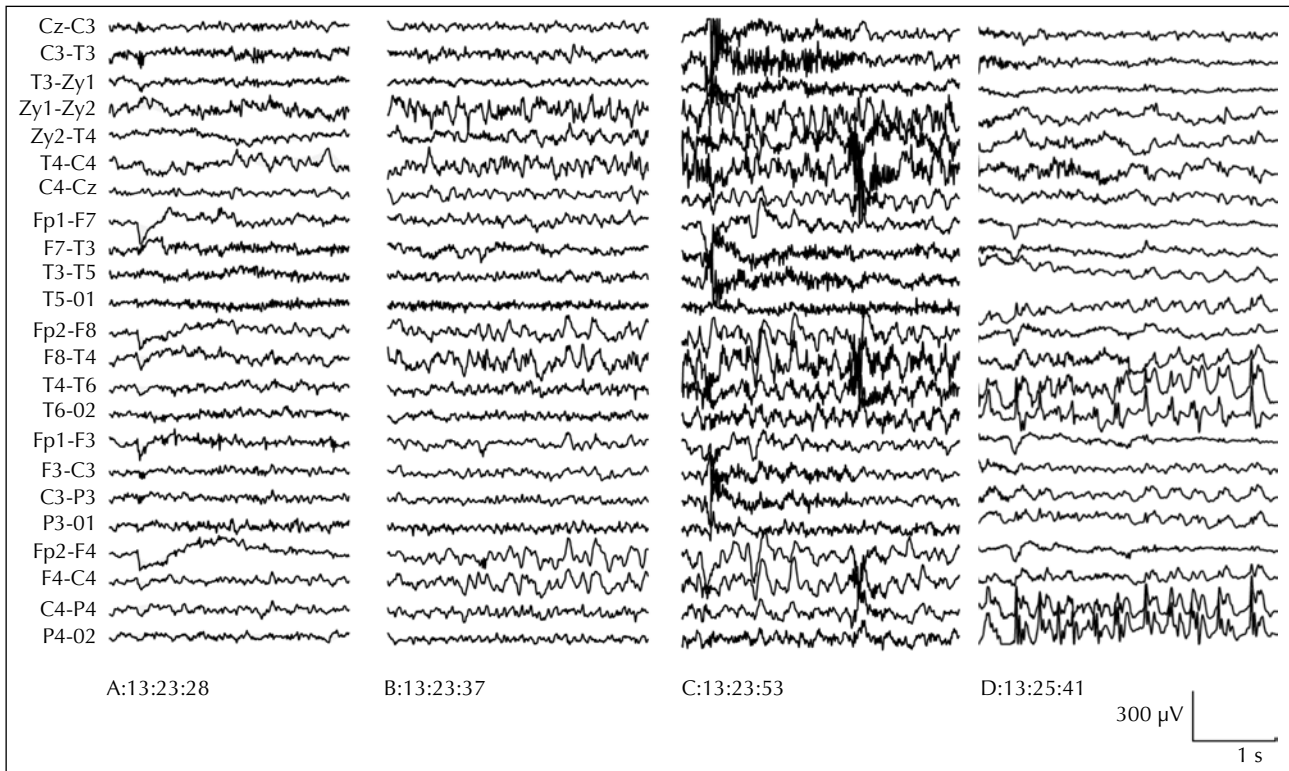


Figure 1. This figure presents the seizure propagation of patient 1 in a telemetry study with zygomatic electrodes. The seizure started over the right temporal region, with initial propagation to the anterior temporal and frontal areas (Panel A and B). Rapid propagation to the posterior temporal structures and the occipital lobe was then seen (Panel C). An ictal amaurosis occurred at the same time. Ictal discharges remained over the occipital lobe for one minute (Panel D).

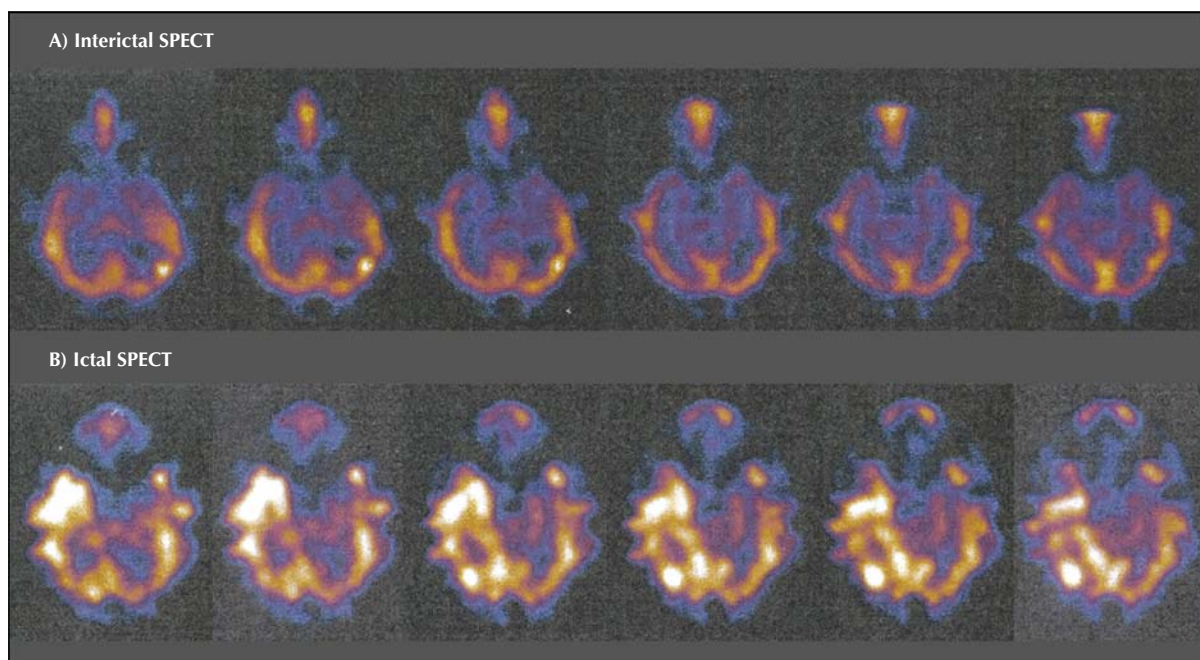


Figure 2. Patient 1 was injected for an ictal SPECT 10 s prior to the ictal propagation to the occipital lobe. In comparison to the interictal SPECT (A), the ictal SPECT (B) showed a tracer enhancement in the temporal as well as the occipital cortex.

eral occipital lobe was seen. Epileptic discharges were maximum at O2 and T6, remaining in the occipital region for six minutes before the seizure ended. During this period, she could identify objects presented by the nurse, but was confused. She was not tested for visual field loss, but did not report any visual phenomena (*figure 3*).

Discussion

Ictal propagation from occipital to temporal lobe structures is well known. Temporal and occipital lobe seizures may therefore be difficult to distinguish. Occipital lobe epilepsies often present with temporal lobe features as an early manifestation (Palmini *et al.* 1993). However, propagation from temporal to occipital regions has not been described and seems to occur rarely.

Both patients in this study had seizures originating in temporal lobe structures, as suggested by depth electrode study. One has to bear in mind that SEEG investigations are always spatially limited and therefore seizures might be originating from more than one area or the electrodes might record ictal propagation instead of the actual seizure-onset. This possibility cannot be excluded in our

patients as electrodes covered the occipital-temporal junction only in the first patient and there was not complete coverage of the occipital lobe in either patient. However, in both patients, habitual seizures could be provoked during a stimulation study and both patients showed constant, typical temporal lobe symptoms during their seizure, which supports the finding of a temporal lobe onset.

The first patient had attacks with altered consciousness, automatisms and an aura of anxiety, all features of TLE. On infrequent occasions, he described seeing flashes as an aura and postictal headaches, features regarded as an indication of a possible occipital lobe onset (Panayiotopoulos 1999). In one seizure with propagation from temporal to occipital region on surface EEG, he experienced complete ictal amaurosis for a minute. In occipital lobe seizures, visual symptoms are described as auras as well as ictal and postictal phenomena (Bauer *et al.* 1991). The aura of flashes and the ictal amaurosis therefore would have been most likely interpreted as primary occipital lobe involvement.

Patient 2 also presented clinical signs of temporal seizures, a bad smell and simple auditory hallucinations followed

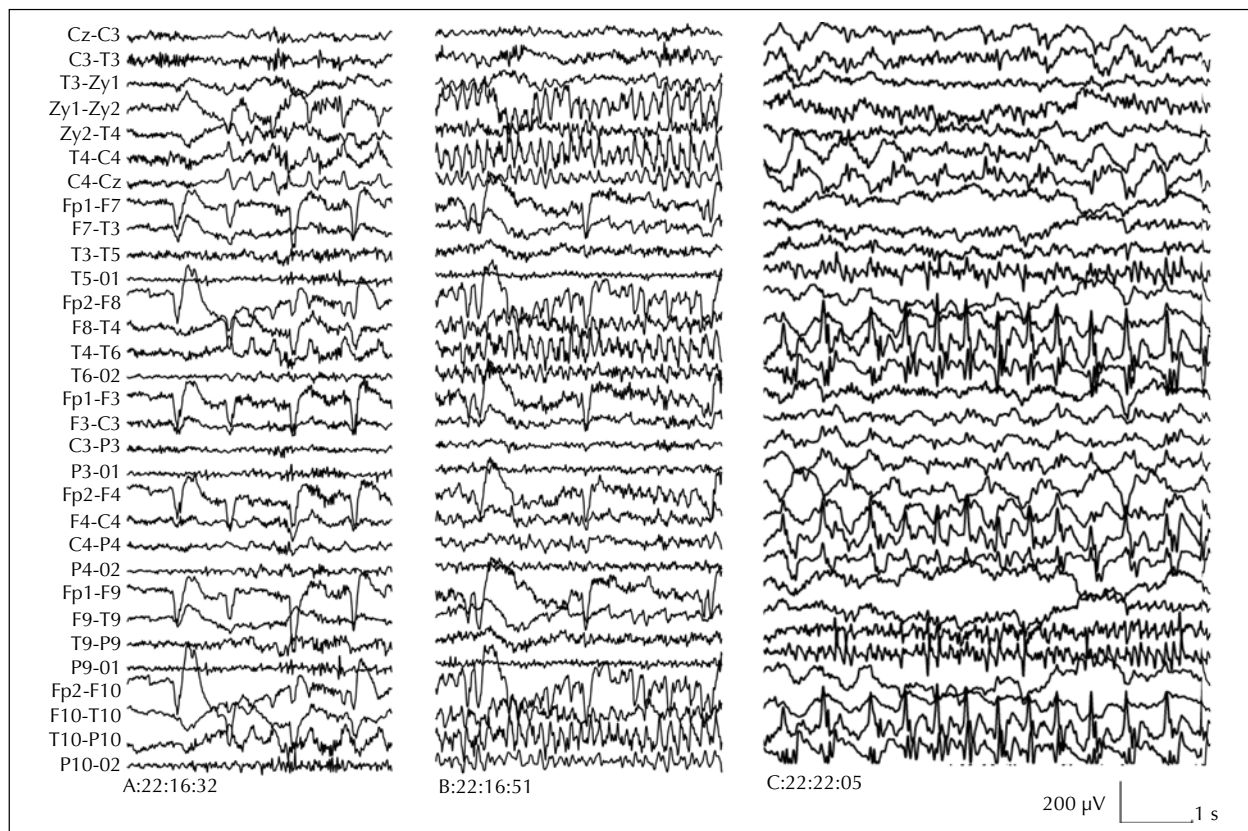


Figure 3. Telemetry study of patient 2. Electrographic onset of the seizure and ictal involvement of the right temporal structures are presented in panels A and B. This was followed by propagation of the ictal discharge to the posterior temporal and occipital lobe. Ictal activity continued over the occipital region for six minutes (Panel C).

by altered consciousness. The clinical features were stereotyped, and in many cases the EEG showed fast secondary generalization. Her depth electrode study showed mesial temporal onset. Symptomatic TLE was confirmed and a second surgery, including temporal neocortical areas, resulted in a seizure-free outcome.

In neither patient, did selective amygdalo-hippocampectomy result in a seizure-free outcome. It is well known that propagation of ictal discharges has predictive value for the surgical outcome in temporal epilepsy (Schulz *et al.* 2000). Boesebeck and co-workers additionally showed that a non-lateralizing seizure pattern and particularly non-lateralizing auras, result in poor postsurgical outcome in patients with epilepsy of temporal-occipital origin (Boesebeck *et al.* 2002). The patients presented had no clearly lateralizing auras, no seizure or propagation patterns during their seizures. Therefore, both patients already had some indications mitigating against a good postsurgical outcome.

Both patients demonstrate that, on rare occasions, ictal propagation from temporal to occipital regions might occur in patients with TLE. This is not necessarily correlated with clinical symptoms. In patient one, the epileptic discharge started in the posterior neocortical areas, and then spread to the temporal pole before going backwards again. This pattern is reversed from the normal direction of propagation of occipital attacks. It is likely that temporal-occipital propagation uses the same underlying anatomical structures. The inferior longitudinal fasciculus is believed to be a fast, direct connecting pathway. Other connecting pathways, such as fibres of the occipito-temporal projecting system with a longer latency, could also be involved in ictal propagation (Olivier *et al.* 1982, Catani *et al.* 2003). Although propagation has only been reported from the occipital to the temporal lobe, it seems to occur, on occasion, in the opposite direction. This may be facilitated by an involvement of neocortical structures during the seizures, as seen in both of our patients. This rare ictal propagation pattern must be considered in patients who have seizures with both temporal and occipital features. Propagation of ictal discharges on surface EEG additionally has predictive value for the surgical outcome in TLE and should be evaluated when assessing the EEG. □

References

- Bauer J, Schüler P, Feistel H, *et al.* Blindness as an ictal phenomenon: investigations with EEG and SPECT in two patients suffering from epilepsy. *J Neurol* 1991; 238: 44-6.
- Boesebeck F, Schulz R, May T, *et al.* Lateralizing semiology predicts the seizure outcome after epilepsy surgery in the posterior cortex. *Brain* 2002; 125: 2320-32.
- Catani M, Jones DK, Donato R, *et al.* Occipito-temporal connections in the human brain. *Brain* 2003; 126: 2093-107.
- Collins RC, Caston TV. Functional anatomy of occipital lobe seizures: an experimental study in rats. *Neurology* 1979; 29: 705-16.
- Olivier A, Gloor P, Andermann F, Ives J. Occipitotemporal Epilepsy Studied with Stereotypical Implanted Depth Electrodes and Successfully Treated by Temporal Resection. *Ann Neurol* 1982; 11: 428-32.
- Palmini A, Andermann F, Dubeau F, *et al.* Occipitotemporal Epilepsies: Evaluation of Selected Patients Requiring Depth Electrodes Studies and Rationale for Surgical Approaches. *Epilepsia* 1993; 34: 84-96.
- Panayiotopoulos CP. Visual phenomena and headache in occipital epilepsy: a review, a systematic study and differentiation from migraine. *Epileptic Disord* 1999; 1: 205-16.
- Salanova V, Andermann F, Olivier A, *et al.* Occipital lobe epilepsy: electroclinical manifestation, electrocorticography, cortical stimulation and outcome in 42 patients treated between 1930 and 1991. *Brain* 1992; 115: 1655-80.
- Schulz R, Lueders HO, Hoppe M, *et al.* Interictal EEG and Ictal Scalp EEG Propagation Are highly Predictive of Surgical Outcome in Mesial Temporal Lobe Epilepsy. *Epilepsia* 2000; 41: 564-70.
- Williamson PD, Spencer DD, Spencer SS, *et al.* Complex partial seizures with occipital lobe onset. *Epilepsia* 1981; 22: 247-8.
- Williamson PD, Engel Jr. J. Complex Partial Seizures. In: Engel Jr, Pedley TA, eds. *Epilepsy: A Comprehensive Textbook. Vol. 1.* Philadelphia: Lippincott-Raven Publishers, 1998: 557-66.
- Williamson PD, Thadani VM, Dracey TM, *et al.* Occipital lobe epilepsy: Clinical characteristics, seizure spread patterns, and results of surgery. *Ann Neurol* 1992; 31: 3-13.