

Sensitivity of scalp 10-20 EEG and magnetoencephalography

Yosuke Kakisaka^{1,2}, Rafeed Alkawadri¹, Zhong I Wang¹,
Rei Enatsu¹, John C Mosher¹, Anne-Sophie Dubarry¹,
Andreas V Alexopoulos¹, Richard C Burgess¹

¹ Epilepsy Center, Neurological Institute, Cleveland Clinic, Cleveland OH, USA

² Department of Pediatrics, Tohoku University School of Medicine, Sendai, Japan

Received June 26, 2012; Accepted December 7, 2012

ABSTRACT – Although previous studies have investigated the sensitivity of electroencephalography (EEG) and magnetoencephalography (MEG) to detect spikes by comparing simultaneous recordings, there are no published reports that focus on the relationship between spike dipole orientation or sensitivity of scalp EEG/MEG and the “gold standard” of intracranial recording (stereotactic EEG). We evaluated two patients with focal epilepsy; one with lateral temporal focus and the other with insular focus. Two MEG recordings were performed for both patients, each recorded simultaneously with initially scalp EEG, based on international 10-20 electrode placement with additional electrodes for anterior temporal regions, and subsequently stereotactic EEG. Localisation of MEG spike dipoles from both studies was concordant and all MEG spikes were detected by stereotactic EEG. For the patient with lateral temporal epilepsy, spike sensitivity of MEG and scalp EEG (relative to stereotactic EEG) was 55 and 0%, respectively. Of note, in this case, MEG spike dipoles were oriented tangentially to scalp surface in a tight cluster; the angle of the spike dipole to the vertical line was 3.6 degrees. For the patient with insular epilepsy, spike sensitivity of MEG and scalp EEG (relative to stereotactic EEG) was 83 and 44%, respectively; the angle of the spike dipole to the vertical line was 45.3 degrees. For the patient with lateral temporal epilepsy, tangential spikes from the lateral temporal cortex were difficult to detect based on scalp 10-20 EEG and for the patient with insular epilepsy, it was possible to evaluate operculum insular sources using MEG. We believe that these findings may be important for the interpretation of clinical EEG and MEG.

Key words: electroencephalography (EEG), magnetoencephalography, sensitivity, stereotactic EEG (SEEG)

Magnetoencephalography (MEG) is a non-invasive technique, which has been known to demonstrate better spatial resolution than electroencephalography (EEG). MEG is usually evaluated with simultaneously-recorded scalp EEG, because both modalities play a complementary role in spike evaluation (Ebersole and Ebersole, 2010). Recently,

reports have demonstrated that it is possible to record and analyse simultaneous intracranial EEG and MEG to determine the presence of spikes (Mikuni *et al.*, 1997; Oishi *et al.*, 2002; Santiuste *et al.*, 2008; Wang *et al.*, 2012).

Previous studies have investigated spike detectability of scalp EEG and MEG by examining simultaneous

Correspondence:

Yosuke Kakisaka
Epilepsy Center,
Neurological Institute,
The Cleveland Clinic Foundation,
9500 Euclid Avenue,
Cleveland, OH 44195, USA
<kakisuke@mui.biglobe.ne.jp>

doi:10.1684/epd.2013.0554

recordings (Iwasaki *et al.*, 2005). However, no studies have focused on the relationship between spike dipole orientation or sensitivity of scalp EEG/MEG and the “gold standard” of intracranial recording (stereotactic EEG [SEEG]). Based on our retrospective review of 300 patients in the MEG laboratory in our institution, we identified two patients with focal epilepsy; one with lateral temporal focus and the other with insular focus. Both patients received two MEG recordings, initially with simultaneous scalp EEG using the international 10-20 electrode placement with additional electrodes for anterior temporal regions (10-20 EEG), and subsequently with simultaneous SEEG.

Patients

Case 1

A 20-year-old, right-handed male began to have seizures at the age of eight. His perinatal and development history was not remarkable. With regards to family history, his father had staring spells during childhood which remitted after two years of medication. The patient’s typical seizures started with an auditory aura followed by either a somatosensory seizure of right leg numbness or dialeptic seizure. He sometimes had secondary generalised tonic-clonic seizures. Seizures occurred 4-9 times/month despite multiple antiepileptic medications. Multiple scalp EEG monitoring, performed at the age of 11, showed interictal spikes in the left centro-temporal region, with left fronto-temporal ictal onset. Since invasive evaluation, involving subdural electrocorticography (ECoG) to cover the left fronto-temporo-parietal region, showed multifocal seizure onset around the left perisylvian fissure, focal resective surgery was denied. A vagus nerve stimulator was implanted at the age of 12. At the age of 20, he was admitted for re-evaluation. Recent EEG showed the left fronto-centro-temporo-parietal region to be the region of ictal onset, however, no clear interictal spikes were observed. FDG-PET showed subtle hypometabolism involving the right frontal operculum and postictal SPECT showed hyperperfusion involving the right periopercular region. MRI showed Chiari type 1 malformation but was otherwise normal.

Case 2

A 13-year-old, right-handed male began to have seizures at the age of 7. His perinatal and early development history, as well as family history, was not remarkable. His typical seizures started with a somatosensory aura of the left arm, followed by a bilateral asymmetric tonic seizure. He never had sec-

ondary generalised tonic-clonic seizures. Seizures tended to occur in clusters, with a frequency of one to two per month, even after having tried multiple antiepileptic medications. Previous multiple scalp-EEG monitoring showed spikes in the right fronto-temporal region, interictally, and seizures were confirmed to emerge from the same region. Ictal SPECT showed hyperperfusion in the right anterior/superior insular region and left dorsolateral posterior frontal region. MRI showed stable volume loss in the cerebellar hemispheres but was otherwise normal.

Methods

Simultaneous recordings of MEG and scalp EEG, as a first study, and MEG and SEEG, as a second study, were performed in a magnetically shielded room for each patient, with a duration of about 40 minutes. The period between the first (scalp EEG-MEG) and second study (SEEG-MEG) was approximately 1.5 month for Case 1, and 3.5 months for Case 2. For MEG data collection, a whole-head MEG system of 204 planar gradiometers (VectorView; Neuromag, Helsinki, Finland) was used. For scalp EEG, international 10-20 electrode placement with additional electrodes for anterior temporal regions (total number of electrodes was 21) was applied. For SEEG recording, the SEEG electrodes used consisted of 8-12 cylindrical, 2.5-mm-long platinum contacts with a diameter of 1.1 mm, separated by 5 mm (Integra EpilepsyTM, Integra, NJ, USA). In this study, we focused on four contacts inserted in the left superior temporal gyrus in Case 1, and another 4 contacts inserted in the right periopercular-insular region in Case 2 (*figure 1*). Electrodes placed in the mastoid of the right side (Case 1) and the left side (Case 2) were used as reference. In this study, spike involvement at a SEEG contact was judged to be positive when a spike waveform could be visually identified. For all SEEG spikes, spikes were observed at all four SEEG contacts in both cases. The shortest distance from brain surface to each contact 1 and 4 was 17 mm and 0 mm for Case 1 and 17.3 mm and 19.0 mm for Case 2, respectively. In all MEG recordings, we applied continuous movement compensation algorithm during recording. Before analysis, we performed temporally-extended signal space separation algorithm (tSSS) to each data set with a commercial software package, “MaxFilter”, to eliminate magnetic noise. We defined a MEG spike as a spike that stood out and was distinguishable from background activity (with an amplitude twice, or larger than, that of background activity). For an estimation of spike source and orientation, single dipole modelling was applied for MEG signals using a spherical head model. We also measured the angle of the spike dipole to the vertical line (*figure 2*).

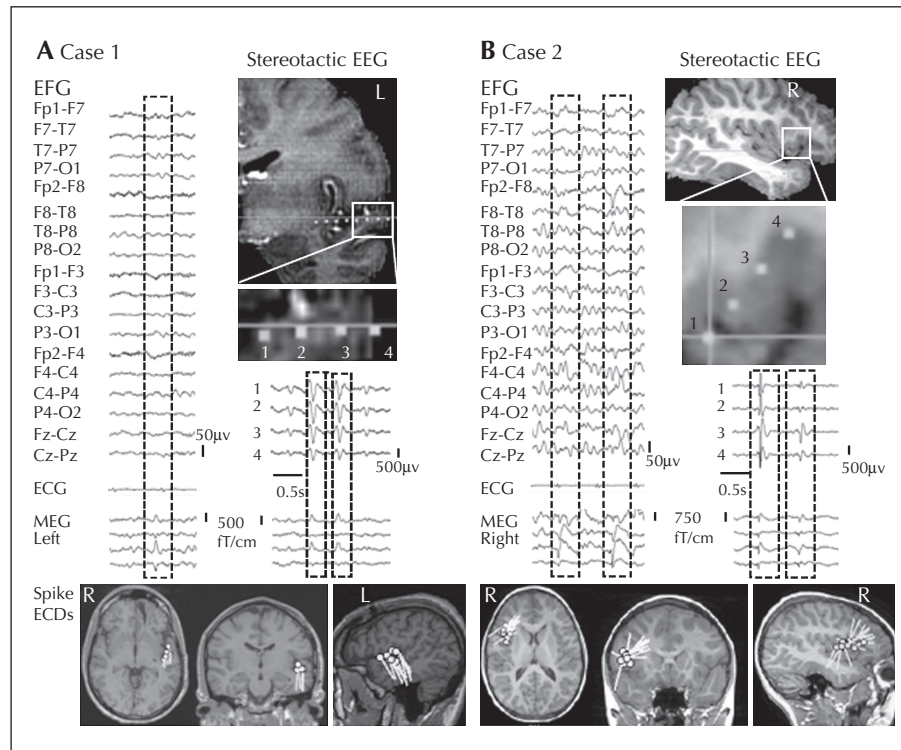


Figure 1. Scalp EEG/MEG and SEEG/MEG of Case 1 (a) and Case 2 (b).

Upper panel: spikes detected by scalp EEG and MEG (left), and SEEG and MEG (right); electrode location is depicted on the right. Lower column: axial, coronal, and sagittal MRI; the equivalent current dipole reflects location (circle) as well as orientation (bar). In both cases, MEG spike dipoles from both studies were anatomically concordant.

Results

The results of scalp EEG and SEEG with MEG are presented in *figure 1* and the details are summarised in *table 1*. In Case 1, SEEG showed spikes at contacts at the left superior temporal gyrus. While all MEG spikes were observed by SEEG, 53% of all SEEG spikes were observed by MEG (sensitivity of MEG=53%, using SEEG as the gold standard). MEG spike dipoles were estimated in the left superior temporal gyrus. In the scalp EEG-MEG study, MEG showed spikes with dipoles estimated in the same region; the left superior temporal gyrus, although scalp EEG failed to show any clear correlating spikes (sensitivity of scalp EEG=0%). Of note, MEG spike dipoles were tightly oriented tangentially to the scalp surface and the angle of the spike dipole to the vertical line was 3.6 degrees.

In Case 2, SEEG showed spikes at contacts in the right insular to peri-insular region. While all MEG spikes were observed by SEEG, 83% of all SEEG spikes were observed by MEG (sensitivity of MEG=83%). MEG spike dipoles were estimated in the right insular to peri-insular region. In the scalp EEG-MEG study, all scalp EEG spikes were observed using MEG and MEG spike dipoles were estimated in the same area; the right

insular to peri-insular region. Scalp EEG showed only 53% of all MEG spikes (corrected sensitivity of scalp EEG=44%). The angle of the spike dipole to the vertical line was 45.3 degrees.

Discussion

The interpretation of MEG with either 10-20 EEG or SEEG in the two cases presented here clearly indicates that: 1) tangential spikes from the lateral temporal cortex may be difficult to detect by 10-20 EEG; and 2) operculum insular sources may be evaluated using MEG.

All MEG spike dipoles from the lateral temporal region (Case 1) demonstrated a characteristic tight clustering with a significant tangential orientation to the scalp; the angle of the spike dipole to the vertical line was 3.6 degrees, without clear EEG spikes. In theory, EEG is sensitive to activities from both the fissure and gyrus, whereas MEG is exclusively sensitive to activities from the fissure cortex (Ebersole and Ebersole, 2010). The data appear to provide curious clinical evidence that spikes tangential to the scalp might be less apparent or undetected by EEG, as shown in our recent study

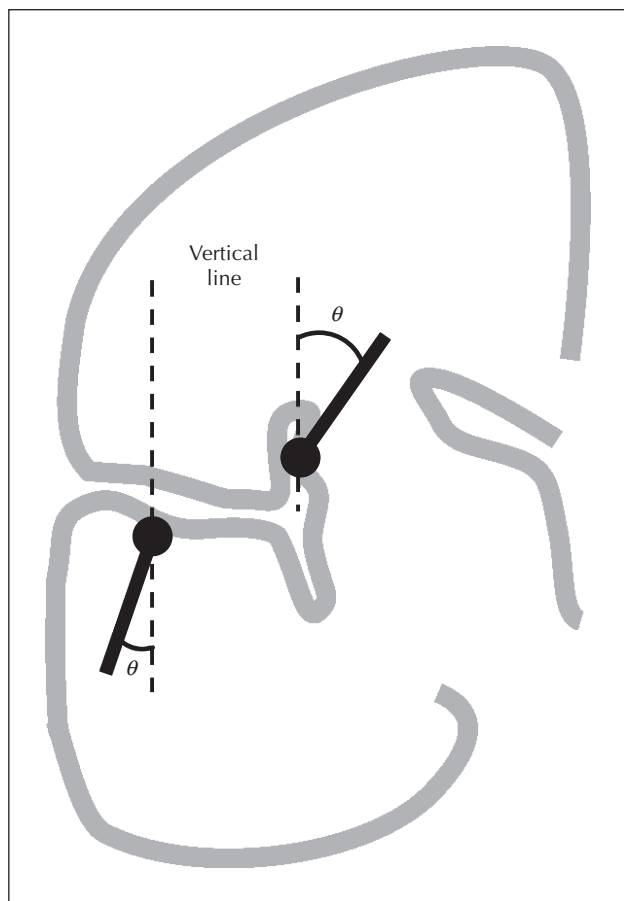


Figure 2. Coronal schema showing angle between the spike dipole and vertical line.

(Kakisaka *et al.*, 2012). For insular spikes (Case 2), it is believed that spike detection by MEG would be difficult because of the geometry of this deeply set region

(Goldenholz *et al.*, 2009). Recently, Park *et al.* reported successful spike detection with MEG in two cases with lesional insular epilepsy (Park *et al.*, 2012). They speculated that geometrical change due to lesion in the insular may relate to their successful MEG recording. However, no clear insular lesion existed in our case. The result of Case 2 not only supports this report in terms of the ability to detect insular spikes using MEG, but also showed that even in the absence of lesion, it was still possible using MEG to detect insular spikes more effectively than previously thought. In contrast to Case 1, the spike dipole of Case 2 had both a radial and tangential component (45.6 degrees). We believe that this difference of spike orientation, or presence of radial component in Case 2, may be related to the appearance of epileptic spikes on scalp EEG.

In order to address the comparative sensitivity between MEG and intracranial recording using ECoG, Agirre-Arrizubieta *et al.* (2009) reported that all MEG spikes were observed with ECoG and 56% of all interictal ECoG spikes had a MEG counterpart. They found that spike detectability was variable according to anatomical region; detectability was greatest in the orbitofrontal and interhemispheric regions (>90%), followed by the superior frontal, central, and lateral temporal regions (<75%), with mesial temporal spikes being the most difficult to detect (<25%). Santiuste *et al.* (2008) compared spike detectability between SEEG and MEG in one patient with occipital epilepsy and three patients with mesial temporal epilepsy. They reported that 95% of all interictal SEEG spikes had a MEG counterpart in the occipital case, while only 25 to 60% of all SEEG spikes had a MEG correlate in the mesial temporal cases (Santiuste *et al.*, 2008). The sensitivity of MEG to detect spikes in Case 1 was less than that reported by Agirre-Arrizubieta’s group (55

Table 1. Key findings of MEG with simultaneous EEG or SEEG.

	Age	Age at seizure onset	Initial seizure symptom	Spike detectability* SEEG:MEG	Spike detectability* MEG:EEG	Concordance of MEG dipole location between the two studies?	Sensitivity of spike detection MEG vs EEG (relative to SEEG)	Angle of the spike dipole to the vertical line (see figure 1)
Case 1	20	8	Auditory aura, or diaplectic	100%:55%	100%:0% (55%:0%)**	Yes (L superior temporal gyrus)	55%:0%	3.6
Case 2	13	7	L arm somato-sensory	100%:83%	100%:53% (83%:44%)**	Yes (R insular to peri-insular)	83%:44%	45.3

*All MEG spikes were observed by SEEG and all EEG spikes were observed by MEG.

**Values were calculated after considering spike detectability of SEEG vs MEG.

vs 73%, respectively). In addition to the difference of electrode type (ECoG vs SEEG), we assume that the variable degree of spiking between cases may explain the difference in MEG sensitivity. None of the previous simultaneous ECoG and MEG studies examined sensitivity of MEG to insular spikes. To clarify the capability or limitation of MEG for insular spikes, additional data would be required from a larger study.

There are, however, several limitations of this study. Firstly, the limited period of recording may not have been representative of the spike profile of the patient. In our two cases, all spikes detected by scalp EEG were observed by MEG, however, spikes unique to EEG may exist (Iwasaki *et al.*, 2005). Secondly, the small sample size of our study may have restricted our interpretation of spike sensitivity among the three modalities. Accumulation of other cases will be needed to overcome these limitations and strengthen the preliminary evidence gained here. □

Acknowledgments and disclosures.

This work was supported, in part, by the National Institutes of Health under grants R01-EB009048 and R01-NS074980, and by the Epilepsy Center of the Cleveland Clinic Neurological Institute. None of the authors has any conflict of interest to disclose.

References

Agirre-Arrizubieta Z, Huiskamp GJ, Ferrier CH, *et al.* Intercal magnetoecephalography and the irritative zone in the electrocorticogram. *Brain* 2009; 132: 3060-71.

Ebersole JS, Ebersole SM. Combining MEG and EEG source modeling in epilepsy evaluations. *J Clin Neurophysiol* 2010; 27: 360-71.

Goldenholz DM, Ahlfors SP, Hämäläinen MS, *et al.* Mapping the signal-to-noise-ratios of cortical sources in magnetoencephalography and electroencephalography. *Hum Brain Mapp* 2009; 30: 1077-86.

Iwasaki M, Pestana E, Burgess RC, *et al.* Detection of epileptiform activity by human interpreters: blinded comparison between electroencephalography and magnetoencephalography. *Epilepsia* 2005; 46: 59-68.

Kakisaka Y, Iwasaki M, Alexopoulos AV, *et al.* Magnetoencephalography in fronto-parietal opercular epilepsy. *Epilepsy Res* 2012; 102: 71-7.

Mikuni N, Nagamine T, Ikeda A, *et al.* Simultaneous recording of epileptiform discharges by MEG and subdural electrodes in temporal lobe epilepsy. *Neuroimage* 1997; 5: 298-306.

Oishi M, Otsubo H, Kameyama S, *et al.* Epileptic spikes: magnetoencephalography versus simultaneous electrocorticography. *Epilepsia* 2002; 43: 1390-5.

Park HM, Nakasato N, Tominaga T. Localization of abnormal discharges causing insular epilepsy by magnetoencephalography. *Tohoku J Exp Med* 2012; 226: 207-11.

Santiuste M, Nowak R, Russi A, *et al.* Simultaneous magnetoencephalography and intracranial EEG registration: technical and clinical aspects. *J Clin Neurophysiol* 2008; 25: 331-9.

Wang ZI, Jones SE, Ristic AJ, *et al.* Voxel-based morphometric MRI post-processing in MRI-negative focal cortical dysplasia followed by simultaneously recorded MEG and stereo-EEG. *Epilepsy Res* 2012; 100: 188-93.