

The ketogenic diet in two paediatric patients with refractory myoclonic status epilepticus

Roberto Horacio Caraballo, Gabriela Reyes Valenzuela, Marisa Armeno, Sebastian Fortini, Graciela Mestre, Araceli Cresta

Servicio de Neurología, Hospital de Pediatría "Prof Dr Juan P Garrahan", Buenos Aires, Argentina

Received July 16, 2015; Accepted October 11, 2015

ABSTRACT – *Aim.* We describe two patients with refractory myoclonic status epilepticus treated with the ketogenic diet.

Methods. Between May 1, 2014 and January 1, 2015, two patients who met the diagnostic criteria for refractory myoclonic status epilepticus, seen at our department, were placed on the ketogenic diet and followed for a minimum of six months.

Results. One patient with myoclonic epilepsy of unknown aetiology had a 75-90% seizure reduction, and the other with progressive encephalopathy associated with myoclonic epilepsy had a 50% seizure reduction. Both patients retained good tolerability for the diet. At the last control, one patient had isolated myoclonias and EEG showed occasional generalized spike-and-polyspike waves; the patient is now successfully attending kindergarten. The quality of life of the second patient improved significantly. In both cases, the number of antiepileptic drugs was reduced.

Conclusion. The ketogenic diet is an effective and well-tolerated treatment option for patients with refractory myoclonic status epilepticus and should be considered earlier in the course of treatment.

Key words: myoclonias, status epilepticus, ketogenic diet, super-refractory, seizures

The ketogenic diet (KD) is considered a safe and effective optional therapy not only for children but also for adults with intractable epilepsy (Kossoff *et al.*, 2008; Caraballo *et al.*, 2011; Caraballo and Vining, 2013).

It has been suggested that the KD may be beneficial for seizure control in specific epileptic syndromes (Kossoff *et al.*, 2008; Caraballo

and Vining, 2013). Over the last years, there has been a remarkable appearance of the concept of using dietary therapy for emergency management of pharmacoresistant seizures and status epilepticus (SE) (Cervenka *et al.*, 2011; Nam *et al.*, 2011; Kossoff and Nabhout, 2013; Strzelczyk *et al.*, 2013; Caraballo *et al.*, 2014; O'Connor *et al.*, 2014). In cases when the diet was reported to

Correspondence:

Roberto H Caraballo
Servicio de Neurología,
Hospital de Pediatría "Prof Dr Juan P
Garrahan",
Combate de los Pozos 1881. C.P. 1245,
Buenos Aires, Argentina
<rhcaraballo@arnet.com.ar>

doi:10.1684/epd.2015.0781

be successful, it worked within 7-10 days (Kossoff and Nabbout, 2013).

The term “myoclonic status epilepticus” is used for a wide range of electroclinical presentations with different prognostic and treatment implications. Myoclonic status epilepticus has been described in generalized epilepsy syndromes, neurodegenerative disease, infectious or inflammatory neurological disease, toxic-metabolic states, and following anoxic brain injury. The presentation of and treatment approach to myoclonic status epilepticus depends largely on the underlying aetiology (Shorvon, 2006).

In this study, we evaluated the efficacy and tolerability of the KD in two patients who met the diagnostic criteria for pharmacoresistant myoclonic SE.

Material and Methods

Case 1

The patient was a 23-month-old boy, born after a full-term pregnancy with a normal weight for gestational age. His perinatal history was unremarkable. Both parents had a history of febrile seizures.

Developmental milestones and neurological examination were according to age, up to 1 year of life. At that time, the baby had febrile seizures, several months later followed by palpebral twitching and oral automatisms. Subsequently, he developed generalized myoclonic seizures and erratic jerks associated with cognitive and motor decline. The patient did not respond to the common antiepileptic drugs (AEDs) and was eventually admitted to our centre because of a myoclonic status epilepticus.

The first interictal EEG recording, performed at age 1 year and 2 months, showed brief generalized spike-and-wave discharges during sleep.

During follow-up, generalized myoclonias increased in frequency.

The control sleep EEG showed spike-and-wave paroxysms with moderate- to high-frequency discharges, predominantly in frontocentral regions. During sleep, generalized isolated myoclonias were recorded associated with generalized spikes and waves.

Neurometabolic investigations, including blood, urine, and CSF analysis, as well as karyotyping, were normal. Brain MRI was also normal. Testing for *SNC1A* gene mutations was negative. Based on these findings and the electroclinical features, the patient was considered to have myoclonic epilepsy of unknown aetiology.

At 2 years and 5 months of age, the patient was admitted with a repetitive myoclonic SE characterized by erratic and generalized jerks. The patient lost independent gait, however, during the period without myoclonic status epilepticus, his motor development improved significantly. The ictal video-EEG showed continuous diffuse and asymmetric spike-and-polyspike waves associated with massive myoclonias (figure 1).

The patient was refractory to different AEDs, such as midazolam, levetiracetam, ethosuximide, clobazam, topiramate, as well as corticosteroids which were tried for two weeks. Therefore, at 2 years and 6 months of age, the KD was started at a 4:1 ratio and glucose administration was discontinued, including that by intravenous infusion. After a 24-hour fast,

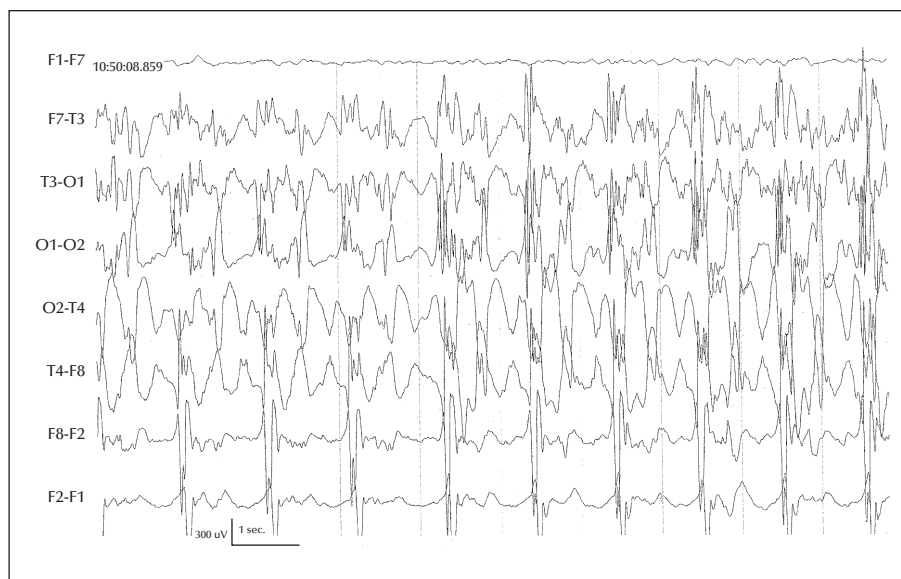


Figure 1. The EEG recording shows continuous and diffuse spikes and polyspikes and waves associated with bilateral myoclonic jerks.

the patient was administered a commercial preparation (KetoCal [KetoCal, SHS]) via a nasogastric tube. Urine ketosis was monitored daily with Labstix. The urine ketone strip measured 4 (++++), throughout the dietary treatment. No attempt was made to measure plasma ketone bodies. During the first week on the KD, the patient slowly improved, achieving a 75-90% seizure reduction, with less EEG abnormalities. Since then, his neuropsychological performance, but mainly his motor development, has significantly improved. The child has recovered independent gait. After one year on the diet, the patient has isolated myoclonias. He is successfully attending kindergarten. The last control EEG showed occasional generalized spike-and-polyspike waves. The number of AEDs has been reduced to one (valproic acid). The diet was switched to the classic oral diet at 3 years of age. Biopsy results and study of genetic markers are pending.

Case 2

The patient was a 17-month-old boy. He was born after an uneventful, full-term pregnancy with a normal weight for gestational age. His family history was unremarkable.

On the first day of life, he started with recurrent refractory status epilepticus requiring mechanical ventilation. He received valproic acid, vigabatrin, and levetiracetam, with poor response.

At 1 year of age, the patient was referred to our centre due to progressive encephalopathy and myoclonic epilepsy. On neurological examination, slow growth of head circumference, generalized hypotonia, and pyramidal signs were observed. Cognitive development was impaired. Fundoscopy was normal.

EEG recordings showed multifocal spikes and diffuse fast spike-and-polyspike waves that increased during sleep. Intermittent photic stimulation was negative. The background activity slowly became impaired.

At that time, brain MRI showed bilateral hypointensity in the white matter on T1-weighted and hyperintensity on T2-weighted images with mild ventricular asymmetry, mega cisterna magna extending to both cerebellar hemispheres, and mild cerebellar hypoplasia.

Neurometabolic investigations, including blood, urine, and CSF analysis, as well as karyotyping, were normal.

The myoclonic episodes were refractory to classic and new oral AEDs. The video-EEG showed continuous diffuse spike-and-wave paroxysms associated with subintractant multifocal and erratic myoclonias (*figure 2*). The boy was admitted to the ICU because of refractory myoclonias, and intravenous levetiracetam, valproic acid, benzodiazepines, and corticosteroids were tried without response over three weeks before starting the KD. The KD was begun at a 4:1 ratio and glucose administration was discontinued, including that by intravenous infusion. After 24 hours of fasting, the child was given a commercial preparation (KetoCal

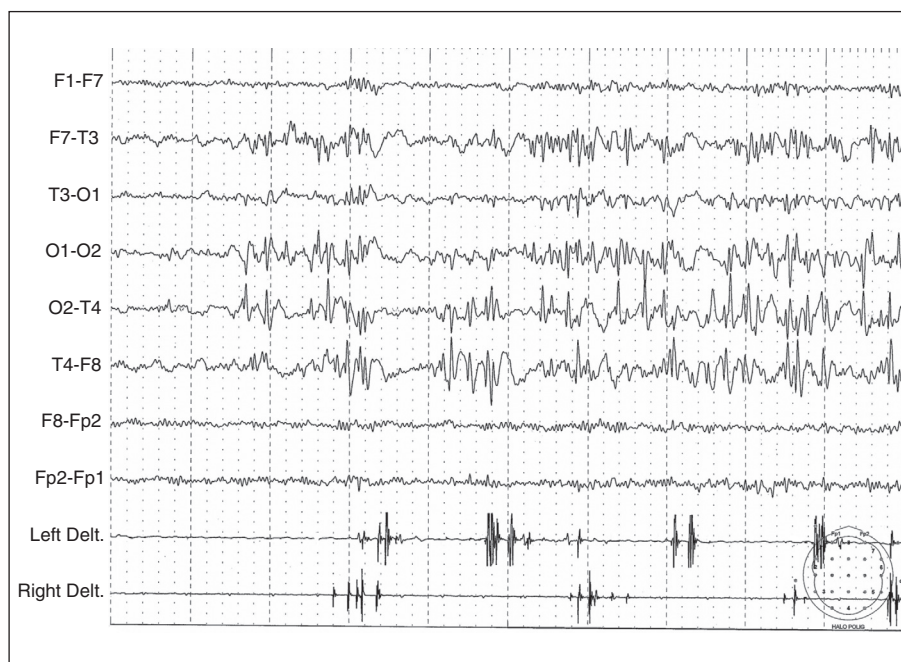

Figure 2. The polygraphic-EEG recording shows continuous, asymmetric and asynchronous bilateral spikes, and spikes and waves, associated with repetitive focal and, less frequently, bilateral myoclonias.

[KetoCal, SHS]) via a nasogastric tube. Urine ketosis was monitored daily with Labstix. The patient maintained a level of urine ketones of 3 (+++) or 4 (++++), throughout the treatment. Plasma ketone bodies were not measured. One week after KD initiation, the patient slowly improved achieving a 50% seizure reduction. He was discharged from the ICU and two weeks later from the hospital. He had become more alert and his eye contact improved. After a six-month follow-up, in spite of the progressive encephalopathy, his quality of life improved and the AEDs were reduced to levetiracetam and topiramate. The patient continues to receive the same formula orally.

Biopsy results and study of genetic markers are pending.

Discussion

Our experience with two children with refractory myoclonic SE demonstrated a good response to the KD in terms of reduction of seizure frequency and tolerability.

The KD has been recommended for patients with refractory SE, not only adults but children as well, regardless of the aetiology (Kossoff and Nabbout, 2013; Caraballo et al., 2014). To our knowledge, no patients with myoclonic SE have previously been reported to be treated with the KD. Our patients had refractory SE and the KD was introduced via a nasogastric tube, achieving seizure control within 3-7 days for both.

Interestingly, patients with non-convulsive SE are also reported to respond well to the KD (Kumada et al., 2010), as are patients with epileptic encephalopathy with electrical status epilepticus during slow sleep (Reyes et al., 2015). These findings support the benefit of the KD in the management of patients with other types of SE.

The use of the KD for the treatment of SE is rapidly increasing throughout the world (Kumada et al., 2010; Kossoff and Nabbout, 2013; Reyes et al., 2015), however, to implement the diet in the management of these critical patients who often recover in the ICU, a ketogenic diet team, including a trained neurologist and dietitian, is necessary. Such a team will also allow the diet to be continued and install a longer-term treatment when it is successful (Caraballo and Vining, 2013; Kossoff and Nabbout, 2013). It is important to emphasize that ICU physicians and nurses should accompany the diet process accordingly, avoiding any AED changes over 10 days, to allow the diet to work well (Kossoff and Nabbout, 2013). Team decisions for each individual patient should be made based on electroclinical aspects (Caraballo et al., 2014).

It is well known that the KD may be especially beneficial for specific epileptic syndromes, however, the

diet may also be useful for specific SE (Kossoff et al., 2008; Caraballo and Vining, 2013). Therefore, when evaluating treatment with the traditional KD in patients with refractory SE, the epileptic syndrome, aetiology, and seizure types should be considered. This may provide a possibility to start the KD early in the management of patients with refractory SE, regardless of the type. Prospective studies of patients, both children and adults, with different types of refractory SE, should be conducted to further define the role of the diet in the management of these patients.

Conclusion

The KD is a promising therapy for myoclonic SE. It should be considered as an alternative option in the management of this type of SE, regardless of the aetiology. In patients with refractory myoclonic SE, the KD should be tried earlier in the course of the treatment. When good seizure control is achieved, the use of the diet may avoid cognitive deterioration and behavioural disturbances. □

Supplementary data.

Summary didactic slides are available on the www.epilepticdisorders.com website.

Disclosures.

None of the authors have any conflict of interest to disclose.

References

- Caraballo R, Vining E. Ketogenic diet. Epilepsy part II: Basic principles and diagnosis. In: Stefan H, Theodore W. *Handbook of Clinical Neurology*. Elsevier, 2013: 783-94.
- Caraballo R, Vaccarezza M, Cersósimo R, et al. Long-term follow-up of the ketogenic diet for refractory epilepsy: multicentre Argentinean experience in 216 pediatric patients. *Seizure* 2011; 20: 640-5.
- Caraballo R, Flesler S, Armeno M, et al. Ketogenic diet in pediatric patients with refractory focal status epilepticus. *Epilepsy Res* 2014; 108(10): 1912-6.
- Cervenka MC, Hartman AL, Venkatesan A, et al. The ketogenic diet for medically and surgically refractory status epilepticus in the neurocritical care unit. *Neurocrit Care* 2011; 15(3): 519-24.
- Kossoff E, Nabbout R. Use of dietary therapy for status epilepticus. *J Child Neurol* 2013; 28(8): 1049-51.
- Kossoff E, Zupec-Kania B, Amark P, et al. Optimal clinical management of children receiving the ketogenic diet: recommendation of the international ketogenic diet study group. *Epilepsia* 2008; 50(2): 304-17.

Kumada T, Miyajima T, Kimura N, *et al.* Modified Atkins diet for the treatment of nonconvulsive status epilepticus in children. *J Child Neurol* 2010; 25(4): 485-9.

Nam SH, Lee BL, Lee CG, *et al.* The role of ketogenic diet in the treatment of refractory status epilepticus. *Epilepsia* 2011; 52(11): e181-4.

O'Connor SE, Richardson C, Trescher WH, *et al.* The ketogenic diet for the treatment of pediatric status epilepticus. *Pediatr Neurol* 2014; 50(1): 101-3.

Reyes G, Flesler S, Armeno M, *et al.* Ketogenic diet in patients with epileptic encephalopathy with electrical status epilepticus during slow sleep. *Epilepsy Res* 2015; 113: 126-31.

Shorvon S. *Status epilepticus, its clinical features and treatments in children and adults.* Cambridge: Cambridge University Press, 2006.

Strzelczyk A, Reif PS, Bauer S, *et al.* Intravenous initiation and maintenance of ketogenic diet: proof of concept in super-refractory status epilepticus. *Seizure* 2013; 22(7): 581-3.

TEST YOURSELF



- (1) Does refractory myoclonic status epilepticus respond well to the ketogenic diet?
- (2) Is the oral formula of the ketogenic diet (Ketocal) a good option for this type of patient?
- (3) Should you consider the ketogenic diet earlier during the course of treatment for patients with refractory myoclonic status epilepticus, regardless of aetiology?

Note: Reading the manuscript provides an answer to all questions. Correct answers may be accessed on the website, www.epilepticdisorders.com, under the section "The EpiCentre".