

Atypical absences and recurrent absence status in an adult with Angelman syndrome due to the UBE3A mutation

Alberto J. Espay, Danielle M. Andrade, Richard A. Wennberg, Anthony E. Lang

Department of Neurology, The Toronto Western Hospital, University of Toronto, Toronto, Ontario, Canada

Received November 29, 2004; Accepted May 10, 2005

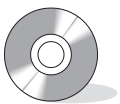ABSTRACT – Angelman syndrome is a neurogenetic disorder resulting in refractory epilepsy and profound psychomotor retardation in its most prevalent form, caused by deletion of maternal chromosome 15q11-13. We report the case of a 29-year-old, mentally retarded man with unusual electroencephalographic changes during periods of atypical absence status epilepticus, a previously unreported manifestation of the usually milder, drug-responsive epilepsy associated with Angelman syndrome due to the UBE3A mutation.

[Published with video sequences]

Key words: Angelman syndrome, UBE3A mutation, non-convulsive status epilepticus, absence status

Angelman syndrome (AS) was first described in three epileptic children with severe learning disability, ataxic and jerky movements, inability to speak, and easily provoked laughter. (Angelman 1965) The clinical picture now includes facial dysmorphism (with prominent microbrachycephaly and prognathism, made more apparent by a constant protrusion of the tongue), strabismus, flexed arms on walking, and “fascination with water” (Clayton-Smith and Laan 2003). The unusually happy disposition of these patients gave origin to the well-known clinical descriptor of “happy puppet syndrome”, which highlighted the common occurrence of inappropriate bursts of laughter and hand flapping

movements. In addition, myoclonic tremor and ataxic gait without overt cerebellar deficits, as well as multiple seizure types, are common at several stages of the disorder, especially when caused by the maternal 15q11-13 deletion, which is the most prevalent form of AS (or *class I*, with AS caused by alternate genetic mechanisms referred to as *class II, III, or IV* due to uniparental disomy, imprinting defect or UBE3A mutations, respectively) (Mann and Bartolomei 1999). We report a young adult whose diagnosis was delayed until frequent episodes of “eyelid fluttering” were diagnosed as manifestations of atypical absence seizures with unusual electroencephalographic features. This



Correspondence:

Dr. A. E. Lang, MD, FRCPC
Department of Medicine,
Division of Neurology,
The Toronto Western Hospital,
399 Bathurst Street, MP11-306,
Toronto, Ontario M5T 2S8
Canada
Tel.: (+ 00 416) 603 5112
Fax: (+ 00 416) 603 5004
<lang@uhnres.utoronto.ca>

observation led to the search for the additional genetic mechanism responsible for class IV AS (UBE3A mutation), a disorder originally missed by screening with standard diagnostic batteries.

Case report

This 29-year-old male with psychomotor retardation and microcephaly since birth was diagnosed with epilepsy at age 5 years with three seizure types described during childhood: generalized tonic-clonic, atonic (drop attacks), and absence. Episodes referred to by his parents as “eyelid fluttering” first appeared at the age of 19 years, while the patient was on clonazepam 1.5mg/day, clobazam 35mg/day and was being reintroduced to phenytoin, 350mg/day. These lasted from several seconds to 2 hours during which it was felt the patient was not his usual self behaviorally, although no definite loss of consciousness was described. A “tongue tremor” and brief generalized body jerks were occasionally present during the episodes, resolution of which was regularly followed by immediate resumption of prior activities (drawing on paper, watching television, or walking, for instance).

Valproic acid was subsequently initiated and clobazam was slowly discontinued, which reduced the “eye fluttering” episodes; however, as interpreted by his parents, frightening visual hallucinations ensued and the valproate was discontinued. Trials of different antipsychotic drugs (risperidone, olanzapine, and quetiapine) over the next 4 years were invariably associated with worsening of both frequency and severity of the “eyelid fluttering” episodes. The use of clonazepam with phenytoin and as-needed lorazepam continued as the preferred, albeit insufficient, strategy for minimiz-

ing these episodes. He had been free of any antipsychotics for almost 3 years prior to our evaluation.

Pregnancy and birth history were unremarkable. Subsequent development was delayed due to hypotonia during infancy and early childhood. He started to sit at approximately nine months, stood at 20 months, and walked at 27 months. His head circumference and height were always below the third percentile. He did not babble, and articulate speech never developed. He could never dress without help. Recurrent respiratory infections were common during the first 2 years of life.

Examination showed microcephaly, bushy eyebrows, wide nasal bridge, and small maxilla with a constantly open mouth and protruding and enlarged tongue. Speech was absent but occasional moaning with frequent, inappropriate and strained monotone laughter could be appreciated, sometimes associated with arm flapping stereotypies. These consisted of arm adduction and external rotation, elbow flexion in close midline proximity and wrist flapping (*figure 1* and accompanying video sequences). Low-amplitude resting and postural tremor of about 6 Hz was noted in the upper extremities, with an action-induced, fine, myoclonic component. Mild rigidity in all limbs and neck was elicited upon activation. The patellar muscle stretch reflexes were brisk but symmetric; other reflexes were normal. The plantar response was flexor, bilaterally. His gait showed short, often hesitant and shuffling steps with decreased arm swing. Impairment of postural reflexes with tendency to fall was evident on the “pull test”.

Brain MRI showed no abnormalities. Video-EEG demonstrated infrequent interictal generalized slow spike and

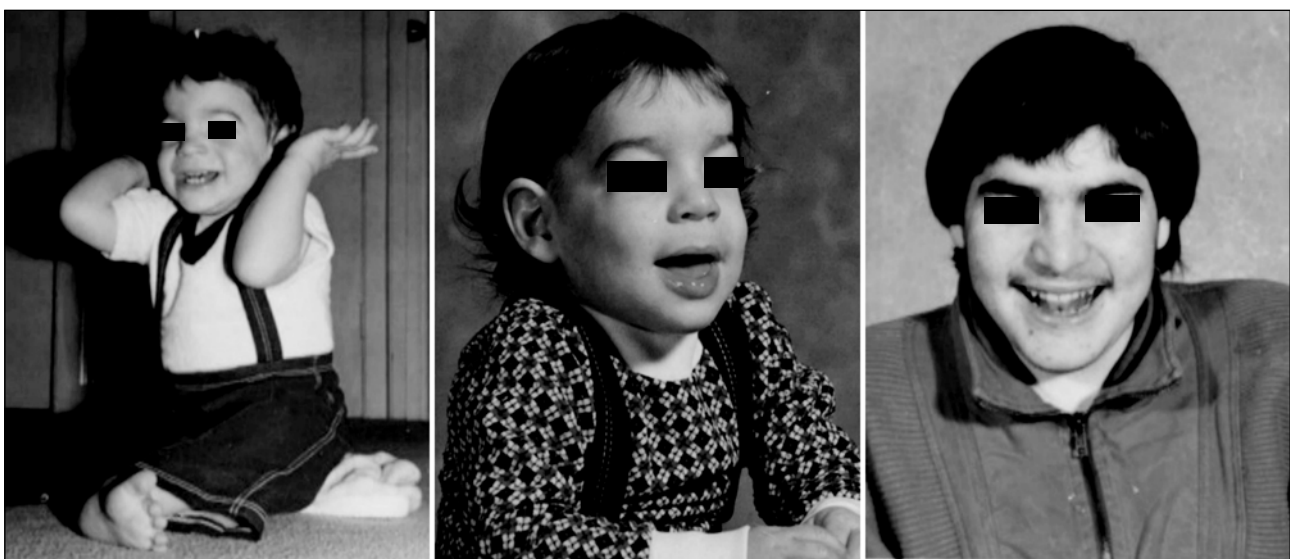

Figure 1. Pictures taken between 1-1.5 years (left and middle) and 15 years of age (right). Note the incipient but characteristic arm flapping (left only), subtle prognathism, tendency for tongue protrusion, and a happy disposition, the appropriateness of which cannot be ascertained here.

wave or abortive spike and wave discharges maximal over the frontal regions. Prolonged episodes of repeated atypical absences occurred lasting for periods up to 2 hours, without return to the interictal clinical baseline, amounting to atypical absence status epilepticus. The individual ictal episodes were associated with subtle head extension, brief loss of awareness, eyelid blinking (*myoclonia*, the "eyelid fluttering" referred to by the parents), upward eye deviation, and arrest of the non-epileptic, hand flapping movements. The ictal EEG changes associated with the atypical absences did not show the expected slow spike and wave activity, but instead, showed repeated bursts of

frontally predominant, rhythmic alpha frequency activity (8-9.5 Hz) lasting from 0.5 to 2.5 seconds (*figure 2*).

The patient had been tested for AS and Rett syndrome 8 and 2 years prior to this evaluation, and both disorders were believed to have been ruled out given the absence of abnormalities in methylation and fluorescence *in situ* hybridization (FISH) techniques for the former, and the lack of the MECP2 mutation for the latter. Based on the dysmorphic features, the stereotypic movements and the documented atypical absence status epilepticus, still suggestive of AS, we requested direct UBE3A mutation analysis, which was diagnostic (2251insAACTA).

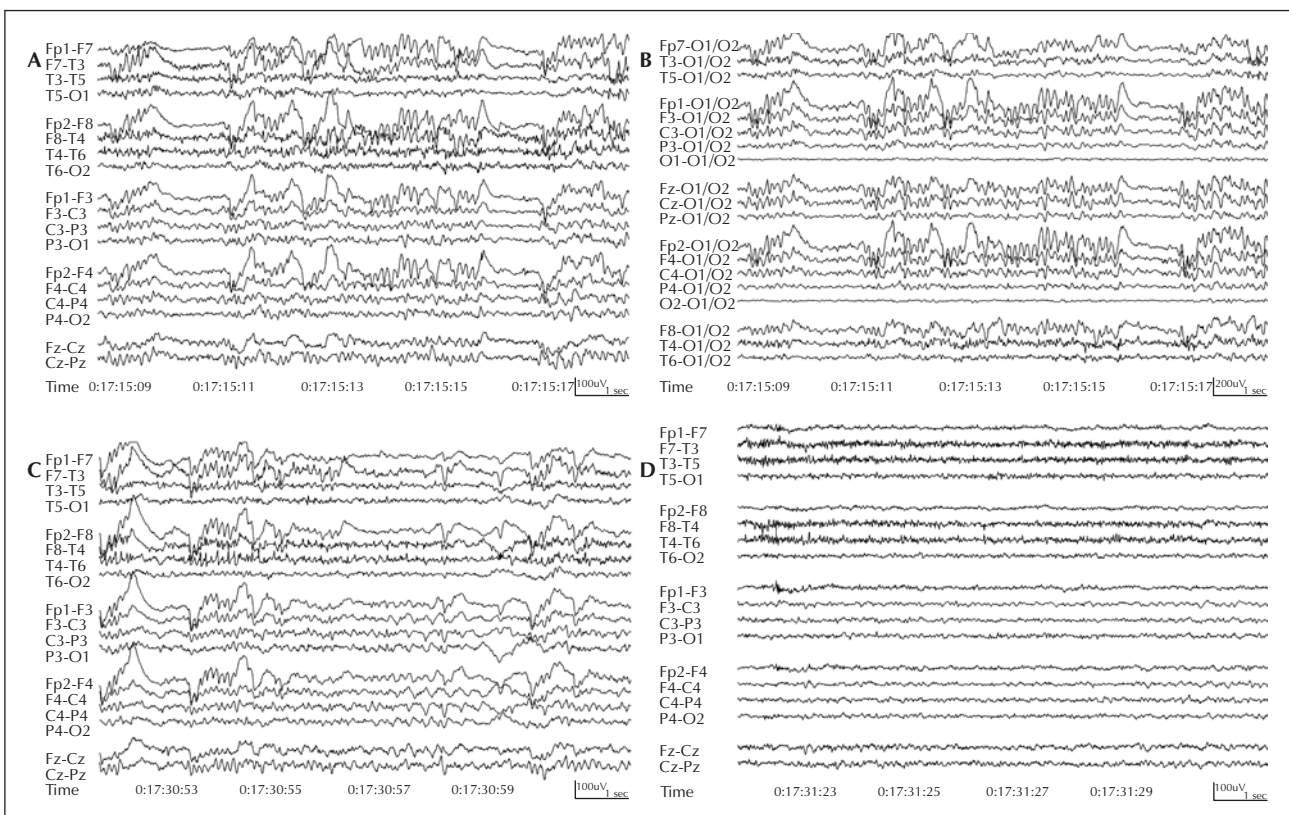


Figure 2. A) Ictal EEG changes associated with the atypical absences showed frontally predominant bursts of rhythmic alpha frequency activity (8-9.5 Hz) lasting from 0.5 to 2.5 seconds, occasionally with a recruiting/derecruiting pattern; the ictal EEG bursts were associated with subtle head extension, eyelid blinking (*myoclonia*), upward eye deviation and arrest of stereotypic hand flapping movements. B) The rhythmic ictal activity could be differentiated from eye flutter artifact by the presence of a subtle, recruiting/derecruiting pattern most evident with the longest bursts, and by the posterior extent of the ictal scalp topographic field when the same EEG sequence was reformatted to a common balanced occipital (O1-O2 average) referential montage. This montage showed the ictal activity extending back to the centroparietal region bilaterally with a gradual amplitude decrement from FP1/FP2 to F3/F4 to C3/CZ/C4 and a much greater fall off to P3/PZ/P4. C) Throughout an entire 2 hours-epoch of absence status, the EEG background activity was markedly different from the background activity recorded immediately before (not shown) and D) immediately after the long clinical episode of absence status, with a large increase in generalized slow wave activity interspersed between the repeated bursts of rhythmic ictal activity. EEG in C is from late ictal phase. EEG in D is 30 seconds later, immediately postictal.

Discussion

We describe previously unreported ictal electroencephalographic features during atypical absence status epilepticus in an adult patient with AS due to the UBE3A gene mutation. The "classical" ictal activity commonly associated with atypical absences in AS, 1-2 Hz sharp and slow wave complexes, usually accompanied by neurological deterioration (Clayton-Smith and Laan 2003, Minassian et al. 1998) was not observed. In a series of 36 AS patients with proven chromosome 15q11-13 deletion, it was demonstrated that, in both children and adults, the most typical EEG findings were rhythmic frontal triphasic delta waves of high amplitude (Laan et al. 1997). In our patient, who importantly did not have the common chromosomal deletion, the interictal EEG did not show the frontal triphasic waves and the ictal EEG was characterized by repeated bursts of frontally predominant rhythmic alpha activity. This unusual ictal EEG pattern, which could be misinterpreted as eye movement artifacts, showed some morphological similarities to ictal changes described in two previous reports in a small number of patients with atypical or typical absences (Nadel et al. 1975, Fakhoury and Abou-Khalil 1999). Accurate identification of the pattern as epileptic is of obvious importance from a diagnostic standpoint. Prior to our seeing the patient, the importance of these EEG abnormalities had not been appreciated and it had been questioned whether the "eyelid fluttering" was a primary movement disorder, possibly accentuated by his previous exposure to neuroleptic drugs.

It should be pointed out that carbamazepine (which our patient did not receive) and phenytoin have been associated with worsening of the epileptic phenotype in AS (Minassian et al. 1998). Our patient however, apparently did not improve during periods of phenytoin "holiday" undertaken prior to our evaluation, and thus the atypical absence status and its unusual, associated ictal EEG pattern is unlikely to have been specifically related to the concurrent administration of phenytoin.

This case also emphasizes the need to pursue a complete genetic evaluation where suspicion for AS remains high despite a "negative" screen. The multiplicity of potential genetic mechanisms causing AS is the main obstacle to making a complete AS diagnostic battery available to clinicians. The routine genetic screening includes the methylation test, which will confirm AS in 85% of patients. FISH and restriction fragment length polymorphism (RFLP) are then carried out to determine if the methylation abnormality is due to maternal deletion (75% of cases), paternal uniparental disomy or imprinting defects (10% combined) (Jiang et al. 1999, Magenis et al. 1987). Therefore, in about 15% of cases, this diagnostic battery will fail to diagnose AS and a direct search for the UBE3A mutation (which accounts for 10% of cases) becomes necessary. In addition to the unusual EEG pattern demonstrated in our patient, his clinical course was atypical for the underlying

genetic cause of his AS. In contrast to AS resulting from maternal 15q11-13 deletion (*class I*), where atypical absence status epilepticus is not unusual, possibly due to deletion of the beta3 subunit of the GABA_A receptor gene in addition to the UBE3A gene, those with mutations in the UBE3A gene (*class IV*) typically have a "milder" phenotype with less frequent myoclonic seizures and greater responsiveness to antiepileptic drugs (Moncla et al. 1999, Minassian et al. 1998). □

Acknowledgements. We are indebted to G.F. Molnar for his expertise in editing and formatting the video and images for this manuscript.

References

- Angelman H. Puppet children. *Dev Med Child Neurol* 1965; 7: 681-8.
- Clayton-Smith J, Laan L. Angelman syndrome: a review of the clinical and genetic aspects. *J Med Genet* 2003; 40: 87-95.
- Fakhoury T, Abou-Khalil B. Generalized absence seizures with 10-15 Hz fast discharges. *Clin Neurophysiol* 1999; 110: 1029-35.
- Jiang Y, Lev-Lehman E, Bressler J, Tsai TF, Beaudet AL. Genetics of Angelman syndrome. *Am J Hum Genet* 1999; 65: 1-6.
- Laan LA, Renier WO, Arts WF, et al. Evolution of epilepsy and EEG findings in Angelman syndrome. *Epilepsia* 1997; 38: 195-9.
- Magenis RE, Brown MG, Lacy DA, Budden S, LaFranchi S. Is Angelman syndrome an alternate result of del(15)(q11q13)? *Am J Med Genet* 1987; 28: 829-38.
- Mann MR, Bartolomei MS. Towards a molecular understanding of Prader-Willi and Angelman syndromes. *Hum Mol Genet* 1999; 8: 1867-73.
- Minassian BA, DeLorey TM, Olsen RW, et al. Angelman syndrome: correlations between epilepsy phenotypes and genotypes. *Ann Neurol* 1998; 43: 485-93.
- Moncla A, Malzac P, Livet MO, et al. Angelman syndrome resulting from UBE3A mutations in 14 patients from eight families: clinical manifestations and genetic counselling. *J Med Genet* 1999; 36: 554-60.
- Nadel A, Waddell G, Volow M, Escueta AV. Unconsciousness, automatism, and myoclonic jerks with diffuse rhythmic 9-Hz discharges. *Epilepsia* 1975; 16: 511-20.

Legend for video sequences

The patient is shown through several "eyelid fluttering" episodes in this homemade videotape. Note the sudden onset and offset of these episodes. Characteristic, non-epileptic behavioral manifestations consisting of arm adduction and external rotation, elbow flexion in close midline proximity and wrist flapping are occasionally associated with laughter, and appear temporally dissociated from the "eyelid fluttering" events, the latter episodes representing atypical absences with eyelid myoclonia.