

# Diaphragm myoclonus followed by generalised atonia in a patient with trisomy 4p: unusual semiology in an unusual condition

James Varley, Tim Wehner, Sanjay Sisodiya

NIHR University College London Hospitals Biomedical Research Centre, Department of Clinical and Experimental Epilepsy, UCL Institute of Neurology, London, UK

Received April 01, 2015; Accepted October 15, 2015

**ABSTRACT** – In this report, we describe a female patient with trisomy 4p, a rare genetic condition, with unusual seizure semiology. The patient is one of the oldest reported survivors with this condition. This semiology was noted while she was being monitored by inpatient video telemetry. We observed a series of myoclonic shoulder jerks, followed by hiccup-like episodes, and finally an atonic head drop. Corresponding ictal EEG showed semi-rhythmic high-amplitude slow waves with spikes superimposed over the frontotemporal areas. This semiology was confirmed as habitual by her parents. Subsequent hiccup-like episodes had no EEG correlate, and the head drop was again associated with semi-rhythmic high-amplitude slow waves and superimposed spikes, more prominent over the right hemisphere. In addition, we review the several cases in which hiccups have been associated with seizures and how this may relate to the neural pathways involved in the pathophysiology of hiccups. We believe the ictal hiccup-like episodes followed by atonia to be a seizure semiology that has not previously been documented. [*Published with video sequence*]

**Key words:** hiccups, seizure, atonic seizure, trisomy 4p

Hiccups have been rarely described as a manifestation of focal epilepsy (Lin *et al.*, 1998; Ponnusamy *et al.*, 2008; Alix *et al.*, 2012; Hahn and Neubauer, 2012). We report an unusual seizure semiology, including hiccup-like episodes, in a patient with an extremely rare genetic condition, trisomy 4p. The patient is one of the oldest reported survivors with this condition.

## Case study

The patient was a 29-year-old female, born from a normal birth and delivery, with no predisposing family history or consanguinity. She was noted to be dysmorphic at birth with talipes equinus. Karyotype was thought to show trisomy 21. She had delayed developmental milestones, initially starting at regular



### Correspondence:

Sanjay M. Sisodiya  
Department of Clinical and Experimental  
Epilepsy, UCL Institute of Neurology,  
33 Queen Square London,  
WC1N 3BG, UK  
<s.sisodiya@ucl.ac.uk>

school with help, but eventually requiring special schooling. She was later diagnosed with *de novo* trisomy 4p, with an unbalanced whole-arm translocation between the short arm of chromosome 4 and the long arm of chromosome 21 (46, XX,+4,der(4;21)(p10;q10). This was confirmed by genome-wide array comparative genomic hybridisation (Nimblegen 135k v3.1 chip). Seizure onset occurred at 11 years, with monthly seizures, with no menstrual relationship as she did not have menarche until the age of 13. Her parents described her going blank and staring, stopping breathing, and progressing to generalised tonic-clonic seizures (GTCS). She had an episode of status epilepticus requiring admission to an intensive care unit (ITU) aged 16 and again required ITU care, aged 23, for a severe chest infection and concurrent uncontrolled seizures. Aged 18 onwards, she had GTCS every four to six weeks with accompanying respiratory arrest, requiring cardiopulmonary resuscitation or sternal rub from her carers, in ~70% of these episodes. At this time, she was also noticed to be having episodes of recurrent hiccups followed by loss of postural tone and decreased responsiveness; these events clustered and could occur repeatedly over 30 minutes. More recently, her carers had become concerned by prolonged periods of decreased responsiveness in the morning, with possible ataxia and dysarthria, as well as episodes of bilateral, repetitive eye blinking associated with upward tonic eye deviation. These episodes lasted around 10 seconds and occurred mostly in the morning.

Other past medical history included vitamin D deficiency, surgically-corrected spinal scoliosis, chronic constipation, recurrent chest infections secondary to reflux which settled when she was put on a thickened diet, previous cataract surgery, blocked lacrimal ducts, hay fever, and abdominal bloating and weight gain, with gallstones seen on abdominal ultrasound.

Her medication on admission to our video telemetry unit was levetiracetam, lacosamide, carbamazepine, clobazam as required, lansoprazole, and regular budesonide and fomoterol inhalers. She had previously tried valproate, gabapentin, topiramate, and lamotrigine. She required help with all activities of daily living, was able to walk around 300 metres, but had no concept of danger and thus required close supervision. She could converse to an extent, make her wishes known, and could follow simple instructions; she has never exhibited aggressive behaviour.

On examination, she was obese with short stature (below 1<sup>st</sup> centile), a short neck, microcephaly (head circumference less than 0.4 centile), low-set misshapen ears, a protruding large tongue (confirmed on nasendoscopy), and facial dysmorphism. Her neuropsychological evaluation pointed to a frontal dysexecutive syndrome. She had normal secondary

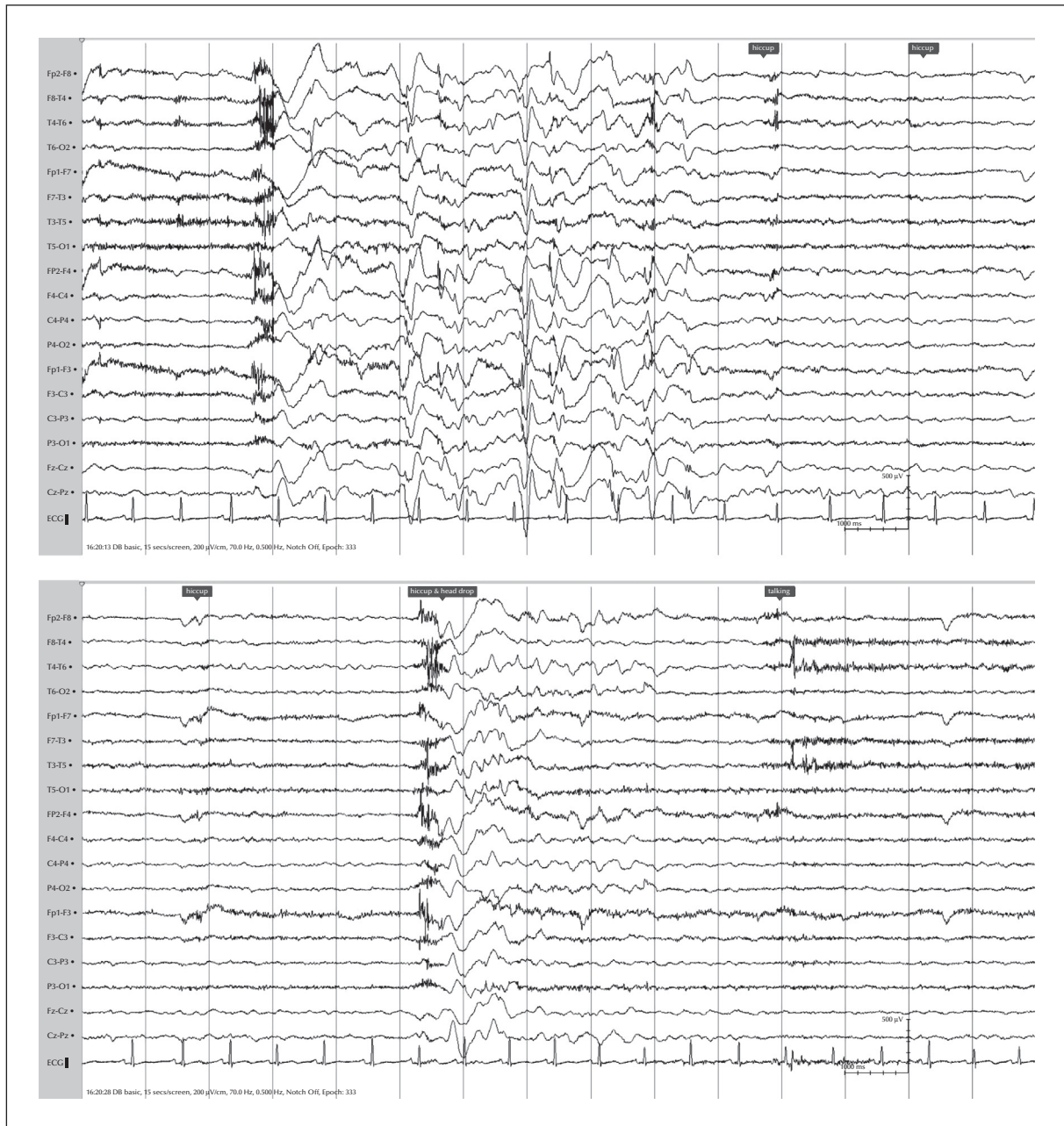
sexual characteristics. Her oxygen saturations on room air were low (86-92%); chest x-ray showed deformities of the 6<sup>th</sup>, 7<sup>th</sup> and 8<sup>th</sup> posterior costal arches. Blood tests showed a thrombocytopenia and pan-hypogammaglobulinaemia. MRI brain imaging was not performed as she would have required generalised anaesthesia, which we considered in her case to be associated with a high risk of complications due to recurrent chest infections and craniofacial dysmorphism.

Continuous video-EEG (Nicolet LTM, sampling frequency 256 Hz) was performed for seven days using standard 10-20 electrodes plus superficial sphenoidal and inferior parietal (P11/12) and inferior frontotemporal (F11/12) electrodes. Her baseline interictal EEG showed semi-rhythmic slow activity in the theta range, with frontocentrally superimposed beta activity. Multifocal epileptiform discharges were seen in the frontocentral and temporal areas bilaterally, often occurring in runs as often as every other 10 seconds during sleep. We recorded an unusual sequence of myoclonic jerks that was identified as habitual by her parents. The patient experienced repetitive myoclonic shoulder jerks, followed by hiccup-like episodes and an atonic head drop (see *video sequences*). These episodes were described as “hiccup-like” because they predominantly involved diaphragm myoclonus, which is present during physiological hiccups, but lacked the reflex closure of the glottis that creates the “hiccup” sound, with associated shoulder myoclonus. The ictal EEG at the time of the shoulder jerks showed a run of semi-rhythmic high-amplitude slow waves with superimposed spikes over the frontocentral areas. Subsequent hiccup-like episodes had no EEG correlate, whilst the head drop was again associated with semi-rhythmic high-amplitude slow waves and superimposed spikes, more prominent over the right hemisphere (*figure 1*).

In addition, she had ictal eyelid flickering for 4-7 seconds during wakefulness, not long enough to assess for any alteration of awareness. During sleep, we observed episodes of hypopnoea or apnoea, lasting 5-12 seconds, with oxygen desaturation as low as 82%, and sometimes leading to an arousal. Initial ictal EEG changes associated with eyelid flickering and hypopnoea/apnoea were non-lateralising diffuse spike-wave discharges, in some instances followed by attenuation and right-sided alpha activity or polyspikes (*figure 2*).

## Discussion

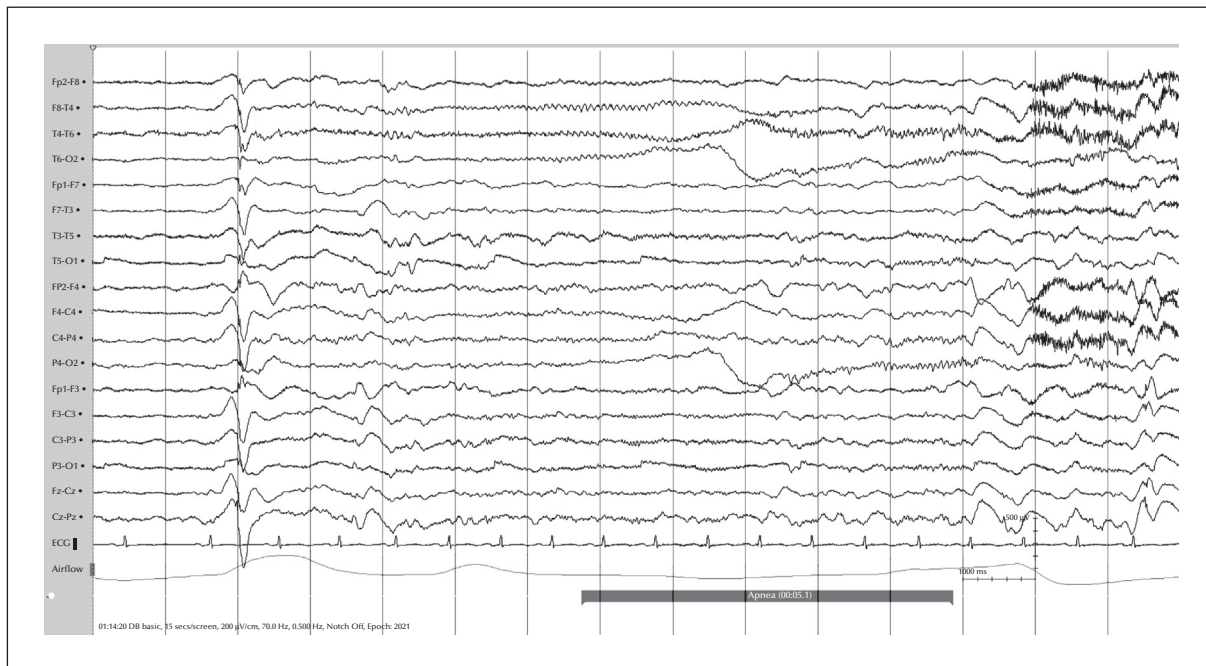
Hiccups are myoclonic contractions of the diaphragm which are followed closely by closure of the glottis, thereby producing the characteristic “hiccup sound”. In normal physiological situations, the contraction



**Figure 1.** Ictal EEG (longitudinal bipolar montage; high-pass filter: 0.5 Hz; low-pass filter: 70 Hz; Scalebar: 1 sec/500  $\mu$ V); two consecutive 15-second pages corresponding to shoulder myoclonus, hiccups, and head drop. Labels correspond to semiological features on the video sequence.

involves both afferent and efferent pathways: the afferent portion includes the vagus nerve, phrenic nerve and sympathetic chain, whilst the efferent limb involves the phrenic nerve. Hiccups are mediated by a central control network, thought to be located primarily in the medulla oblongata, with modulation by the hypothalamus, reticular activating system, and the temporal lobe (Loft and Ward, 1992). Hiccups are predominantly a benign, self-limiting, idiopathic

occurrence. They can be secondary to alcohol excess, gastric distension, carbonated beverages, anxiety, or stress. They are rarely persistent (lasting for more than 48 hours) or intractable (lasting for more than one month), with over 100 known causes (categorised according to lesions or stimulation of the central nervous system, diaphragmatic irritation, vagal nerve irritation, drug-induced metabolic alterations, and surgical, infectious, psychogenic, or idiopathic causes)



**Figure 2.** EEG recording (same settings as in *Figure 1*) of apnoeic seizures during sleep.

(Lewis, 1985). Although the episodes described in our case do not overlap exactly with physiological hiccups, our contention is that they are phenotypically similar enough to suggest that they share neuroanatomical and neurophysiological properties.

Hiccups in the context of epilepsy have been described only in case reports. Lin *et al.* reported six children with benign myoclonic epilepsy who had characteristic brief, expiratory noises associated with seizures which they believed to be diaphragmatic in origin (Lin *et al.*, 1998). Later, case reports demonstrated hiccups as part of left temporal lobe seizures in one case (Fogarasi *et al.*, 2006) and during one child's established absence seizures, with the hiccups being time-locked with the 3-Hz generalised spike-and-wave discharge seen on EEG (Ponnusamy *et al.*, 2008). A further group reported a 6-year-old with hiccups as a predominant symptom of her juvenile myoclonic epilepsy, with EMG spikes closely correlating with EEG discharge and diaphragmatic myoclonus, but, exceptionally, no other forms of limb myoclonus (Hahn and Neubauer, 2012).

Alix *et al.* reported two adults with hiccups as part of their seizure semiology (Alix *et al.*, 2012). The first was a 73-year-old female with right mesial temporal sclerosis and semiology characterised by right hand automatisms, head version, left hand clonus and finally hiccups, which eventually lead to seizure termination. Ictal EEG showed right anterior temporal seizure onset; the patient became seizure-free following a right selective amygdalohippocampectomy. The second was a 23-year-old with right parietal gliosis and mesial

temporal sclerosis whose seizure semiology involved fidgeting and repetitive lower limb movements, followed by oro-buccal automatisms, vocalisations and then hiccups, after which the seizure terminated. The ictal EEG evolved over the right centroparietal region. These two adult cases demonstrate hiccups as a late ictal occurrence in people with focal epilepsy, whereas in the paediatric cases, generalised epilepsies predominate. Ictal hiccups may be mediated via ictal interference with the central portion of the hiccup reflex arc.

It is also possible that increased vagal nerve tone, the afferent of the hiccup reflex arc, causes the hiccups and contributes to termination of the seizures, as opposed to being part of seizure semiology. An inhibitory effect of hiccups was reported in a patient with daily absence seizures who then developed intractable hiccups, occurring every one to three seconds during which time his habitual seizures stopped. EEG showed frontal spikes only, and after eight days his hiccups spontaneously terminated and his seizures promptly returned (Ikeda *et al.*, 2001). In support of this suggestion, the 23-year-old patient described by Alix *et al.* (2012) had significantly improved seizure control with insertion of a vagal nerve stimulator.

This inhibitory aspect of hiccups does not seem to apply in all cases however, most notably in the Hahn and Neubauer (2012) case report where the hiccups were an early and predominant semiological feature. In addition, the hiccup-like episodes were a similarly predominant feature in our case, and were eventually

followed by generalised atonia with head drop. It is possible, therefore, that in some cases there are hiccups due to activation of hiccup reflex afferents by increased vagal nerve tone, but in other cases, hiccups are a direct result of cortical seizure activity feeding into hiccup reflex efferents. The novel semiology described here is associated with predominantly frontocentral ictal EEG activity, which may be suggestive of activity involving a temporal or hypothalamic aspect of the hiccup reflex arc, which is then feeding into the brainstem and activating hiccup reflex efferents, thus evading evaluation with scalp EEG electrodes. Rare cases of epilepsy related to brainstem lesions have been reported (Dagcinar *et al.*, 2007). As the seizure progressed in our case, the ictal scalp EEG findings suggested propagation of seizure activity to involve negative motor areas, such as the primary negative motor area in the inferior frontal gyrus or the supplementary negative motor area in front of the supplementary sensorimotor area (Lüders *et al.*, 1995), linking hiccup-like episodes with atonia.

As one of the oldest known survivors with trisomy 4p, there is a possibility that this semiology may be unique to this condition. Our case lends weight to the suggestion that hiccups or hiccup-like episodes can be a manifestation of epilepsy and may be associated with atonic seizures, the latter being a novel finding. □

#### Disclosures.

The authors have no conflict of interest to declare.

## References

- Alix JJ, Ponnusamy A, Bhattacharyya D, Hoggard N, Grunewald RA. Complex partial seizures: going out with a hiccup. *Seizure* 2012;21: 820-2.
- Dagcinar A, Hilmi Kaya A, Ali Tasdemir H, Kuruoglu E, Sabancilar Z, Sav A. A fourth ventricular ganglioneurocytoma representing with cerebellar epilepsy: a case report and review of the literature. *Eur J Paediatr Neurol* 2007;11: 257-60.
- Fogarasi A, Janszky J, Tuxhorn I. Autonomic symptoms during childhood partial epileptic seizures. *Epilepsia* 2006;47: 584-8.
- Hahn A, Neubauer BA. Epileptic diaphragm myoclonus. *Epileptic Disord* 2012;14: 418-21.
- Ikeda A, Matsuoka K, Nakaya Y, Shibasaki H. Hiccups start, seizures cease. *Ann Neurol* 2001;50: 128-9.
- Lewis JH. Hiccups: causes and cures. *J Clin Gastroenterol* 1985;7: 539-52.
- Lin Y, Itomi K, Takada H, *et al.* Benign myoclonic epilepsy in infants: video-EEG features and long-term follow-up. *Neuropediatrics* 1998;29: 268-71.
- Loft LM, Ward RF. Hiccups. A case presentation and etiologic review. *Arch Otolaryngol Head Neck Surg* 1992;118: 1115-9.
- Lüders HO, Dinner DS, Morris HH, Wyllie E, Comair YG. Cortical electrical stimulation in humans. The negative motor areas. *Adv Neurol* 1995;67: 115-29.
- Ponnusamy A, Rao G, Baxter P, Field P. Ictal hiccup during absence seizure in a child. *Epileptic Disord* 2008;10: 53-5.

### Legend for video sequence

Here the patient can be noted to experience repetitive myoclonic shoulder jerks, followed by hiccup-like episodes and an atonic head drop, with no resulting prolonged loss of consciousness.

#### Keywords for the video research on [www.epilepticdisorders.com](http://www.epilepticdisorders.com)

*Syndrome:* Lennox-Gastaut; FLE; TLE

*Aetiology:* trisomy 4p

*Phenomenology:* shoulder and diaphragmatic myoclonus and axial atonia

*Localization:* multifocal (negative motor areas, frontal lobe, temporal lobe) or generalised