

Epileptic seizure semiology in different age groups

Guadalupe Fernandez-Baca Vaca¹, Carlos L. Mayor²,
Naira García Losarcos^{1,3}, Jun T. Park¹, Hans O. Lüders¹

¹ University Hospitals Cleveland Medical Center, Cleveland, Ohio, USA

² Fundacion Santa Fe de Bogotá, Bogotá, Colombia

³ University of Miami, Miami, Florida, USA

Received June 01, 2017; Accepted February 22, 2018

ABSTRACT – Aims. Seizure semiology provides information about the eloquent cortex involved during a seizure and helps to generate a hypothesis regarding the localization of the epileptogenic zone (EZ), a prerequisite for surgical management of epilepsy. We aimed to study the seizure semiology among all different age groups to better characterize semiological changes that occur with age.

Methods. We performed a retrospective review of video-EEG data in paediatric and adult patients admitted to the Epilepsy Monitoring Unit over a three-year period. Authors independently reviewed and classified the seizure semiology while blinded to clinical, EEG, and neuroimaging data. A total of 270 patients were included in the study.

Results. The most frequent EZ in patients who were one month to three years old was undetermined. Focal epilepsy became more frequent in patients older than 10 years. Among patients with focal epilepsy, a posterior quadrant EZ was most frequent in children younger than three years old, a temporal EZ between three and six years old, and a frontal EZ between six and 10 years old. The temporal lobe was the most frequent location for focal EZ in patients older than 18 years. Auras, automotor seizures, and generalized tonic-clonic seizures were extremely infrequent in patients younger than 10 years old. The youngest patient with auras was 5.7 years old. The youngest patient with automotor seizures was 3.7 years old. We identified only three patients with generalized tonic-clonic seizures who were younger than 10 years (aged six months, 6.6 years, and nine years, respectively). Patients younger than three years exhibited mostly generalized simple motor seizures and hypomotor seizures. Generalized epileptic spasms, generalized tonic seizures, and generalized clonic seizures were infrequent in patients older than 10 years.

Conclusion. Seizure semiology and electroencephalographic changes most likely reflect the maturation of cortical functions.

Key words: seizure semiology, epileptic auras, automotor seizures, generalized tonic-clonic seizures, generalized tonic seizures

Correspondence:

Guadalupe Fernandez-Baca Vaca
UHCMC,
11100 Euclid Av. Lakeside building 3200,
44106 Cleveland, Ohio, USA
<guadalupe.fernandezbacavaca2@
uhhospitals.org>

Seizure semiology provides information about the eloquent cortex involved during a seizure and may help to generate a hypothesis regarding the location of the epileptogenic zone (EZ) (Lüders *et al.*, 2006). This information may be helpful in the surgical management of epilepsy.

Prior seizure semiology studies suggest that some seizure types are either not present or only seen in the paediatric population. This change of seizure semiology with age most probably reflects the maturation of the cortex and may be a good index of the degree of maturation of cortical functions. However, not all age groups were analysed in previous seizure semiology studies.

In this study, we investigated seizure semiology in all different age groups (infancy through to adulthood) by analysing video recordings of seizures during admission to our Epilepsy Monitoring Unit, in order to better characterize the semiological changes that occur with age.

Materials and methods

We performed a retrospective review of video-EEG data from paediatric and adult patients admitted to the Epilepsy Monitoring Unit (EMU) at the University Hospital Cleveland Medical Center during a period of three years.

Clinical charts were reviewed and patients who had experienced one or more epileptic seizures during the EMU evaluation were included in the study. Two authors independently reviewed the videos while blinded to EEG and clinical data. Each clinical seizure was classified using the Semiological Seizure Classification (Lüders *et al.*, 1998). Results for each seizure were compared. If there was any disagreement, a consensus decision was taken during a weekly meeting with the senior author (HOL).

In order to define the location of the EZ, we used the interictal EEG (irritative zone), ictal EEG (seizure onset zone), and neuroimaging findings (epileptogenic lesion). We classified the EZ as generalized when the interictal and ictal activity were generalized and the MRI showed no focal lesion. We classified the EZ as focal when the irritative and ictal onset zones showed focal and concordant findings, and neuroimaging was either negative or showed a concordant focal lesion. The rest of the patients, who did not show a good correlation between the different zones, were classified as “undetermined”. This included patients with a focal MRI lesion and generalized or multifocal ictal and interictal activity on EEG. Note that seizure semiology was not used to define the EZ.

All seizures were analysed for each patient. One representative seizure for each seizure type was included

in the final analysis. One patient could have one or more seizure types, with each seizure type consisting of several seizure components. The evolution from one seizure component to another was marked by an arrow. Lateralizing signs were listed independently for each seizure type, if not already listed as part of the seizure evolution. Examples of the information listed for each patient is given below:

Patient 1

Video-EEG 1: Nine months old.

Seizure type 1: Hypomotor seizure → generalized clonic seizure.

Seizure type 2: Epileptic spasms.

Video EEG 2: Two years old.

Seizure type 1: Generalized tonic seizure → generalized clonic seizure.

Patient 9

Video-EEG 1: Thirty-five years old. Only one EMU admission.

Abdominal aura → automotor seizure (with loss of awareness) → right versive seizure → generalized tonic-clonic (GTC) seizure.

Lateralizing sign: Postictal aphasia.

Patients were divided into different age groups based on the age when the seizures were recorded in the EMU. As a result, if one patient had multiple video-EEG admissions at different points in time, he/she was included in more than one age group. For example, a child would be included in two different age groups if the first video-EEG evaluation was performed at age two years, and a second evaluation at age six years.

Results

A total of 1,140 patient's charts were reviewed. Out of these, 852 patients were excluded as they had either no recorded events, or non-epileptic paroxysmal episodes. Epileptic paroxysmal events were recorded in 288 patients during EMU admissions. Eighteen patients were subsequently excluded from the study: seven patients had electrographic seizures only and 11 patients had poor quality video recordings. A total of 270 patients were included in the study. More than one seizure type was recorded in 16 paediatric and 19 adult patients.

The number of patients in different age groups is represented in *figure 1*. Only one patient was included in two different age groups. This patient underwent two video-EEG evaluations at five and 6.5 years, respectively. The first evaluation showed bilateral symmetric myoclonic seizures, and the second evaluation showed GTC seizures 1.5 years later.

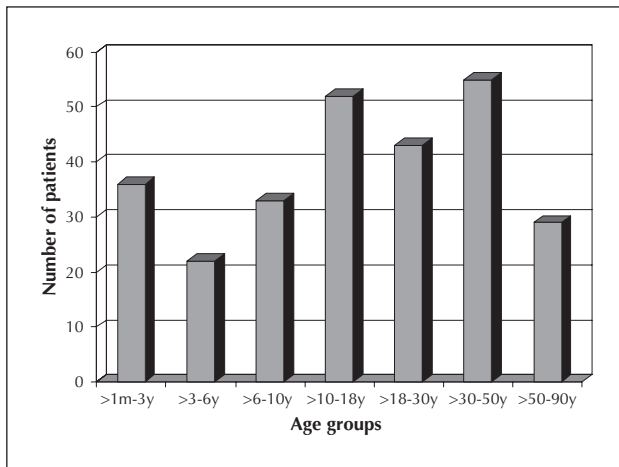


Figure 1. The number of patients in the different age groups.

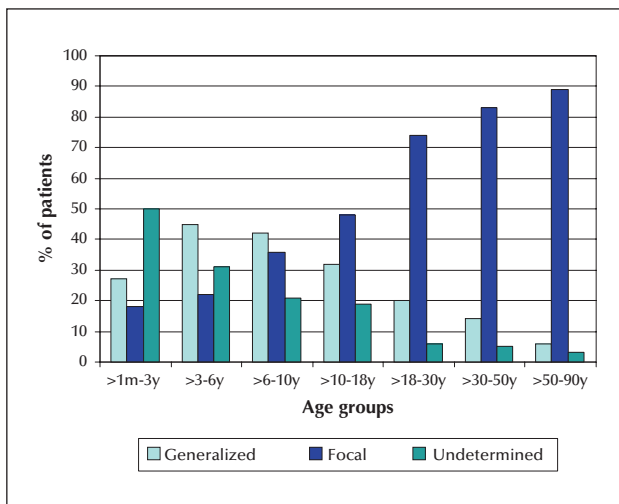


Figure 2. The type of the epileptogenic zone according to the different age groups.

The epileptogenic zone (EZ)

Figure 2 shows the most likely EZ for the different age groups. A significant proportion of young children, especially those below three years of age, had undetermined EZ. The number of undetermined EZs decreased with age, whereas that of focal epilepsy increased with age, being the most frequent EZ in patients older than 10 years old. A generalized EZ was most frequent in patients between three and 10 years of age. Among patients with focal epilepsy (*supplementary figure 1*), temporal lobe epilepsy was the most frequent in patients older than 18 years. The most frequent location for the EZ was the posterior quadrant in children younger than three years and temporal in patients between three and six years.

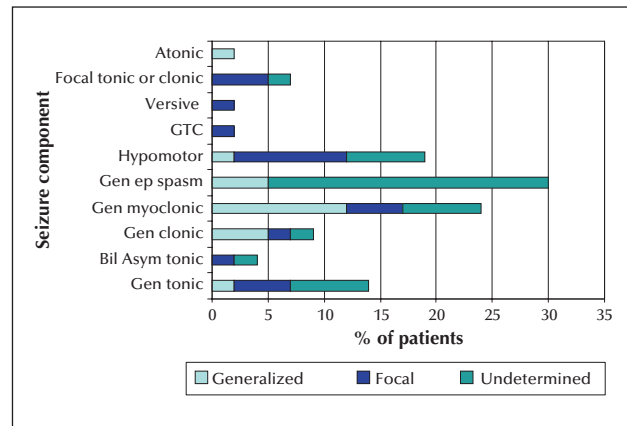


Figure 3. Seizure components in patients aged one month to three years of age.

Seizure semiology for the different age groups

One month to three years old

(figure 3, supplementary figures 2, 3)

Generalized simple motor seizures (spasms and tonic, myoclonic, and clonic seizures) and hypomotor seizures accounted for almost all seizure types seen in this age group. The most frequent EZ was undetermined (80%).

The most common seizure type was generalized epileptic spasms (30% of patients), which were bilateral and symmetric. Most of these patients had an undetermined EZ (95% of patients with epileptic spasms). Only 5% of the patients with epileptic spasms had a generalized EZ.

Generalized myoclonic seizures were the second most common type of seizure (24% of patients), and of the patients with these seizures, the EZ was considered generalized in 50%, focal in 20%, and undetermined in the rest.

Hypomotor seizures were the third most common seizure type in this age group (19% of patients). Fifty percent of patients with hypomotor seizures had a focal EZ, which was localized to the posterior quadrant in 75% of patients and only lateralized in the remaining 25%.

A six-month-old girl with a right frontal EZ had a hypomotor seizure that evolved into a GTC seizure. This GTC seizure exhibited a semiology that was extremely similar to the GTC seizures seen in adults. It lasted for a total of 1.5 minutes. It started with a short and symmetric tonic phase (with a duration of three seconds) with extension of the arms and legs in a decerebrate posture, evolving into a jittery phase, followed by a long clonic phase (82 seconds). However, contrary to what is usually seen in adults and older children, the tonic phase was brief and not as "intense" (the EMG

artefact was not as intense as that in adults). Also, the seizure was not followed by postictal EEG suppression. The patient returned to baseline ~120 seconds after the seizure.

No auras or automotor seizures were seen in this age group. Mouth automatisms occurred in several patients, but the seizures were not classified as automotor seizures because similar automatisms were also seen frequently during interictal periods.

Three to six years old

(figure 4, supplementary figures 2, 3)

The most frequent seizure type in this age group was generalized myoclonic seizure (34%), followed by bilateral generalized tonic seizure (21%) and focal tonic or clonic seizure (21%). The EZ was most frequently generalized (46%).

For 80% of the patients with myoclonic seizures, the EZ was generalized, and undetermined in the rest. On the other hand, most of the patients with generalized tonic seizures had an undetermined EZ (60%). Eighty percent of the patients with generalized tonic seizures had refractory epilepsy and were developmentally delayed. Focal clonic or tonic movements occurred in 21% of the patients during their seizures. The EZ in 60% of these patients was focal and undetermined in 40%. When the EZ was focal, the focal movement was always contralateral to the EZ.

This was the youngest age group in which we observed auras and automotor seizures. Automatisms were characterized mostly by lip smacking (which was clearly different from the patient's interictal behaviour).

Of note, no GTC seizure was seen in this age group of three to six years. Dialeptic and hypomotor seizures were not frequent, and these occurred only in patients with a generalized EZ.

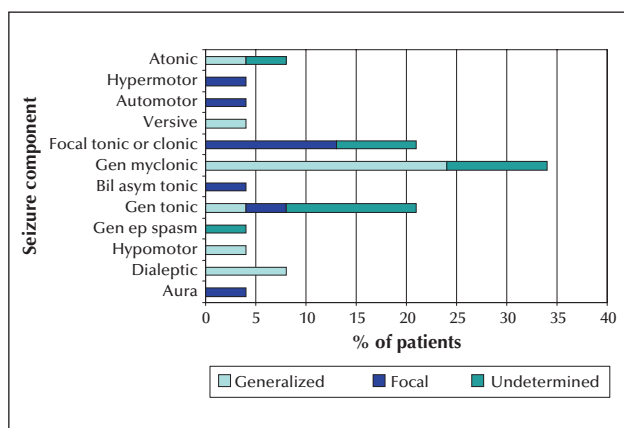


Figure 4. Seizure components in patients aged three to six years of age.

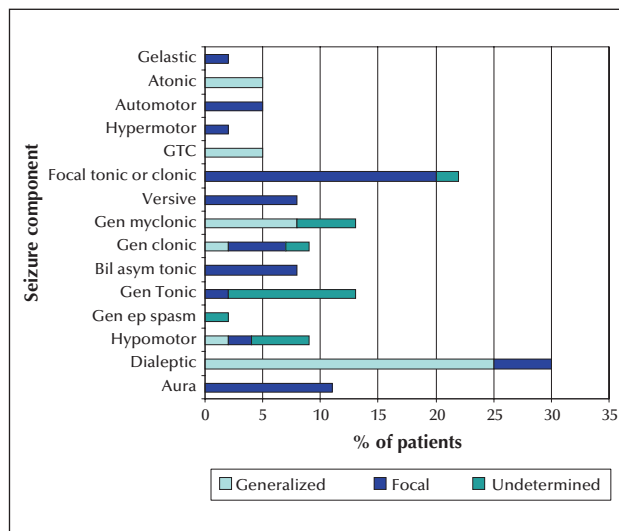


Figure 5. Seizure components in patients aged six to ten years of age.

Six to ten years old

(figure 5, supplementary figures 2, 3)

The most frequent seizure type in this age group was dialeptic, which was seen in 30% of the patients. Eighty-three percent of the patients with dialeptic seizures had a generalized EZ and 17% had a focal EZ.

Similar to the previous age groups, 22% of the patients showed focal tonic or clonic movements during their seizures. Ninety percent of these patients had a focal EZ, and the tonic or clonic movement was always contralateral to the EZ.

Generalized myoclonic seizures were seen in 13% of the patients in this group, and 61% of these had a generalized EZ, and the rest had an undetermined EZ.

Generalized tonic seizures were seen in 13% of the patients, and 80% of these had an undetermined EZ. Most of these patients had global developmental delay, and we were not able to clearly define the patients' mental status during the seizure.

Three patients had repetitive, brief, bilateral, asymmetric tonic seizures, occurring particularly at night. Of the three patients, two had no loss of awareness during seizures and one had an unknown level of awareness. The most likely location for the EZ was mesial frontal in all three cases. These patients were not developmentally delayed.

Four patients experienced an aura, and all of these patients had a focal EZ. The auras were: non-specific, abdominal aura, or visual aura.

Only two patients had GTC seizures; the EZ was generalized in both patients. As compared to adult GTC seizures, these GTC seizures appeared less violent, with less "intense" EMG artefact on the EEG, and had a shorter tonic phase.

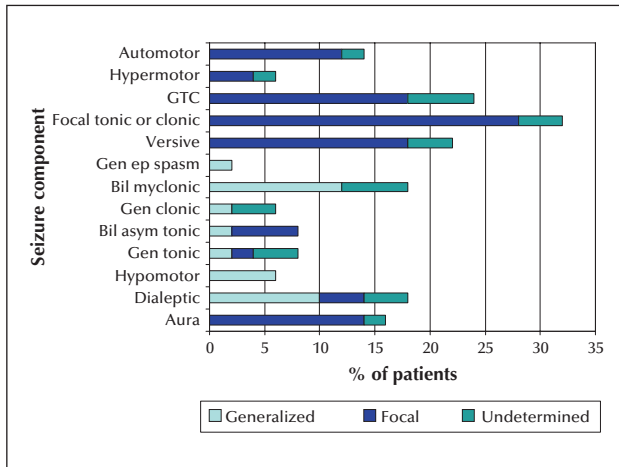


Figure 6. Seizure components in patients aged 10 to 18 years of age.

Automotor seizures were recorded in two patients, and were characterized mostly by oral automatisms with lip smacking and repetitive swallowing.

The youngest patient with hypermotor seizures was seen in this group; an eight-year-old girl with a right temporal lobe EZ. She had hypermotor movements, mostly in the lower extremities, with repetitive hip and knee flexion/extension movements. She did not have any vocalizations during the seizure.

Versive seizures were seen in three patients, all of whom had focal EZs which were contralateral to the head version.

10 to 18 years old

(figure 6, supplementary figures 2, 3)

Most of the patients in this age group had focal epilepsy. The seizure semiology in this age group closely resembled that of the adult population.

The most frequent seizure types were focal clonic or tonic seizures (32% of the patients in this age group). Eighty-seven percent of these patients had a focal EZ, and the tonic or clonic movements were always contralateral to the EZ.

GTC seizures occurred in 12 patients, and 90% of these had a focal EZ; the rest had an undetermined EZ. In most cases, these seizures were preceded by automotor or dialeptic seizures. During seizure evolution, most of the patients experienced focal tonic or clonic seizures and/or versive seizures. The intensity of the muscle artefact during the tonic phase of the seizure resembled the intensity observed in adults. All patients but one had postictal suppression. Overall, the tonic phase, postictal suppression, and recovery time were shorter in the paediatric population compared to adults.

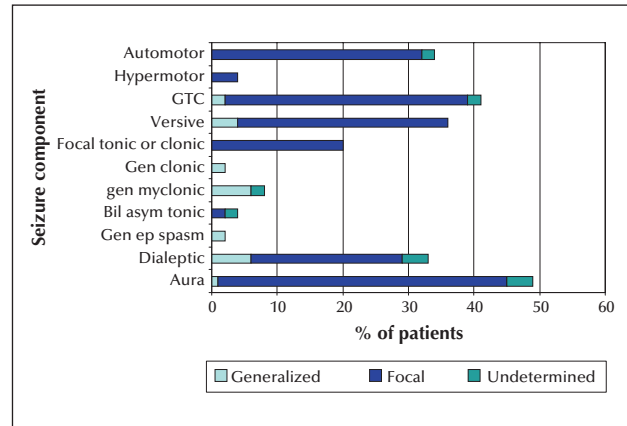


Figure 7. Seizure components in patients aged 18 to 30 years of age.

Twenty-two percent of the patients in this age group had versive seizures. Eighty percent had focal EZ, which was contralateral to the version, and 20% had an undetermined EZ. The versive seizures were preceded by dialeptic (30% of patients), automotor (30% of the patients), clonic facial (20% of the patients), tonic arm (10% of patients), and bilateral myoclonic seizures (10% of the patients). The versive seizures were followed by a GTC seizure in 70% of the patients.

Automotor seizures occurred in 14% of the patients. These seizures consisted predominantly of oral and hand automatisms, which were more prominent than those observed in younger age groups.

Eight patients experienced auras that were psychic, visual, somatosensory, abdominal, auditory or non-specific.

Myoclonic, dialeptic, and hypomotor seizures occurred mostly in patients with a generalized EZ.

A 10-year-old girl with cerebral palsy, severe cognitive delay, and intractable epilepsy had generalized epileptic spasms.

The adult population

(figures 7, 8, 9, supplementary figures 2, 3)

The results for all adult population groups are outlined below. Auras, automotor or dialeptic seizures, followed by versive seizures, evolving into secondary GTC seizures were the most frequent semiology seen in our adult population.

In patients older than 50 years of age, there was a decrease in the number of GTC seizures, focal tonic or clonic seizures, and versive seizures.

GTC seizures occurred as secondary generalization in 93% of the patients. The EEG during the tonic phase showed more intense muscle artefact compared with that for younger patients.

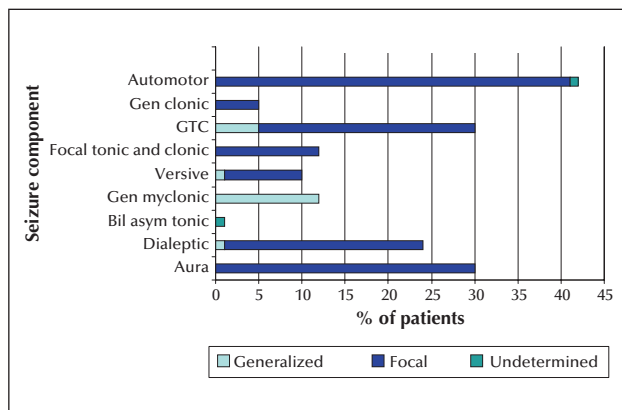


Figure 8. Seizure components in patients aged 30 to 50 years of age.

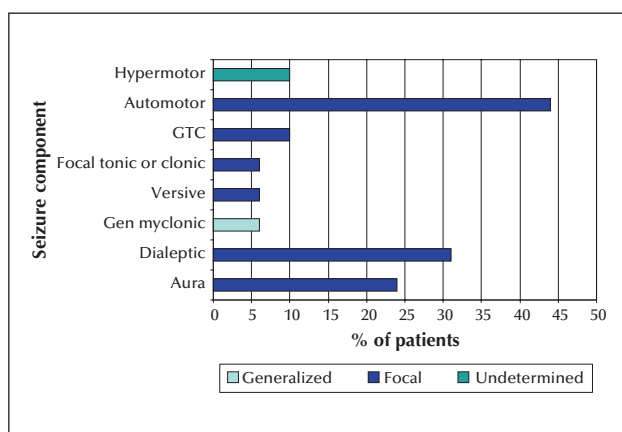


Figure 9. Seizure components in patients aged 50 to 90 years of age.

Generalized myoclonic seizures were seen infrequently, but when seen, occurred in patients with a generalized EZ.

Seizure components

The percentage of patients who had more than one seizure component in the different age groups was: 19% of patients younger than three years of age, 24% of patients between three and six years, 42% of patients between six and 10 years, 50% of patients older than 10 years, and 60% of adult patients. For patients older than 10 years, their semiology and progression closely resembled that of the adult population.

Discussion

This is the first study in which seizure semiology has been analysed in all age groups; from one month to 90 years old. In this study, auras, automotor seizures, and GTC seizures were infrequently seen in patients

younger than 10 years of age. Auras were first seen in a 5.7-year-old girl. The first automotor seizure was seen in a 3.7-year-old girl. Typical GTC seizures were extremely infrequent in patients younger than six years of age. Only one GTC seizure with a brief tonic phase and without postictal suppression was identified in a six-month-old girl. On the other hand, generalized epileptic spasms, generalized tonic seizures, and generalized clonic seizures were infrequently seen in patients older than 10 years of age. Seizure evolution was simpler in patients younger than three years (with only one seizure component), followed by an increase in the number of seizure components with age. In addition, there was a high number of patients younger than three years with undetermined EZ. The number of patients with undetermined EZ decreased with age, and the number of patients with focal EZ started to increase after six years of age, being the most frequent form of EZ in patients older than 10 years. These seizure semiologies and electroencephalographic changes most likely reflect the maturation of cortical functions.

As mentioned above, there was a high number of patients with undetermined EZ in our infant population (one month to three years old). Most of these patients exhibited epileptic spasms, generalized tonic seizures, and/or hypomotor seizures in the setting of multifocal interictal epileptiform discharges, with either generalized or multifocal ictal EEG patterns. The number of patients with undetermined EZ decreased with age. In patients older than six years of age, ictal, interictal, and imaging showed a clearer correlation, making it easier to define the EZ, leading to a decrease in the number of undetermined EZs. Focal, not generalized epilepsy was most frequent in patients older than 10 years. These results may reflect a bias in our patient population. Our study cohort was exclusively derived from EMU admission data. EMU admissions, however, are most frequent for focal epilepsy patients who undergo presurgical evaluation. Therefore, the location of the EZ in patients who are admitted to the EMU most likely does not reflect the EZ location in the "general" epilepsy population seen in the outpatient setting. Nevertheless, a paediatric prevalence study based on outpatient and inpatient retrospective chart review, carried out in Finland (Tampere University Hospital), found that focal epilepsy was indeed the most prevalent type of epilepsy in children older than 10 years of age, whereas generalized and focal EZs were equally frequent in patients between six and 10 years of age (Eriksson and Koivikko, 1997). These findings are fairly similar to those from our EMU population.

Simple motor seizures and hypomotor seizures accounted for all seizure types observed in patients younger than three years of age. This has already been observed in previous studies (Duchowny, 1987;

Yamamoto *et al.*, 1987; Oller-Daurella and Oller, 1989; Brockhaus and Elger, 1995; Hamer *et al.*, 1999; Fogarasi *et al.*, 2002; Ray and Kotagal, 2005). Most of the simple motor seizures in this age group (one month to three years old) were generalized (generalized epileptic spasms and generalized tonic, generalized myoclonic, and generalized clonic seizures). In this age group, generalized simple motor and hypomotor seizures occurred in patients with a focal or generalized EZ. No complex motor seizures (hypermotor or automotor seizures) or auras were identified in this age group.

We found that generalized epileptic spasms were the most frequent seizure type in patients younger than three years of age, and were extremely infrequent beyond this age group. Tonic seizures were most frequently seen in patients aged three to six years, and no generalized tonic seizures were seen in patients older than 12 years. In addition, patients with generalized epileptic spasms and generalized tonic seizures frequently shared a similar phenotype: an undetermined EZ and cognitive impairment. This may support prior investigations reporting that epileptic spasms are replaced by generalized tonic seizures in older age groups (Gastaut *et al.*, 1963; Egli *et al.*, 1985). Previous observations reveal that tonic seizures usually do not begin after eight to 10 years of age, and disappear after 15 to 30 years of age (Gastaut *et al.*, 1963). We did not identify any generalized tonic seizures in patients older than 12 years, however, we are aware that generalized tonic seizures exist in the adult population. This is most likely related to population bias, as these adult patients are most frequently seen in the outpatient and acute inpatient setting, rather than in the EMU. Nevertheless, in the adult population, generalized tonic seizures are probably less frequent than other generalized motor seizures, such as generalized myoclonic, generalized clonic, or GTC seizures. In this study, 60% of the patients with generalized tonic seizures had an undetermined EZ, refractory epilepsy, and were developmentally delayed, and this has been described in previous studies (Rodin *et al.*, 1976; Patel *et al.*, 2006). Previous observations indicate that generalized clonic seizures occur almost exclusively in early childhood and are less frequent than generalized tonic seizures (Gastaut and Broughton, 1972). In this study, generalized clonic seizures were seen infrequently. They occurred mostly in patients younger than three years of age and almost disappeared in patients older than 10 years of age. Only 33% of the paediatric patients with clonic seizures were developmentally delayed.

Typical GTC seizures were extremely infrequent in paediatric patients. On the other hand, GTC seizures are frequently reported by paediatricians. It is very likely that in these cases, the paediatricians are not referring to typical GTC seizures, but to the other gen-

eralized motor seizures, such as epileptic spasms, or generalized tonic or generalized clonic seizures, which are all frequent in the paediatric population. Typical GTC seizures are characterized by a very specific sequence of motor events. GTC seizures should be approximately symmetric, starting with a generalized tonic contraction, in decorticate or decerebrate posture. This is followed by a generalized "jittery phase" that evolves into generalized clonic jerking. The contractions of the clonic phase are mainly proximal and decrease progressively in frequency, while the amplitude of the jerks increases. Even though GTC seizures have been described as mostly symmetric, reports suggest that the clonic phase of GTC seizures can be asymmetric, more often for secondary GTC seizures (Franca *et al.*, 2014). After the clonic phase, postictal coma occurs (Gastaut and Broughton, 1972). Korff *et al.* were unable to identify any GTC seizures based on a retrospective review of 109 seizures in 77 infants (Korff and Nordli, 2005). Similarly, Hamer *et al.* were unable to identify any GTC seizures after reviewing 296 seizures from 76 patients, aged one month to three years (Hamer *et al.*, 1999). Based on a study of 29 patients with temporal lobe epilepsy (18 months to 16 years of age), Brockhaus *et al.* were unable to identify any GTC seizures in patients younger than six years old (Brockhaus and Elger, 1995). Fogarasi *et al.* reviewed 111 seizures from 14 patients with frontal lobe epilepsy (aged three to 81 months) (Fogarasi *et al.*, 2001), as well as 110 seizures from 18 patients with occipital lobe epilepsy (aged three to seven years) (Fogarasi *et al.*, 2003), and did not observe any typical GTC seizures. Lastly, Wyllie *et al.* reviewed seizures from 18 children aged 16 months to 12 years with temporal lobe epilepsy and found that the youngest patient with GTC seizures was eight years old (Wyllie *et al.*, 1993). In our study, GTC seizures were extremely infrequent in patients younger than 10 years. We identified only three patients with GTC seizures who were younger than 10 years (a six-month-old and a 6.6- and nine-year-old). The six-month-old girl had a short symmetric tonic phase in extension (decerebrate posture), followed by a jittery phase which gave way to prolonged clonic jerking that was asynchronous. This seizure was not followed by postictal EEG suppression. The semiology of this seizure resembled typical GTC seizure evolution, however, the tonic phase was very short (three seconds) and there was no postictal EEG suppression. We noticed that GTC seizures in adults had a longer tonic phase and postictal suppression compared to those in the paediatric population. This data has been previously published by Freitas *et al.* (2013) who found that the major differences in GTC seizures between the paediatric and adult population were a shorter total seizure duration, a shorter tonic phase, and postictal suppression with a relatively fast recovery

phase. We observed that generalized tonic seizures lasted from five to 30 seconds, and that EEG suppression was infrequent after generalized tonic seizures in our patient population. In addition, generalized clonic seizures in our population lasted from three seconds to 30 seconds and EEG suppression was not seen after generalized clonic seizures. This suggests that postictal suppression is the result of typical GTC evolution, and that the tonic and clonic phases are crucial, but not sufficient to generate postictal EEG suppression.

In this study, generalized myoclonic seizures were seen in both the paediatric and adult population. Generalized myoclonic seizures were most frequently seen in patients three to six years of age and the most frequent EZ was generalized.

Hypomotor seizures are characterized by a decrease or arrest of behavioural activity in patients in whom it is not possible to test awareness during a seizure or check for postictal amnesia. By definition, they occur only in newborns, infants, or patients with severe cognitive impairment (Acharya *et al.*, 1997; Lüders *et al.*, 1998). Hypomotor seizures can be seen in generalized or focal epilepsy (Hamer *et al.*, 1999). In a retrospective review of 110 hypomotor seizures recorded from 34 patients, aged one day to 15 years, it was found that 64% of the seizures had a focal onset (over temporal or parietal regions) and that 35% had a generalized onset (Kallen *et al.*, 2002). In this study, 50% of the patients with hypomotor seizures had a focal EZ, mostly localized to the posterior quadrant. Hypomotor seizures were most frequent in patients aged one month to three years. When hypomotor seizures were seen in patients older than three years, the most likely EZ was generalized.

For dialeptic seizures, the predominant ictal symptomatology is an alteration of awareness, and the patients are amnesic of the seizures (Lüders *et al.*, 1998). In our study, patients between three and 18 years of age with dialeptic seizures had mostly a generalized EZ (72%). In contrast, adults with dialeptic seizures had mostly focal EZs (84%). We did not observe dialeptic seizures in patients younger than three years of age. However, defining dialeptic seizures is not straightforward, and cooperation of the patient is required to define dialeptics, namely assessment of responsiveness during a seizure and amnesia for the event. This assessment is not possible before three years of age, and as mentioned above, most of these patients would be classified with hypomotor seizures.

We did not observe automotor seizures in young patients. In our study, the youngest patient with clear automotor seizures was a 3.7-year-old girl, with most likely temporal lobe epilepsy, who exhibited relatively mild lip smacking (which was clearly different from the patient's interictal behaviour). We also observed that the automatic movements typical of automotor

seizures became more prominent with increasing age, characterized by stronger and faster movements. In a previous study, automotor seizures were found in patients with focal epilepsy, younger than two years of age (Bye and Foo, 1994). However, most studies have reported difficulties in differentiating automatisms from interictal behaviour in young children. Hamer *et al.* studied 296 seizures from 76 patients, aged between one month and three years, and found prominent automatisms in only one patient (Hamer *et al.*, 1999). Acharya *et al.* studied 125 seizures in 23 infants with focal epilepsy and children aged 2-24 months, and again observed some subtle oroalimentary activity during the seizures, which was indistinguishable from the patients' interictal behaviour (Acharya *et al.*, 1997). We agree that automatisms in infants are difficult to distinguish from their normal interictal behaviour. In the paediatric population, automotor seizures have been described to consist of relatively simple oral automatisms, which progressively become more complex with age (Wyllie *et al.*, 1993; Bye and Foo, 1994; Brockhaus and Elger, 1995; Fogarasi *et al.*, 2002; Ray and Kotagal, 2005).

Auras were infrequent and mostly non-specific in patients younger than 10 years of age. No auras were reported by patients younger than five years old. The youngest patient who reported auras was a 5.7-year-old. In patients aged 10 to 18 years, auras were more frequent and elaborate (as for example, psychic auras). These findings are supported by previous studies. Hamer *et al.* reviewed 296 seizures from 76 patients, aged between one month and three years old, and did not find any auras (Hamer *et al.*, 1999). Acharya *et al.* reviewed 125 seizures in 23 infants with focal epilepsy, aged 2-24 months, and detected no auras (Acharya *et al.*, 1997). Dylgjeri *et al.* reviewed 10 patients, aged one to 13 years, with insular epilepsy who had been investigated by stereoelectroencephalography (SEEG), followed by resective surgery, with the purpose of analysing electroclinical correlations. None of the patients had the typical sequence described by Isnard *et al.* (2004) (sensation of laryngeal constriction and paresthesias), and only three patients described subjective manifestations, all of whom were older than seven years of age (Dylgjeri *et al.*, 2014). Fogarasi *et al.* studied 111 seizures from 14 paediatric patients with frontal lobe epilepsy; only one six-year-old reported an aura (Fogarasi *et al.*, 2001). The age of this patient is similar to that of our youngest patient who reported auras (a 5.7-year-old). In a group of 15 children with temporal lobe epilepsy, two patients (2.5 and five years of age) reported somatosensory auras, but no further description about the nature of the symptom, timing, or localization was given (Fogarasi *et al.*, 2002). A different study by Fogarasi *et al.* evaluated 110 seizures from 18 paediatric patients (three to seven years old)

with occipital lobe epilepsy. The authors found only two patients with auras, but no age was specified. Interestingly, these auras were not visual, but characterized by nausea and headache. All 18 patients exhibited oculomotor features, most frequently nystagmus (Fogarasi *et al.*, 2003). Wyllie *et al.* did not find any aura among 18 patients with temporal lobe epilepsy younger than five years of age (Wyllie *et al.*, 1993). The failure of young patients' ability to report auras may be related to immature expressive language and a difficulty in understanding that a particular sensation may be "abnormal" in the relatively older group (>three years old).

Only lateral head movements that are forced, unnatural, and sustained should be classified as versive seizures (Wyllie *et al.*, 1986; Lüders *et al.*, 1998). Hamer *et al.* studied seizure semiology in 76 patients, aged one month to three years; the authors found that most of the head turn and eye deviation movements were not extreme or sustained, and only versive seizures were identified in five patients. These versive seizures, which meet the above criteria, were contralateral to the EZ in four out of five versive seizures (80%). In addition, all focal clonic, focal tonic, and focal myoclonic seizures were contralateral to the EEG seizure patterns (Hamer *et al.*, 1999). Brockhaus *et al.* studied paediatric patients with temporal lobe epilepsy and were unable to find a lateralizing value for head deviations, most probably because they did not apply the criteria specified above. They felt, however, that unilateral motor phenomena, especially clonic movements, were a reliable lateralizing sign for a contralateral epileptogenic focus (Brockhaus and Elger, 1995). Acharya *et al.* reviewed 125 seizures in 23 infants with focal epilepsy, aged 2-24 months, and found that some patients had head turning movements during seizures, but these were not forced, unnatural, and/or sustained (Acharya *et al.*, 1997). We also found that versive seizures are infrequent in children younger than 10 years, but when seen in patients with focal epilepsy, the version was always contralateral to the EZ. We identified only one versive seizure in an infant, a six-month-old girl. In her case, version was forced, unnatural, and sustained, and was contralateral to the EZ. On the other hand, focal tonic or clonic seizures were a frequent lateralizing sign in the paediatric population. This was most frequent in three- to 18-year-olds. When focal tonic or clonic seizures were seen in patients with focal epilepsy, the semiology was consistently contralateral to the EZ across all age groups.

Many patients included in this study had intractable epilepsy, and unfortunately, we were unable to investigate the seizure semiology in less severely affected patients. In addition, we were not able to follow the patients, as many of them had only one admission or multiple admissions within a short period of time.

In conclusion, we report the following observations in seizure semiology with age:

- Auras, automotor seizures, and GTC seizures were extremely infrequent in patients younger than 10 years old. We identified only three patients younger than 10 years with GTC seizures. The youngest patient with an automotor seizure was a 3.7-year-old. The youngest patient with auras was a 5.7-year-old girl.
- Generalized epileptic spasms, generalized tonic seizures, and generalized clonic seizures were infrequent in patients older than 10 years.
- Patients younger than three years exhibited mostly generalized simple motor seizures and hypomotor seizures. In these patients, a clear EZ was more challenging to identify, compared to older patients.
- Seizure semiology in patients older than 10 years was very similar to that in the adult population. Seizures with focal semiology accounted for almost all seizure semiology in the adult population. GTC seizures occurred as secondary generalization in 93% of adult patients. Versive seizures were infrequently seen in patients younger than 10 years of age. □

Supplementary data.

Supplementary figures are available on the www.epilepticdisorders.com website.

Disclosures.

None of the authors have any conflict of interest to declare.

References

- Acharya JN, Wyllie E, Lüders HO, Kotagal P, Lancman M, Coelho M. Seizure symptomatology in infants with localization-related epilepsy. *Neurology* 1997; 48: 189-96.
- Brockhaus A, Elger CE. Complex partial seizures of temporal lobe origin in children of different age groups. *Epilepsia* 1995; 36: 1173-81.
- Bye AM, Foo S. Complex partial seizures in young children. *Epilepsia* 1994; 35: 482-8.
- Duchowny MS. Complex partial seizures of infancy. *Arch Neurol* 1987; 44: 911-4.
- Dylgieri S, Taussig D, Chipaux M, *et al.* Insular and insulo-opercular epilepsy in childhood: An SEEG study. *Seizure* 2014; 23: 300-8.
- Egli M, Mothersill I, O'Kane M, O'Kane F. The axial spasm-the predominant type of drop seizure in patients with secondary generalized epilepsy. *Epilepsia* 1985; 26: 401-15.
- Eriksson KJ, Koivikko MJ. Prevalence, classification, and severity of epilepsy and epileptic syndromes in children. *Epilepsia* 1997; 38: 1275-82.
- Fogarasi A, Janszky J, Faveret E, Pieper T, Tuxhorn I. A detailed analysis of frontal lobe seizure semiology in children younger than 7 years. *Epilepsia* 2001; 42: 80-5.

- Fogarasi A, Jokeit H, Faveret E, Janszky J, Tuxhorn I. The effect of age on seizure semiology in childhood temporal lobe epilepsy. *Epilepsia* 2002; 43: 638-43.
- Fogarasi A, Boesebeck F, Tuxhorn I. A detailed analysis of symptomatic posterior cortex seizure semiology in children younger than seven years. *Epilepsia* 2003; 44: 89-96.
- Franca S, Gupta DK, Rao S, et al. Side-to-side axial movements. *Epileptic Disord* 2014; 16: 1-4.
- Freitas J, Kaur G, Fernandez Baca Vaca G, et al. Age-specific periictal electroclinical features of generalized tonic-clonic seizures and potential risk of sudden unexpected death in epilepsy (SUDEP). *Epilepsy & Behav* 2013; 29: 289-94.
- Gastaut H, Broughton R. *Clinical and Electrographic features, Diagnosis and Treatment of Epileptic seizures*. Springfield Illinois, USA: Charles Thomas Publisher, 1972.
- Gastaut H, Roger J, Ouahchi S, Timsit M, Broughton R. An electro-clinical study of generalized epileptic seizures of tonic expression. *Epilepsia* 1963; 4: 15-44.
- Hamer HM, Wyllie E, Luders HO, Kotagal P, Acharya J. Symptomatology of epileptic seizures in the first three years of life. *Epilepsia* 1999; 40: 837-44.
- Isnard J, Guenot M, Sindou M, Mauguier F. Clinical manifestations of insular lobe seizures: a stereo-electroencephalographic study. *Epilepsia* 2004; 45: 1079-90.
- Kallen K, Wyllie E, Luders HO, Lachhwani D, Kotagal P. Hypomotor seizures in infants and children. *Epilepsia* 2002; 43: 882-8.
- Korff C, Nordli Jr. DR. Do generalized tonic-clonic seizures in infancy exist? *Neurology* 2005; 65: 1750-3.
- Lüders H, Acharya J, Baumgartner C, et al. Semiological seizure classification. *Epilepsia* 1998; 39: 1006-13.
- Lüders H, Najm I, Nair D, Widdess-Walsh D, Bingman W. The epileptogenic zone: general principles. *Epileptic Disord* 2006; 8: S1-9.
- Oller-Daurella L, Oller LF. Partial epilepsy with seizures appearing in the first three years of life. *Epilepsia* 1989; 30: 820-6.
- Patel H, Smith J, Garg B. Focal cerebral pathology presenting as tonic seizures. *J Child Neurol* 2006; 21: 813-6.
- Ray A, Kotagal P. Temporal lobe epilepsy in children: overview of clinical semiology. *Epileptic Disord* 2005; 7: 299-307.
- Rodin E, Smid N, Mason K. The grand mal pattern of Gibbs, Gibbs and Lennox. *Electroencephalogr Clin Neurophysiol* 1976; 40: 401-6.
- Wyllie E, Lüders H, Morris HH, Lesser RP, Dinner DS. The lateralizing significance of versive head and eye movements during epileptic seizures. *Neurology* 1986; 36: 606-11.
- Wyllie E, Chee M, Granstrom ML, et al. Temporal lobe epilepsy in early childhood. *Epilepsia* 1993; 34: 859-68.
- Yamamoto N, Watanabe K, Negoro T, et al. Complex partial seizures in children: ictal manifestations and their relation to clinical course. *Neurology* 1987; 37: 1379-82.