

Gastaut type idiopathic childhood occipital epilepsy

Taissa Ferrari-Marinho¹, Eugenia Fialho Macedo¹,
Rafael Scarpa Costa Neves¹, Livia Vianez Costa¹,
Ivanda SS Tudesco¹, Kelly C Carvalho¹, Henrique Carrete²,
Luis Otavio Caboclo¹, Elza Marcia Yacubian¹,
Ana Paula Hamad¹

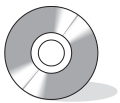¹ Department of Neurology and Neurosurgery

² Department of Imaging Diagnosis, Hospital São Paulo, Universidade Federal de São Paulo, Brazil

Received September 25, 2012; Accepted January 9, 2013

ABSTRACT – Gastaut type idiopathic childhood occipital epilepsy is an uncommon epileptic syndrome characterised by frequent seizures, most commonly presenting as elementary visual hallucinations or blindness. Other occipital (non-visual) symptoms may also occur. Interictal EEG typically shows occipital paroxysms, often with fixation-off sensitivity. Ictal EEG is usually characterised by interruption by paroxysms and sudden appearance of low-voltage, occipital, fast rhythm and/or spikes. Despite well described clinical and EEG patterns, to our knowledge, there are very few reports in the literature with video-EEG recording of either seizure semiology or fixation-off phenomena. We present a video-EEG recording of a 12-year-old girl with Gastaut type epilepsy, illustrating the interictal and ictal aspects of this syndrome. Our aim was to demonstrate the clinical and neurophysiological pattern of a typical seizure of Gastaut type epilepsy, as well as the fixation-off phenomena, in order to further clarify the typical presentation of this syndrome. [*Published with video sequences*]

Key words: idiopathic childhood epilepsy, Gastaut type epilepsy, video-EEG



Correspondence:

Taissa Ferrari Marinho
Unidade de Pesquisa e Tratamento
de Epilepsia (UNIPETE),
Hospital São Paulo,
Departamento de Neurologia
e Neurocirurgia,
Universidade Federal de São Paulo,
Rua Napoleão de Barros, 737, 13º andar,
CEP-04024-002 São Paulo-SP, Brazil
<taissaferrari@yahoo.com.br>

Gastaut type idiopathic childhood occipital epilepsy (G-ICOE) is an age-related epileptic syndrome within the group of idiopathic focal epilepsies in childhood. Age at onset ranges from 3-15 years, with a peak at 8-11 years (Covanis *et al.*, 2005; Panayiotopoulos *et al.*, 2008). G-ICOE is an occipital epilepsy characterised by brief and frequent seizures, most commonly presenting as elementary visual hallucination or blindness. Elementary visual hallucination is the most characteristic ictal symptom. Other

occipital symptoms such as sensory illusions of ocular movement and ocular pain, tonic deviation of the eyes, eyelid fluttering or repetitive eye closure, as well as complex visual hallucination, may also occur. Interictal EEG typically shows occipital paroxysms, often with fixation-off sensitivity (Gastaut, 1982; Gastaut *et al.*, 1992) and sleep activation. Ictal EEG is characterised by interruption by paroxysms and sudden appearance of low-voltage, occipital, fast rhythm and/or fast spikes (Panayiotopoulos, 2010).

Neuropsychological evaluation of patients with G-ICOE discloses lower scores for attention, memory, and intellectual functioning, relative to control subjects, although other basic neurophysiological functions do not differ significantly (Gulgonen *et al.*, 2000).

Our aim was to present a case of G-ICOE with ictal video-EEG documentation in order to further illustrate the clinical and neurophysiological pattern of a typical seizure (Thomas *et al.*, 2003), as well as the fixation-off phenomena based on EEG, and thus contribute to our understanding of the clinical and EEG dimensions of G-ICOE.

Case study

A 12-year-old girl with normal developmental milestones started to present with seizures at age 9. There was no family history of epilepsy. At first, seizures were characterised by elementary visual hallucinations accompanied by headache and vomiting. After two years, she started to experience complex visual hallucinations (of a dog and a wolf), followed by loss of consciousness. She was treated with multiple antiepileptic drugs, which failed to control seizures. Video-EEG recordings showed frequent bilateral occipital sharp waves with eyes closed, which were significantly reduced when eyes were opened (fixation-off sensitivity) (*figure 1 and video sequence 1*). The discharges were activated by sleep. No response to intermittent photic stimulation was seen. The use of glasses, which prevent fixation, activated the epileptiform discharges. A focal-onset seizure lasting for 70 seconds was recorded. Ictal EEG showed low-amplitude, fast rhythm, lasting for two seconds over occipital regions and involving the midline. This activity was followed by spikes and spike-wave complexes at a frequency of 2-3/second, with

a 6-Hz theta rhythm over the left occipital region superimposed by spikes, involving the contralateral homologous region and midline (*figure 2*). Clinically, the patient presented with impairment of awareness and eyelid flutter, related both in time and frequency to the spike-wave discharges, followed by conjugate tonic deviation of the eyes and head to the right, concomitant with the slow, rhythmic, theta activity (*video sequence 2*). Neuroimaging was unremarkable. Neuropsychological evaluation showed cognitive performance within the expected range for age, except for impaired selective attention.

Discussion

Our patient presented with electroclinical features consistent with the diagnosis of G-ICOE. This epileptic syndrome is uncommon, corresponding to 0.2-0.9% of all epilepsies and 2-7% of benign childhood focal seizures (Covanis *et al.*, 2005). Thus, despite well described clinical and EEG patterns, to our knowledge, there are few reports of video-EEG recordings and presentations in the literature of either seizure semiology or fixation-off phenomena.

Seizures of G-ICOE commonly manifest with visual symptoms, such as elementary and complex visual hallucinations, visual illusions, blindness or partial visual loss and sensory hallucinations of ocular movements, and pain (Covanis *et al.*, 2005). Our patient's first seizure symptom was elementary visual hallucinations, which is described as the initial manifestation in more than two thirds of patients reported in the literature (Kivity *et al.*, 2000). This seizure type is usually frequent, brief (lasting for 1-2 minutes), occurs upon awakening, and can be the sole ictal manifestation. Complex visual hallucinations are observed in less than 10% of patients (Gastaut, 1982). Non-visual ictal symptoms of occipital lobe origin, including

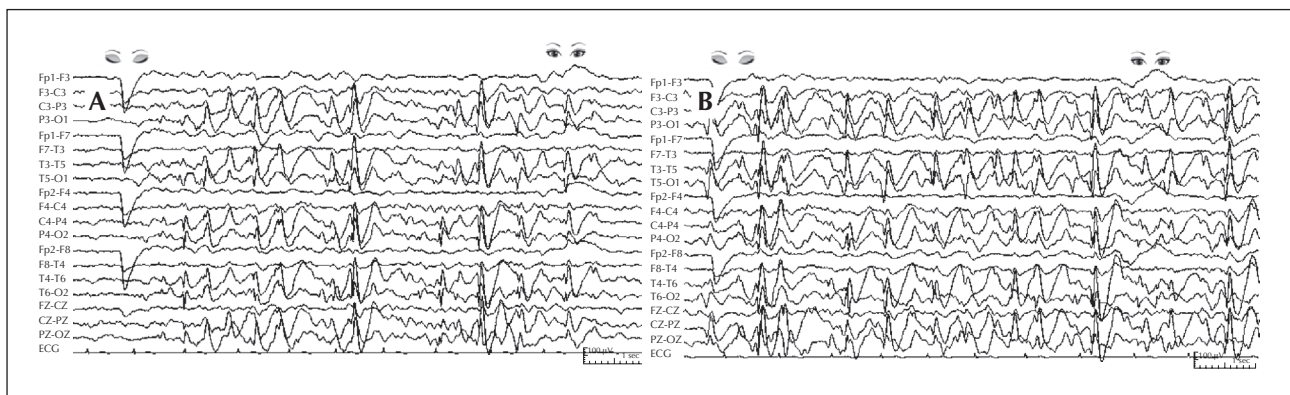


Figure 1. Interictal EEG showing the fixation-off sensitivity. (A) Without glasses. (B) With glasses. Frequent discharges impaired the ability to visualise alpha rhythm.

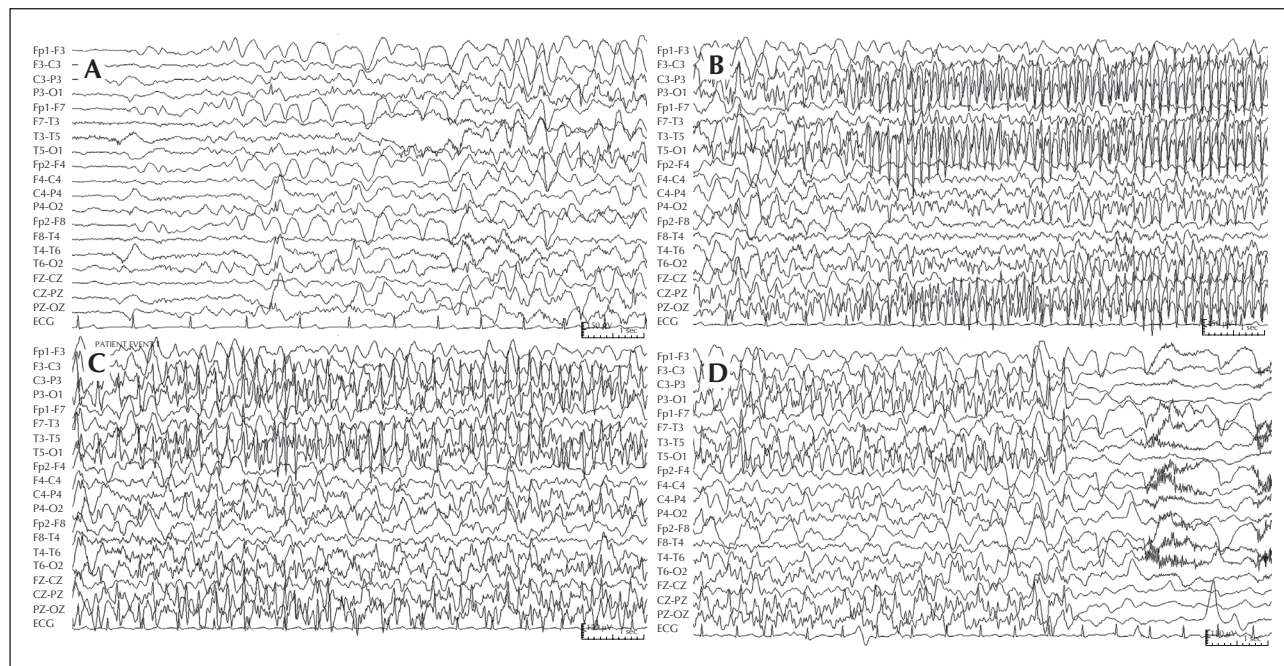


Figure 2. EEG recording showing an electroclinical seizure. (A) Onset of low-amplitude, fast rhythm in the occipital regions followed by spikes and spike-wave complexes at a frequency of 2-3/second. (B and C) 6-Hz theta rhythm over the left occipital region, with superimposed spikes, involving the contralateral homologous region and midline. (D) Abrupt end of the seizure.

deviation of the eyes and forced eyelid closure and eyelid blinking, can also be part of the clinical spectrum of G-ICOE (Caraballo *et al.*, 2008). In this case report, we illustrate a non-visual seizure pattern recorded during a routine video-EEG, emphasizing occipital involvement in this type of epilepsy. In addition, propagation to adjacent areas, manifested by impairment of consciousness, may also occur.

G-ICOE interictal EEG is characterised by occipital sharp-and-slow-wave complexes, which increase as long as fixation and central vision are eliminated, defining the so called “*fixation-off sensitivity*” (Panayiotopoulos, 2010). Despite being a classical feature of this syndrome, fixation-off sensitivity is not pathognomonic of G-ICOE, however, it may be observed in another idiopathic focal epileptic syndrome in childhood, Panayiotopoulos syndrome (PS), or even in symptomatic occipital epilepsies (Panayiotopoulos, 2010). We have illustrated this characteristic phenomenon using EEG and video recordings in the case presented in order to further clarify the diagnosis of G-ICOE when supported by clinical data.

Due to some overlapping features, the differential diagnosis of G-ICOE and PS may pose a challenge to the clinician. The duration of seizure, which is brief in G-ICOE and long in PS, is probably the most important difference. The seizure presented in this report, which lasted 70 seconds, is consistent with the diagnosis of

G-ICOE. Regarding ictal clinical semiology, autonomic manifestations constitute the most frequent seizure pattern in PS, whereas visual symptoms are the most typical seizure onset manifestations in G-ICOE. On the other hand, non-visual seizures, including tonic deviation and impairment of consciousness, as presented in this case, although less frequent in G-ICOE, are also described in this syndrome.

Since there is no need for repeated or long-term EEG monitoring for the diagnosis of idiopathic focal epilepsies in childhood, ictal EEGs have been very rarely recorded for these syndromes. The video-EEG shown in this article highlights the semiological aspects of this seizure type. Moreover, it demonstrates how important it is to record routine EEGs with video (Connolly *et al.*, 1994). In the literature, the ictal EEG pattern is well known, characterised by the disappearance of occipital paroxysms, followed by development of fast rhythms and/or fast spikes, including irregular bilateral spike-waves (Beaumanoir, 1993; Covanis *et al.*, 2005; Caraballo *et al.*, 2008). In our case, we have documented a previously undescribed ictal pattern; theta ictal activity during the tonic eye deviation phase, in addition to fast rhythm and spike-waves.

Beyond the seizures, our patient showed lower scores in attention tests. G-ICOE, like idiopathic syndromes, affects children with normal development. Nevertheless, lower performance scores in attention and memory, as well as in intellectual functioning, have

been reported (Gulgonen *et al.*, 2000). The possibility of subtle cognitive deficits should always be considered in G-ICOE.

Considering the low performance in neuropsychological tests and unclear prognosis regarding seizure remission, the use of the term “benign” for this syndrome may not be appropriate (Berg *et al.*, 2010). After two to four years following onset, 50-60% of patients become seizure-free (Panayiotopoulos *et al.*, 2008; Caraballo *et al.*, 2008) and an excellent response to AED is seen in 90% of patients. Nevertheless, 40-50% of patients may continue to have visual seizures (Panayiotopoulos *et al.*, 2008). Our patient persisted with seizures despite treatment with multiple antiepileptic drugs, which is often the case.

Distinguishing between G-ICOE and symptomatic occipital epilepsy can be difficult, particularly when children are otherwise normal; brain magnetic resonance imaging (MRI) is used to exclude symptomatic occipital epilepsy (Ferrie *et al.*, 1997).

To the best of our knowledge, recording of non-visual seizures and fixation-off phenomenon in G-ICOE documented by VEEG has rarely been reported. The current report may provide useful didactic information in order to recognise the typical presentation of this syndrome. □

Disclosures.

None of the authors has any conflict of interest to disclose.

Legends for video sequences

Video sequence 1

Interictal EEG showing the fixation-off sensitivity, both without glasses and with glasses.

Video sequence 2

The patient showing a focal seizure characterised by impairment of awareness and eyelid flutter, followed by conjugate tonic deviation of the eyes and head to the right

Key words for video research on

www.epilepticdisorders.com

Syndrome: late onset childhood occipital epilepsy (gastaut type)

Etiology: idiopathic

Phenomenology: eye deviation; hallucinations (visual)

Localization: not applicable

References

- Beaumanoir A. Semiology of occipital seizures in infants and children. In: Andermann F, Beaumanoir A, Mira L, Roger J, Tassinari CA. *Occipital seizures and epilepsies in children*. London: John Libbey, 1993: 71-86.
- Berg AT, Berkovic SF, Brodie MJ, *et al.* Revised terminology and concepts for organization of seizures and epilepsies: Report of the ILAE Commission on Classification and Terminology, 2005-2009. *Epilepsia* 2010; 51: 676-85.
- Caraballo RH, Cersosimo RO, Fejerman N. Childhood occipital epilepsy of Gastaut: a study of 33 patients. *Epilepsia* 2008; 49: 288-97.
- Connolly MB, Wong PK, Karim Y, Smith S, Farrell K. Outpatient video-EEG monitoring in children. *Epilepsia* 1994; 35: 477-81.
- Covanis A, Ferrie CD, Koutroumanidis M, Oguni H, Panayiotopoulos K. Panayiotopoulos syndrome and Gastaut type idiopathic childhood occipital epilepsy. In: Roger J, Bureau M, Dravet C, Genton P, Tassinari CA, Wolf P. *Epileptic syndromes in Infancy, childhood and adolescence*. Montrouge (France): John Libbey Eurotext, 2005: 227-54.
- Ferrie CD, Beaumanoir A, Guerrini R, *et al.* Early-onset benign occipital seizure susceptibility syndrome. *Epilepsia* 1997; 38: 285-93.
- Gastaut H. A new type of epilepsy: benign partial epilepsy of childhood with occipital spikes-waves. *Clin Electroencephalogr* 1982; 13: 13-22.
- Gastaut H, Roger J, Bureau M. Benign epilepsy of childhood with occipital paroxysms up-date. In: Roger J, Bureau M, Dravet C, Dreiffus FE, Perret A, Wolf P. *Epileptic syndromes in infancy, childhood and adolescence*. London: John Libbey, 1992; 201-17.
- Gulgonen S, Demirbilek V, Korkmaz B, Dervent A, Townes BD. Neuropsychological functions in idiopathic occipital lobe epilepsy. *Epilepsia* 2000; 41: 405-11.
- Kivity S, Ephraim T, Weitz R, Tamir A. Childhood epilepsy with occipital paroxysms: clinical variants in 134 patients. *Epilepsia* 2000; 41: 1522-33.
- Panayiotopoulos CP. Benign childhood focal seizures and related epileptic syndromes. In: Panayiotopoulos CP. *A clinical guide to epileptic syndromes and their treatments*. London: Springer Healthcare Ltd, 2010: 339-76.
- Panayiotopoulos CP, Michael M, Sanders S, Valeta T, Koutroumanidis M. Benign childhood focal epilepsies: assessment of established and newly recognized syndromes. *Brain* 2008; 131: 2264-86.
- Thomas P, Arzimanoglou A, Aicardi J. Benign idiopathic occipital epilepsy: report of a case of the late (Gastaut) type [corrected]. *Epileptic Disord* 2003; 5: 57-9. Erratum in: *Epileptic Disord* 2003; 5: 169.