

Ictal asystole mimicking seizure deterioration in temporal lobe epilepsy

Baburhan Guldiken^{1,2}, Elisabeth Hartl¹, Jan Rémi¹, Soheyl Noachtar¹

¹Epilepsy Center, Department of Neurology, University of Munich, Munich, Germany

²Department of Neurology, Medical Faculty of Trakya University, Edirne, Turkey

Received February 27, 2015; Accepted May 02, 2015

ABSTRACT – We report on a patient with temporal lobe epilepsy, secondary to a left lateral temporal cavernoma, in whom the change in seizure semiology suggested recurrence of secondary generalized seizures. Anticonvulsive medication previously controlled secondary generalized seizures over a period of years but focal seizures continued at a lower rate. Continuous video-EEG monitoring revealed ictal asystole associated with myoclonic syncope and falls during focal seizures arising from the left temporal lobe. After implantation of a cardiac pacemaker, no more falls occurred during the focal seizures. In conclusion, recurrence of seizure-associated falls is typically attributed to recurrence of secondary generalized seizures, however, ictal asystole should be considered in selected epilepsy patients as a differential diagnosis of falls. [*Published with video sequence*]

Key words: ictal asystole, syncope, seizure-associated fall

Recurrence of seizure-related falls in chronic focal epileptic patients, in whom epileptic falls were previously controlled with anticonvulsive medication, is usually attributed to recurrence of generalized convulsive seizures. In this report, we present a patient with temporal lobe epilepsy (TLE) in whom video-EEG monitoring revealed an ictal asystole as the cause of myoclonic syncope during seizures arising from the left temporal lobe.

Case study

This 45-year-old woman had had epileptic seizures since the age of 13 years. Her seizures were heralded

by non-specific auras which were followed by blank staring, inability to speak, and loss of responsiveness (dialeptic seizures) (Lüders *et al.*, 1998). Rarely, generalized convulsions occurred. Her seizures were secondary to a cavernoma in the left mesial temporal gyrus, as documented by magnetic resonance imaging. Auras and dialeptic seizures continued despite lesionectomy of the cavernoma and anticonvulsant medication. One year after surgery, her family described recurrence of falls and cramps with loss of consciousness despite unchanged medication of 2,000 mg levetiracetam and 300 mg lamotrigine.



Correspondence:

Soheyl Noachtar
Epilepsy Center,
Dept. of Neurology,
University of Munich,
Marchioninstr. 15,
D-81377 Munich, Germany
<noa@med.uni-muenchen.de>

During continuous EEG monitoring, all interictal epileptiform discharges were recorded in the left temporal region. All of the six recorded habitual seizures arose from the left mesial temporal region. Asystoles were recorded during four of these seizures (figure 1). During asystole, her head dropped (while lying in bed) and she had several myoclonic jerks of the trunk and limbs. The asystole lasted from 22 to 35 seconds. The patient regained consciousness shortly after recurrence of normal cardiac rhythm.

The recording demonstrated that the head drop and jerks, and most likely the falls, are secondary to the ictal asystole, leading to syncope. After a pacemaker was implanted, she did not fall anymore during her seizures. Left anterior temporal lobe resection, two years after the implantation of the pacemaker, has now led to complete seizure control for more than two years.

Discussion

Recurrence of seizure-related falls may not necessarily be related to a recurrence of generalized convulsions, but may be secondary to ictal asystole, as demonstrated by our patient. Typically, anticonvulsant medication is more effective in controlling secondary generalized convulsions than focal seizures in patients with TLE (Mattson *et al.*, 1992). The recurrence of falls in patients in whom only focal seizures without falls persist for a long period of time usually leads to the assumption that generalized convulsions reoccur. This typically leads to an adjustment of the anticonvulsant medication. However, video-EEG monitoring in our patient revealed ictal asystole and demonstrated that the atonic falls were most likely not the result of seizure generalization, but were due to ictal syncope. Myoclonic jerks during syncope

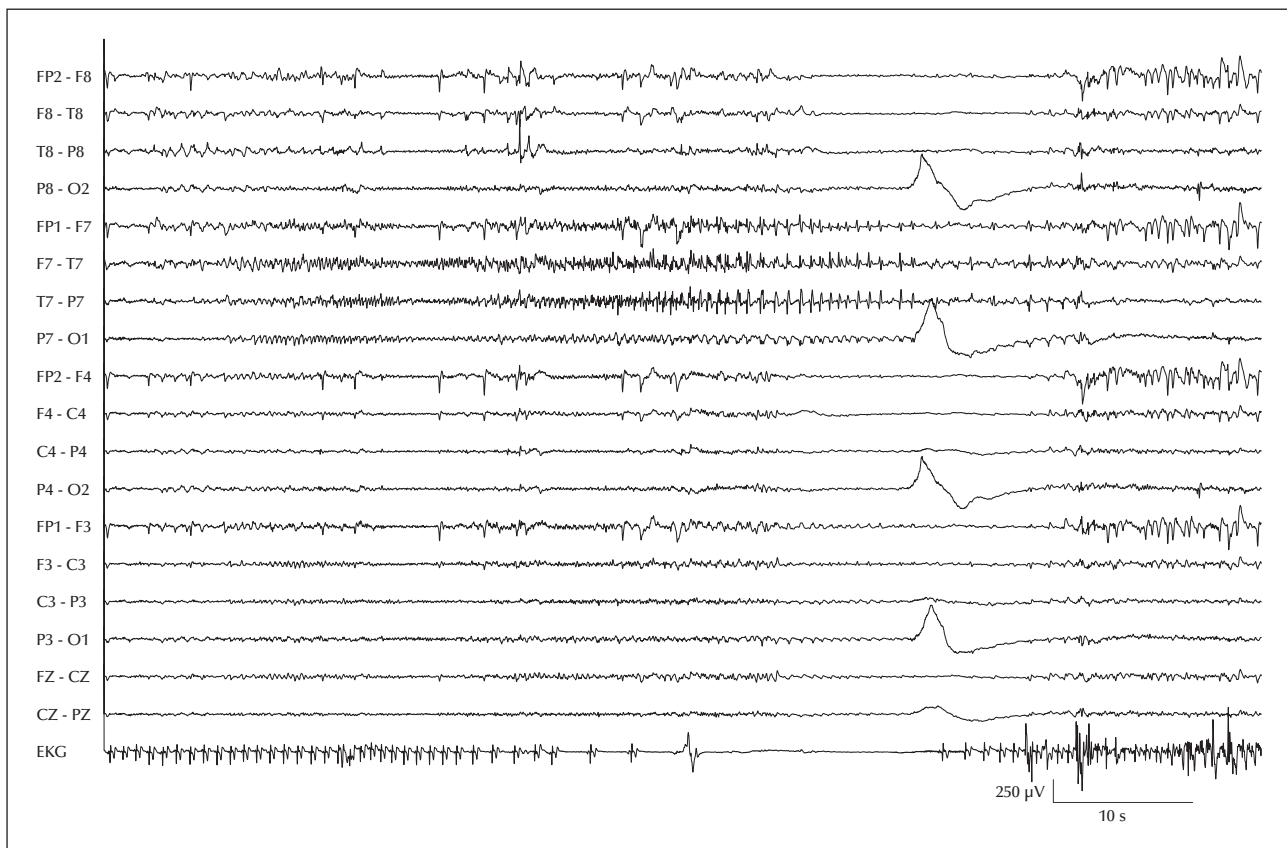


Figure 1. This bipolar longitudinal EEG shows a left temporal EEG seizure pattern during a seizure characterized by blank staring and loss of consciousness, which is followed by an ictal asystole lasting 22 seconds. During the asystole, the patient's head dropped and she developed myoclonic jerks of the trunk and the limbs.

are very common and may easily be misinterpreted as generalized convulsions (Lempert *et al.*, 1994).

Video-EEG monitoring established the correct diagnosis and prompted the implantation of the pacemaker. The patient did not wish to have resective epilepsy surgery at that time. Two years later, she agreed to epilepsy surgery, which eventually led to seizure freedom. One might consider that earlier epilepsy surgery might have abolished the need for the pacemaker, but the patient was not willing to have epilepsy surgery at that time, and the pacemaker reduced her seizure and syncope-related risks. Implantation of cardiac pacemakers has been shown to prevent further falls and related lacerations in patients with ictal syncope (Moseley *et al.*, 2011). Strzelczyk *et al.* (2011) reported two patients with drug-resistant epilepsy who refused pacemaker implantation as well as epilepsy surgery and continued to have recurrent seizures with falls and trauma.

The relation of ictal asystole to sudden unexpected death in epileptic patients (SUDEP) is yet unclear. No clear association could be shown in risk analyses of SUDEP and in the SUDEP patients observed during video-EEG monitoring (Nilsson *et al.*, 1999; So *et al.*, 2000).

We previously reported a similar female patient, in whom an event recorder demonstrated that her falls were associated with asystole. Implantation of a pacemaker abolished the falls but unmasked TLE, documented by video-EEG monitoring (Rémi and Noachtar, 2011). In this patient, anticonvulsant medication controlled her seizures.

In conclusion, when seizure-related falls reoccur in patients with focal epilepsies, one should consider ictal asystole leading to syncope during epileptic seizures. Video-EEG monitoring can resolve this issue. □

Supplementary data.

Summary didactic slides are available on the www.epilepticdisorders.com website.

Disclosures.

None of the authors have any conflicts of interest to declare.

Legend for video sequence

Video showing a dialeptic seizure followed by ictal asystole, unresponsiveness, and bilateral myoclonic jerks. The patient's responsiveness was not tested during this seizure. She did not respond during an identical seizure with milder myoclonic jerks.

Keywords for research on
www.epilepticdisorders.com

Syndrome: focal non-idiopathic temporal (TLE)

Etiology: syncope (cardiac)

Phenomenology: atonic seizure (drop attack)

Localization: temporal lobe (left)

References

- Lempert T, Bauer M, Schmidt D. Syncope: a videometric analysis of 56 episodes of transient cerebral hypoxia. *Ann Neurol* 1994; 36(2): 233-7.
- Lüders H, Acharya J, Baumgartner C, *et al.* Semiological seizure classification. *Epilepsia* 1998; 39(9): 1006-13.
- Mattson RH, Cramer JA, Collins JF. A comparison of valproate with carbamazepine for the treatment of complex partial seizures and secondarily generalized tonic-clonic seizures in adults. The Department of Veterans Affairs Epilepsy Cooperative Study No. 264 Group. *N Engl J Med* 1992; 327(11): 765-71.
- Moseley BD, Ghearing GR, Munger TM, Britton JW. The treatment of ictal asystole with cardiac pacing. *Epilepsia* 2011; 52(4): e16-9.
- Nilsson L, Farahmand BY, Persson PG, Thiblin I, Tomson T. Risk factors for sudden unexpected death in epilepsy: a case-control study. *Lancet* 1999; 353(9156): 888-93.
- Rémi J, Noachtar S. Seizure, syncope, or both: cardiac pacemaker reveals temporal lobe epilepsy. *J Neurol* 2011; 258(12): 2291-2.
- So EL, Sam MC, Lagerlund TL. Postictal central apnea as a cause of SUDEP: evidence from near-SUDEP incident. *Epilepsia* 2000; 41(11): 1494-7.
- Strzelczyk A, Cenusa M, Bauer S, *et al.* Management and long-term outcome in patients presenting with ictal asystole or bradycardia. *Epilepsia* 2011; 52: 1160-7.

TEST YOURSELF

An epileptic patient known to suffer from rare focal epileptic seizures due to temporal cavernoma describes recurrence of falls with loss of consciousness and jerks of the entire body. The patient's antiepileptic medication previously controlled secondary generalized seizures over a period of years.

(1) What would be your diagnosis?

- A. Secondary generalized seizure
- B. Atonic seizure
- C. Ictal asystole
- D. Myoclonic seizure

(2) How would you evaluate the patient?

- A. Frequent controls at the outpatient clinic
- B. Cardiac monitoring
- C. Video-EEG monitoring
- D. Magnetic resonance imaging of the brain

(3) What treatment would you suggest?

- A. Cardiac pacemaker and epilepsy surgery
- B. Addition of a new antiepileptic drug
- C. Vagal nerve stimulation
- D. Anti-arrhythmic drugs

Note: Reading the manuscript provides an answer to all questions. Correct answers may be accessed on the website, www.epilepticdisorders.com, under the section "The EpiCentre".