

Kinesigenic reflex epilepsy associated with a glioma in the lateral peri-rolandic region

Romy Hoque¹, Edouardo Gonzalez-Toledo^{1,2}, Elena Korniychuk¹, John DellaBadia¹, Stephen L. Jaffe¹

¹ Department of Neurology

² Department of Radiology, Louisiana State University School of Medicine, Shreveport, LA, USA

Received June 20, 2008; Accepted January 26, 2009

ABSTRACT – A patient with kinesigenic focal motor seizures induced by tongue-jaw movement had a grade III astrocytoma clearly co-localizing with the epileptic network in the appropriate peri-rolandic, motor-sensory, lingual-jaw cortical area. The clinical seizure phenomena were time-locked with the EEG epileptic activity. [Published with video sequences]

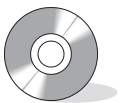Key words: kinesigenic reflex epilepsy, peri-rolandic epileptic network, video/EEG

Reflex epilepsies are characterized by seizures induced by a specific temporally associated sensory trigger. They are classified according to the stimuli that trigger them such as visual patterns, lights, sounds, tastes, odors, and movement associated proprioception (Ferlazzo *et al.* 2005). Kinesigenic seizures (*i.e.* seizures induced by movement) produced by chewing/eating were originally described by Ahuja *et al.* (1988). Rarely have reported cases demonstrated clear EEG-neuroimaging correlation. We report a patient with kinesigenic seizures time-locked to the EEG epileptic activity, having a grade III astrocytoma that co-localized with the EEG epileptic network in the appropriate peri-rolandic, lingual-jaw homuncular cortical area.

Case Study

A 67 year old right handed white male with no significant past medical history presented with a single generalized seizure, and then developed simple partial seizures consisting of tonic and then clonic activity of the tongue and jaw to the right.

These partial seizures were occasionally spontaneous but usually elicited by talking, the chewing component of eating, and rapid, side-to-side voluntary tongue movements. Although dysarthria occurred during the partial seizures, aphasia did not. There was no alteration of awareness. The patient had a normal general physical and neurological examination. MRI of the brain revealed a 2 cm diameter mass lesion in the left lateral peri-rolandic cortex (*figure 1*). Biopsy revealed a grade III astrocytoma that



Correspondence:

R. Hoque, M.D.
Department of Neurology,
Louisiana State University School
of Medicine,
Shreveport, LA, 71103, USA
<romy.hoque@gmail.com>

Presented in part at the meeting of the American Clinical Neurophysiology Society, February, 2008.

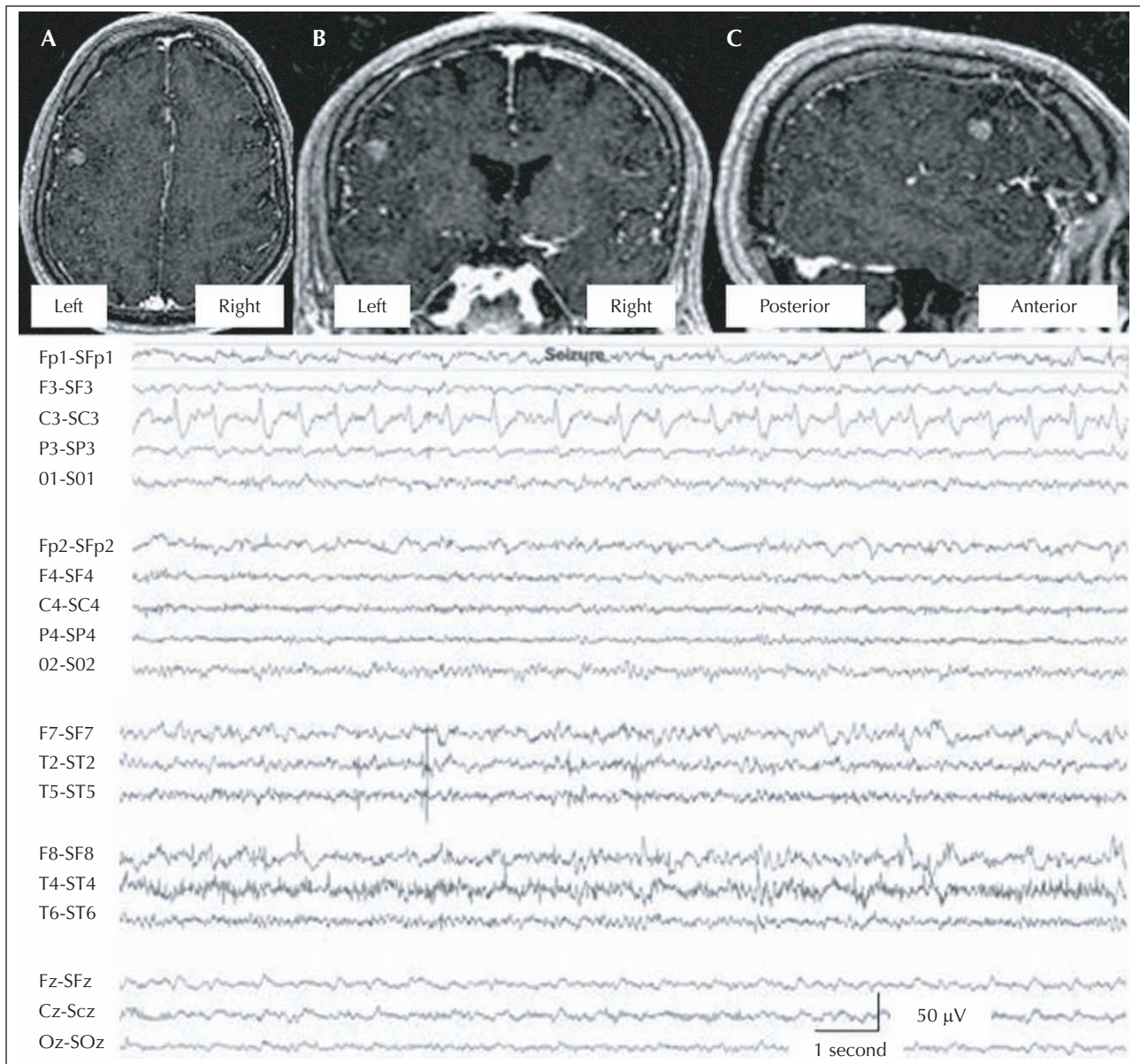


Figure 1. MRI T1-weighted SPGR (spoiled gradient echo) sequences co-localizing the mass lesion with the EEG epileptic network. **A)** Axial. **B)** Coronal. **C)** Sagittal. MRI shows a grade III astrocytoma in the left peri-rolandic cortex. EEG is in the Laplacian montage. Sensitivity: 7.0 $\mu\text{V}/\text{mm}$. Paper speed: 30 mm/second. High frequency filter: 70 Hz. Low frequency filter: 1 Hz. 60-Hz filter: off. Epileptiform discharge co-localizes with the mass lesion under the C3 electrode.

was treated with radiation and chemotherapy. Generalized tonic-clonic seizures did not recur after phenytoin initiation, but phenytoin did not effectively control the simple partial seizures. Phenytoin was replaced by levetiracetam to avoid anticonvulsant interaction with the chemotherapeutic agents. The simple partial seizures increased after radiation and chemotherapy were completed. Levetiracetam was replaced with extended release carbamazepine with excellent seizure control.

Video-EEG monitoring revealed rhythmic 10 Hz activity that evolved into rhythmic theta activity with accompanying spikes, correlating with tonic followed by clonic activity of the tongue and jaw (see *video sequence*). The rhythmic epileptiform discharge localized to the left paracentral head region, maximal at the C3 electrode (*figure 1*). Occasional theta activity was seen interictally in this area, but no other EEG abnormalities were noted.

Discussion

Kinesigenic seizures are rare and have been reported to be evoked by active or passive movements. In our case, the co-localization of the left lateral peri-rolandic, cortical astrocytoma with the left paracentral epileptiform discharge suggests that local area network disruption by the tumor enabled the cortical hyperexcitability. Further mechanistic evidence is provided by the time-locked nature of the epileptiform discharge to the tonic and then clonic tongue and jaw movements to the right (Lopes da Silva *et al.* 2003).

With our present data, it is not possible to definitively determine whether the proprioceptive sensory input to the motor area, or the voluntary motor activation via praxis circuitry input induced the cortical motor neuron hyperexcitation resulting in the simple partial seizures. But a monkey model of kinesigenic reflex epilepsy with a passive proprioceptive trigger has been reported (Xue and Ritaccio 2006). In one study of eating epilepsy, 98% appeared triggered only by mastication activity (Koul *et al.* 1989), and the integrated "automatic" motor activities of talking and chewing, which also induced seizures in our patient, probably bypass the voluntary ideomotor praxis areas. All these factors implicate the proprioceptive circuitry input as being the necessary component of the seizure triggering mechanism in our case.

Eating epilepsies, which involve chewing/swallowing movements and therefore can be categorized as movement induced or kinesigenic seizures, have been infrequently reported, but appear more prevalent in the central Asian population (Ahuja *et al.* 1988, Remillard *et al.* 1998, Senevirutane 2005). In the Sri Lanka studies, eating induced epilepsy was the most common type of reflex epilepsy and manifested as both partial and generalized seizures. Although focal and generalized epileptic discharges were recorded interictally, none of these eating epilepsy case series were able to record an actual seizure induced by eating or by voluntary lingual-jaw movement. In contrast to our case, neuroimaging (computerized tomography) did not localize the cortical area primarily involved.

Moreover, previously reported cases not only involved signs of peri-rolandic, suprasylvian dysfunction, but were associated with more diffuse lesions clinically demon-

strating a fixed hemiparesis and/or an intellectual deficit. Thus in these cases, even the taste appreciation pathways in the limbic system could have contained the primary epileptic network. In contrast, our patient had a very circumscribed, peri-rolandic lesion without a fixed neurological deficit. The circumscribed neuroimaging focus, the focal electrographic discharge and the short latency between the provocative tongue maneuver and the clinical/electroencephalographic seizure very strongly suggest an epileptic network primarily involving the large tongue-jaw representation in the motor-sensory peri-rolandic cortex. □

Legend for video sequence

Demonstrates patient self-inducing seizure by tongue and jaw movements, mental status remains normal as seizure occurs. This is followed by video-EEG demonstrating cortical epileptic localization correlating with clinical seizure activity.

References

- Ahuja GK, Pauranik A, Behari M, Prasad K. Eating epilepsy. *J Neurol* 1988; 235: 444-7.
- Ferlazzo E, Zifkin BG, Andermann E, Andermann F. Cortical triggers in generalized reflex seizures and epilepsies. *Brain* 2005; 128: 700-10.
- Koul R, Koul S, Razdan S. Eating epilepsy. *Acta Neurol Scand* 1989; 80: 78-80.
- Lopes da Silva FH, Blanes W. Dynamical diseases of brain systems: different routes to epileptic seizures. *IEEE Trans Biomed Eng* 2003; 50: 540-8.
- Remillard GM, Zifkin BG, Andermann F. Seizures induced by eating. *Adv Neurol* 1998; 75: 227-40.
- Senevirutane U. Reflex epilepsies; clinical and demographic characteristics in a tropical country. *J Clin Neurosci* 2005; 12: 767-9.
- Xue LY, Ritaccio AL. Reflex seizures and reflex epilepsy. *Am J END Technol* 2006; 46: 39-48.