

Late-onset epilepsy in a surgically-treated Sturge-Weber patient

Julia Jacobs, Pierre LeVan, André Olivier, Frederick Andermann, François Dubeau

Montreal Neurological Institute, Canada

Received August 3, 2008; Accepted October 5, 2008

ABSTRACT – Sturge-Weber syndrome is a rare, congenital, neurocutaneous disorder. It can be associated with a variety of symptoms including severe epilepsy. Patients often become symptomatic during childhood and the severity of the epilepsy correlates with the patient's neurological outcome. The patient reported here remained asymptomatic until age 24, when he started to experience migraine accompanied by visual scotoma and hemiparesis. Ten years later, he developed severe, refractory epilepsy, with prolonged postictal neurological deficits and ictal as well as post-ictal headaches. It became increasingly difficult to distinguish between migraines and seizures as both could last for several hours, as demonstrated in the two video EEGs. Both the epilepsy and the migraine may therefore have contributed to the patient's severe, neurological deterioration, probably by accelerating the progressive neuronal damage. Surgery improved the situation, but lesional areas were too extensive for complete removal. Late-onset symptoms in Sturge-Weber syndrome may thus result in a severe course for the disease. Early intervention and surgical treatment options are discussed. [*Published with video sequences*]

Key words: Sturge-Weber, intractable epilepsy, migraine, surgical treatment

Sturge-Weber syndrome (SWS) is a nonhereditary, congenital, neurocutaneous disorder, which occurs in one of 50 000 live births. It is characterized by a facial port-wine stain, which follows the distribution of the trigeminal nerve, and by leptomeningeal angiomatosis. This is most often unilateral and involves the occipital or posterior parietal lobes (Comi 2003). The neurological symptoms in SWS are the result of the necrotic and gliotic changes underlying the leptomeningeal angioma. These may be diverse, the most common being epilepsy, migraine, contra-lateral hemiparesis and hemianopsia, as well as progressive

mental deterioration (Di Rocco and Tamburrini 2006).

Seizures usually start early in life, and are often intractable to medication (Sujansky and Conradi, 1995b). In addition to the vascular malformation, seizures in the developing brain of patients with SWS may cause additional, permanent damage, explaining the progressive functional and cognitive deficits.

Epilepsy surgery has been proven to be successful in those patients with refractory focal seizures (Arzimanoglou *et al.* 2000, Sujansky and Conradi 1995a, Tuxhorn and Pannek 2002). Removal of the entire lesion



Correspondence:

J. Jacobs, MD
Montreal Neurological Institute,
EEG-Department, 3801 University Street,
Montreal, Quebec, H3A2B4, Canada
<julia.jacobs@gmx.de>

resulted in seizure freedom in all patients described by Arzimanoglou *et al.* (2000). However, as the lesion is most commonly located in the occipital-parietal areas, resections are often limited in attempts to spare the visual field. The timing of surgery has also been a matter of debate, some authors favouring early surgery, even at epilepsy-onset, in order to prevent irreversible tissue damage and deficits (Hoffman 1997).

Approximately 40% of patients with SWS and epilepsy report migraine headaches, and in half of them the latter are a more persistent and disabling problem compared to the seizures (Kossoff *et al.* 2005). In many patients, the migraine attacks consist of a severe, prolonged, unilateral headache with autonomic symptoms, transient neurological deficits such as hemiparesis, and visual scotomas (Arzimanoglou *et al.* 2000, Lisotto *et al.* 2004). In patients who experience increasing or prolonged neurological deficits, it can be difficult to distinguish between migraine, ictal and postictal manifestations, and even ischemic events (Jansen *et al.* 2004, Thomas-Sohl *et al.* 2004).

We present a patient with SWS and late-onset migraine and epilepsy, and discuss the difficult differential diagnosis between migraine attacks and seizures, and their mechanisms.

Case report

We present a 41-year-old man, who was first diagnosed with seizures at age 35. He was born after an uneventful pregnancy, at term, to non-consanguineous parents. He had normal developmental milestones, finished high school as an average student and trained as a mechanic. There was no family history of epilepsy, migraine or any other neurological disorder.

At age 24, he presented for the first time with headaches, later diagnosed as “*migraine accompagnée*”. During these episodes, he typically experienced a tingling sensation in the left toes and leg, sometimes accompanied by weakness of the left hemibody and visual phenomena such as flashes, multicoloured lights and scotomas. These episodes usually lasted between 30 minutes and two hours, and were followed by a severe, unilateral, pulsating headache with nausea and vomiting. He had a discrete port-wine stain on the right forehead and typical MRI findings consisting of right posterior-parietal and occipital atrophy, enhanced vascular areas in the mesial aspect of the parietal and occipital lobes, consistent with pial angiomatosis, and an enlarged right choroid plexus (*figure 1*). Physical and neurological examinations were otherwise normal. As shown in *figure 2*, the severity and frequency of the patient’s migraine attacks increased over the years.

Ten years after the first migraine attack, the patient presented with the first recognized seizure, consisting of an aura of flashing lights, loss of consciousness and a left hemibody convulsion. Seizure frequency rapidly

increased and despite several antiepileptic drugs, he also experienced several episodes of focal status epilepticus. Typically, the epileptic attacks consisted of simple, visual hallucinations such as flashing, multi-coloured lights and scotoma, lasting for several hours at a time, and interpreted as aura continua. These episodes were sometimes accompanied by headache, and it became increasingly more difficult for the patient to differentiate between migraine symptoms and seizures. His situation deteriorated to a point where he was consistently afraid of light, so wore sunglasses, and had to drop out of work.

His first interictal scalp EEGs were normal, but later, interictal epileptiform abnormalities in the right posterior quadrant with maximum at T6, O2, and P10 were described. During his first prolonged EEG monitoring, nine pure electrographic and four clinical-EEG seizures consisting of rhythmic, small amplitude sharp waves were recorded over the right posterior quadrant. In each clinical event, the patient reported a visual aura, followed by a brief period of confusion and sometimes clonic movements of the left arm. After a prolonged electrographic seizure of 10 minutes duration, the patient experienced visual symptoms, numbness of the left hemibody and a severe, unilateral headache consistent with a typical migraine attack, which lasted for several hours. At the same time, the EEG showed continuous, bilateral posterior-parietal and occipital slow-wave activity (*see video sequence 1*).

Because of the rapid progression and refractoriness of the disease, and as the visual field was intact at baseline (repeated visual field examinations revealed inconsistent, non-persistent, left homonymous hemianopsia), the patient underwent an intracerebral EEG evaluation. Four intracranial electrodes were inserted exploring the temporal (amygdala, hippocampus and overlying neocortex) and occipital (supra- and infracalcarine) structures on the right. The interictal epileptiform activity was mostly restricted to the infracalcarine gyrus, and 56 pure electrographic and two clinical seizures also originated from this area. Five other clinical episodes with visual auras and a numb sensation over the left hemibody occurred which were not accompanied by EEG-changes. Finally, similar to that which was observed during surface EEG recording, he experienced another prolonged episode of headache, typical of his habitual migraine attacks, with visual, sensory and autonomic manifestations. The SEEG revealed clear focal ictal epileptiform discharges first seen in the infracalcarine occipital electrode contacts and later propagating to supracalcarine structures. This seizure remained confined to the occipital lobe for more than 90 minutes before secondary generalization (*see video sequence 2*).

Neuropsychological evaluations showed a low average IQ, mild impairment in non-verbal memory and learning, and reduced fine motor-skills in both hands.

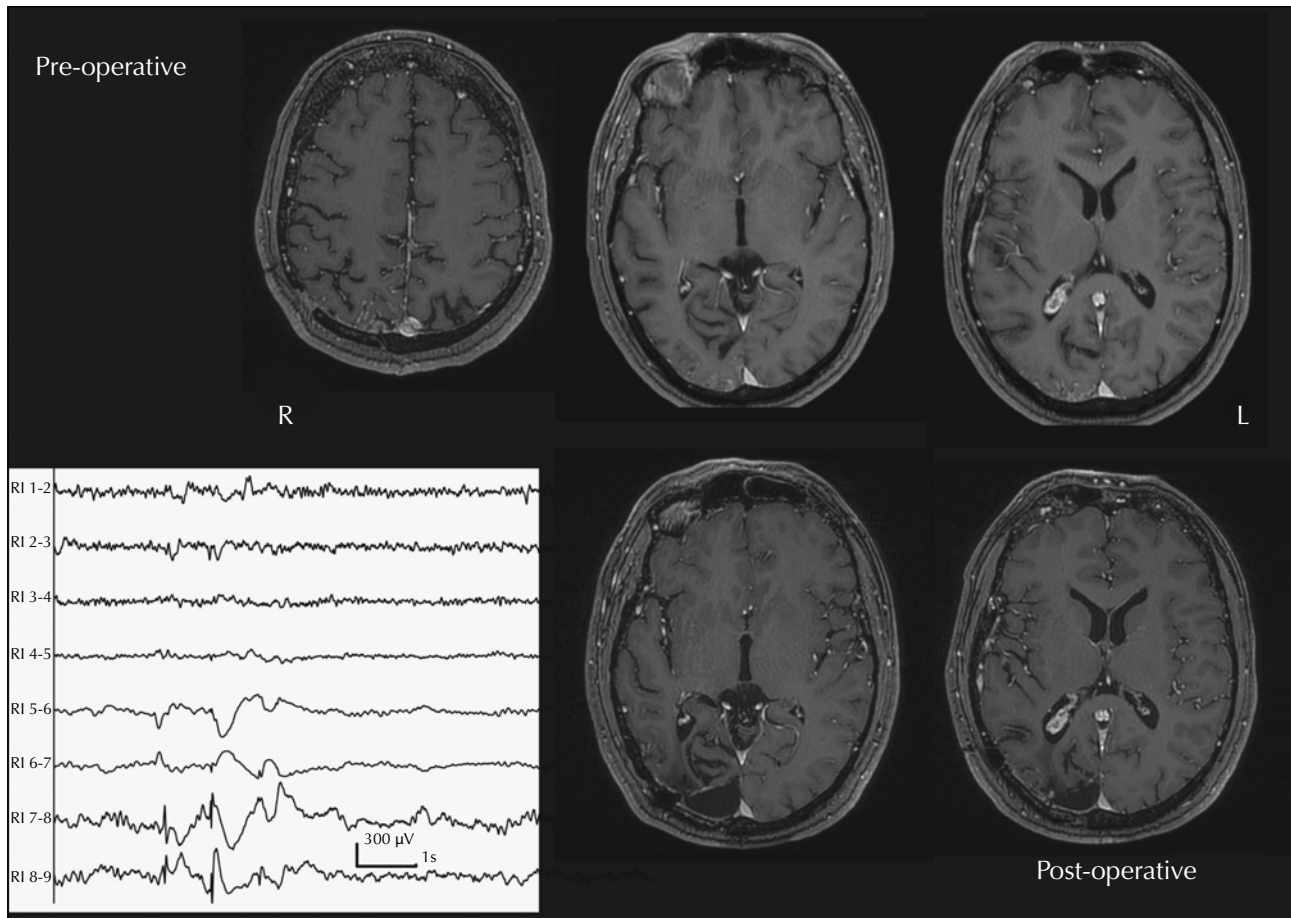


Figure 1. The preoperative MRIs in the upper row show clear signs of SWS: enhancement of the pial structures, gliotic changes in the underlying cortex and an enlarged choroid plexus. In the lower row, in the post-operative MRI after the first surgery, the surgical cavity as well as the remaining lesion are clearly visible. The intracranial EEG shows interictal spike-slow-waves over the most external contacts of RI, which is the infralcalcarine electrode.

The patient underwent an occipital cortical resection (January 2006) that included 2/3 of the infra- and supracalcarine structures from the mesial surface and extending laterally by ~ 4 cm (*figure 2*). This surgery led to great improvement, but he did not become seizure-free. Residual seizures remained brief and focal, consisting only of visual and sensory phenomena, perceptual impairment, disorientation and autonomic manifestations. After one year, the seizure frequency increased to three-four a month and the patient again became disabled by prolonged episodes of confusion, visual manifestations and severe headaches. In November 2007, the resection was extended anteriorly in the parietal lobe and the posterior temporal region. He now has a persistent, dense, left homonymous hemianopia, but so far has not experienced his habitual seizures. The lesion could not be removed entirely because of the additional risk of significant functional deficits. Histopathology confirmed the diagnosis of Sturge-Weber, showing pial fibrosis, abnormal vessels with markedly thickened and sometimes hyalinised walls,

extensive demyelination of white matter and moderate to marked gliosis in occipital cortex.

Discussion

This patient is unusual because of the late clinical onset, first characterized by a migrainous syndrome and later associated with rapidly progressive, refractory epilepsy. Before his first episode of headache at age 22, the patient was completely asymptomatic and showed only a discrete port-wine stain on his right forehead. Patients with SWS are usually affected early in life; most of them start to have seizures during infancy (Sujanski and Conradi 1995b) and the average age-at-onset of headaches is eight years (Kossoff *et al.* 2005). Also, they may demonstrate normal developmental milestones until the beginning of the seizures (Sujanski and Conradi 1995a), but then experience progression of the disease with increasing mental and motor deficits (Ville *et al.* 2002). Compared with studies of

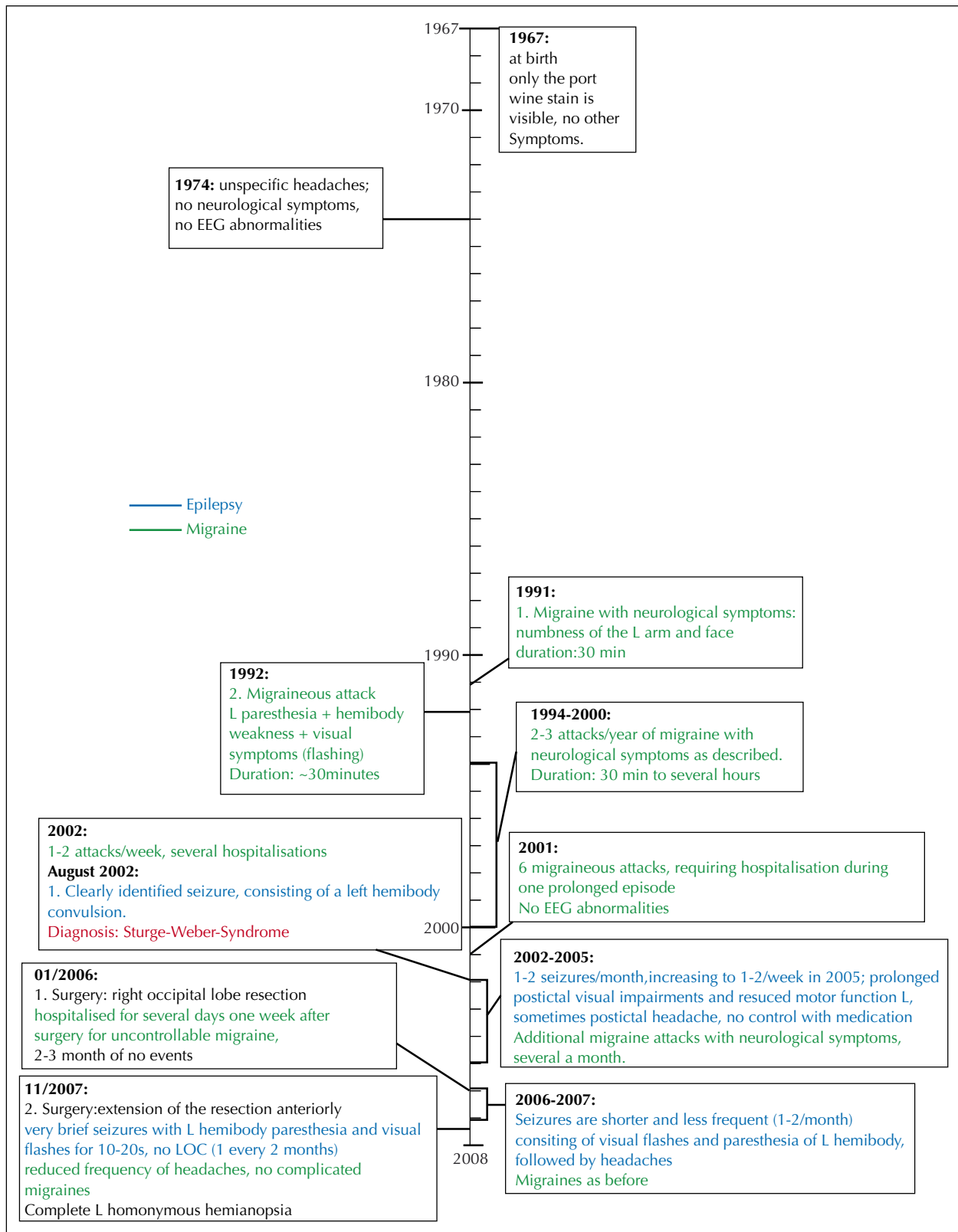


Figure 2. Development of the patient’s disease from birth to his last follow-up at the beginning of 2008; (green: migraine related events/blue: epilepsy related events).

larger groups, the onset of our patient's headache and epilepsy is extraordinarily late (Arzimanoglou *et al.* 2000, Sujanski and Conradi 1995a). Before his first episode of migraine at age 24, the patient had lived a healthy and unaffected life. It is unclear why he became symptomatic at this point, and even more importantly, why the disease from there on progressed to a point where he became severely disabled in everyday life, experiencing persistent visual disturbances, daily seizures and headaches.

One reason might be the unique physiopathology of the disorder. SWS most likely derives from a somatic mutation, which results in the failure of the primitive cephalic venous complex to regress during the first trimester of development (Comi 2003). The clinical manifestations depend on the degree and extension of the vascular malformation, and also on the cumulative amount of tissue damage in the underlying brain. These progressive necrotic and gliotic changes result from impaired venous blood flow in this area (Comi 2003, Oguz *et al.* 2007). The neurological symptoms are correlated with the degree of hypoperfusion as demonstrated by MR perfusion imaging (Lin *et al.* 2006). Thus, SWS is not a static disease and recurrent disturbances of brain function during migraine attacks and seizures may lead to additional metabolic disturbances such as hypoxia and further damage to the brain. Serial, anatomical MRI studies show clear progression of the disease in the form of increasing atrophy and calcification over time (Maria *et al.* 1998). The abnormal venous system is unable to react to acute events such as seizures (Aylett *et al.* 1999). SPECT and PET studies revealed that hypoperfusion and hypometabolism are not limited to the area directly underlying the venous malformation, but appear to damage more remote areas, including at times, the contralateral hemisphere (Bar-Server *et al.* 1996, Aylett *et al.* 1999). Patients with SWS often experience functional decline after each cluster of seizures, with postictal deficits that tend to become more prolonged with the duration of the epilepsy (Arzimanoglou *et al.* 2000). Prophylactic medical treatment before the onset of migraine or epilepsy, or surgery at an early stage, have been proposed to prevent the deterioration (Salman 1998, Ville *et al.* 2002). In our patient, recurrent, prolonged migraine attacks were often accompanied by major neurological symptoms, such as visual scotomata, hemibody paresthesia and weakness, and might have caused additional tissue damage leading to the development of seizures. This increased tissue damage was also suggested by the initially reversible visual scotoma, which later evolved into a permanent, inferior, homonymous quadrantanopsia and eventually hemianopsia. Unfortunately, early MR images were not available for comparison, but the first MRI obtained at age 35, as well as the pathological findings, clearly showed extensive gliotic changes and neuronal cell loss. The seizures rapidly became refractory, the patient experiencing several episodes of focal status epilepticus and some-

times prolonged visual symptoms in the form of flashing lights or scotoma.

The actual timing of onset of the patient's epilepsy might be questioned; he, himself, was unable to distinguish between migraine and seizures. In both situations, he experienced focal motor or sensory deficits, visual changes and headaches, and especially prolonged events were hard to classify. When questioned later, he could remember migraineous events in which he had had altered consciousness even before the presumed epilepsy onset. The EEG studies also illustrated this problem in differential diagnosis: during both surface and intracranial studies he experienced very similar prolonged events. During surface EEG, he had an event, which lasted for nearly four hours. The patient presented with nausea, headache, flashes and scotomata, although the recording showed no ictal activity. During the second event, recorded with depth electrodes and lasting more than an hour, he again had headache, visual symptoms and nausea, and the EEG showed focal ictal epileptic discharges before secondary generalization (the patient had been receiving reduced medication). This sustained ictal activity certainly has the potential to cause substantial damage to the vulnerable brain. This difficulty in understanding the significance of the acute symptoms in patients with SWS has been described previously (Dora and Balkan 2001, Jansen *et al.* 2004, Taddeucci *et al.* 2005), but have never been accompanied by intracranial EEG correlation as in our patient. The patient underwent two resective surgeries, leaving him with a substantial reduction in the number of seizures, improved quality of life, but also a permanent, homonymous hemianopsia to which he has had some difficulty adapting. Complete removal of the lesion would have most likely caused additional sensory and motor deficits. It is uncertain whether some of the tissue damage could have been prevented and the long-term outcome improved, if he had undergone surgery earlier. However, Arzimanoglou and co-authors did not find a significant correlation between the timing of surgery and outcome (2000), and success or failure was largely dependent on the extent of the removal of the damaged tissue. Another approach that has been suggested is early prophylactic treatment with medication that improves the blood supply, such as calcium-blockers or anti-aggregants such as aspirin. A study of patients with migrainous symptoms revealed that only 15% had been treated with serotonergic drugs and only a third were regularly using low dose aspirin (Kossoff *et al.* 2005). In our patient, acetaminophen (500 mg) was tried during the early manifestation of his migraine but this did not result in long-lasting relief and he received no preventive treatment.

Conclusion

In patients with SWS, the differentiation between migraine and epilepsy may be difficult especially if the seizures and

Legends for video sequences

Video sequence 1

Surface EEG.

Section A: normal sleep EEG.

Section B: at 00.43 am, the patient develops rhythmic delta activity over the right hemisphere, most prominent over the posterior head regions. He is asymptomatic and continues to sleep.

Section C: at 01.08 am, he calls the nurse and complains of severe, right-sided headache and nausea, as well as a numbness of his left arm. He thinks he is experiencing a migraine. The EEG-pattern is unchanged.

Section D: the first visual changes occur: the patient reports being unable to see and that this resembles his seizures. He also describes a numbness of his left face, arm and leg. He is fully alert and can respond to questions when tested. In the following hour, the patient's symptoms come and go, accompanied by continuous rhythmic delta waves over the right hemisphere. Parenteral anti-epileptic in addition to pain medications do not lead to improvement. After one hour, the patient becomes asymptomatic, but the EEG pattern remains unchanged. It does not improve until 03.05 when he again describes epileptic symptoms (Section E), which last for around five minutes. The EEG returns to normal at around 3:45 am.

Video sequence 2

Seizure recorded with implanted electrodes.

Section A: the patient calls the nurse and complains of severe headache at 4.00 am, shortly before this video-recording starts. On the EEG, 2 Hz delta activity is recorded from the infracalcarine gyrus. This evolves into ictal activity in the form of 3 Hz spike and wave complexes. Then a slow spread to the supracalcarine electrode can be observed.

Section B: at 4.10am, the patient calls the nurse again. He complains about numbness of the left arm and face. This is accompanied by a severe, right-sided headache. Rhythmic ictal activity can be seen over both calcarine gyri with predominance over the infracalcarine gyrus.

Section C: he complains for the first time of visual changes in form of flashes after the ictal discharges become more prominent and widespread, now involving all contacts of both calcarine electrodes.

Section D: thirty five minutes after seizure-onset, the ictal activity propagates over all contacts of the electrode. The patient now shows repetitive shaking of the head.

Section E: at 05.30 am, the patient has a secondary generalized seizure, which starts with a cry, and tonic movements of the head and mouth to the left. This is followed by tonic posturing of the left arm and then generalized clonic movements. The seizure lasts for about three minutes.

migraine attacks are both present and associated with ongoing neurological symptoms. Clinical manifestations may sometimes have late-onset as seen in our patient, but when present they may, as in early-onset patients, have a severe and progressive course. The progression of the functional deficits may indicate progressive neuronal damage due to the vascular malfunction; prophylactic medication and early surgery might reduce the risk of further brain damage and deterioration. □

Acknowledgments. JJ was supported by the Preston Robb Fellowship of the Montreal Neurological Institute.

References

- Arzimanoglou AA, Andermann F, Aicardi J, *et al.* Sturge-Weber syndrome: indications and results of surgery in 20 patients. *Neurology* 2000; 55: 1472-9.
- Aylett SE, Neville BG, Cross JH, *et al.* Sturge-Weber syndrome: cerebral haemodynamics during seizure activity. *Dev Med Child Neurol* 1999; 41: 480-5.
- Bar-Server Z, Conolly LP, Branes PD, *et al.* Tc-99m-HMPAO SPECT in Sturge-Weber-Syndrome. *J Nucl Med* 1996; 37: 81-3.
- Comi AM. Pathophysiology of Sturge-Weber syndrome. *J Child Neurol* 2003; 18: 509-16.
- Di Rocco C, Tamburrini G. Sturge-Weber syndrome. *Childs Nerv Syst* 2006; 22: 909-21.
- Dora B, Balkan S. Sporadic hemiplegic migraine and Sturge-Weber syndrome. *Headache* 2001; 41: 209-10.
- Hoffman HJ. Benefits of early surgery in Sturge-Weber syndrome. In: Tuxhorn I, Holthausen H, Boenigk H, eds. *Pediatric epilepsy syndromes and their surgical treatment*. London: John Wright & Sons Ltd, 1997: 364-70.
- Jansen FE, van der Worp HB, van Huffelen A, *et al.* Sturge-Weber syndrome and paroxysmal hemiparesis: epilepsy or ischaemia? *Dev Med Child Neurol* 2004; 46: 783-6.
- Kossoff EH, Hatfield LA, Ball KL, *et al.* Comorbidity of Epilepsy and Headache in patients with Sturge-Weber Syndrome. *J Child Neurol* 2005; 20: 678-82.
- Lisotto C, Mainardi F, Maggioni F, *et al.* Headache in Sturge-Weber syndrome: a case report and review of the literature. *Cephalalgia* 2004; 24: 1001-4.
- Lin DD, Barker PB, Hatfield LA, *et al.* Dynamic MR perfusion and proton MR spectroscopic imaging in Sturge-Weber syndrome: correlation with neurological symptoms. *J Mag Reson Imaging* 2006; 24: 274-81.
- Maria BL, Neufeld JA, Rosainz LC, *et al.* Central nervous system structure and function in Sturge-Weber syndrome: evidence of neurologic and radiologic progression. *J Child Neurol* 1998; 13: 606-18.
- Oguz KK, Senturk S, Ozturk A, *et al.* Impact of recent seizures on cerebral blood flow in patients with Sturge-Weber-Syndrome: Study of two cases. *J Child Neurol* 2007; 22: 617-22.
- Salman MS. Is the prophylactic use of antiepileptic drugs in Sturge-Weber-Syndrome justified? *Med Hypotheses* 1998; 51: 293-6.

Sujansky E, Conradi S. Outcome of Sturge-Weber syndrome in 52 adults. *Am J Med Genet* 1995a; 57: 35-45.

Sujansky E, Conradi S. Sturge-Weber syndrome: age of onset of seizures and glaucoma and the prognosis for affected children. *J Child Neurol* 1995b; 10: 49-58.

Taddeucci G, Bonuccelli A, Polacco P. Migraine-like attacks in child with Sturge-Weber syndrome without facial nevus. *Pediatr Neurol* 2005; 32: 131-3.

Thomas-Sohl KA, Vaslow DF, Maria BL. Sturge-Weber syndrome: a review. *Pediatr Neurol* 2004; 30: 303-10.

Tuxhorn IE, Pannek HW. Epilepsy surgery in bilateral Sturge-Weber syndrome. *Pediatr Neurol* 2002; 26: 394-7.

Ville D, Enjolras O, Chiron C, et al. Prophylactic antiepileptic treatment in Sturge-Weber-Syndrome. *Seizure* 2002; 11: 145-50.

John Libbey
EUROTEXT

ACTIVATE online access

to **YOUR JOURNAL**

FREE
for subscribers

You just need to have your subscription number* and follow the guidelines.

*If you do not know your subscription number:
Please refer to your invoice or call our subscription department:
+ 33 (0) 1 43 62 66 64

Go to **www.epilepticdisorders.com**

JOURNALS
All journals
Medicine
Biology and research
Public health
Agronomy and biotech.

SUBSCRIBERS
My account
Forgotten password ?
User access

SERVICES
Order an issue
Pay-per-view articles
Newsletters

AUTHOR INFORMATION

Access all articles online
Access articles in PDF
Access the journal archives