

**Anatomo-electro-clinical correlations:
the Miami Children's Hospital,
USA Case Report - Case 04-2008**

MRI-negative frontal lobe epilepsy with ipsilateral akinesia and reflex activation

Stephen Malone¹, Ian Miller¹, Prasanna Jakayar¹, Trevor Resnick^{1,2}, Sanjiv Bhatia^{1,3}, Michael Duchowny^{1,2}

¹ Brain Institute and Comprehensive Epilepsy Program, Miami Children's Hospital

² Department of Neurology, University of Miami Miller School of Medicine

³ Department of Neurosurgery, University of Miami Miller School of Medicine, Miami Florida, USA

Received May 23, 2008; Accepted September 28, 2008

ABSTRACT – [Case records of *Epileptic Disorders*. Anatomo-electro-clinical correlations. Case 04-2008] The pre-operative assessment and surgical management of children and young adults with MRI-negative, frontal lobe epilepsy is often challenging owing to the semiologic expression being unusual or non-lateralizing. Localization based on functional tests may be non-convergent, further compounding the difficulty of surgical planning. We describe a patient with seizures presenting with early, subjective akinesia of the dominant hand that were at times triggered by repetitive motor tasks. Subdural EEG monitoring revealed seizure-origin in the ipsilateral dorsolateral frontal lobe. After resective surgery the patient has had a seizure free period of 9 months, and is free of deficits. This is the first report of frontal lobe seizure semiology consisting of ipsilateral ictal akinesia. [Published with video sequences]

Key words: childhood epilepsy, frontal lobe epilepsy, epilepsy surgery, presurgical assessment

A 17-year-old, right-handed male presented for management of intractable, partial epilepsy. Seizures had begun at age six years and were characterized by brief periods of unresponsiveness and fumbling hand movements, preceded by an aura of vague cephalic sensations or more rarely, an ill-defined sensation in both hands that began minutes or hours before motor seizure-onset. At onset, he

complained of an inability to use his right hand. Awareness was preserved during his seizures, which typically lasted 10-20 seconds, and he was mute throughout. Head turning to the right, with accompanying clonic jerking of the left arm accompanied some seizures. Secondary generalized events occurred infrequently, but ictal falls and injuries were common. Seizure frequency was at least weekly. His longest seizure-free interval was two years. Failed medications included carbamazepine and oxcarbazepine, both maintained at high doses, at the time of surgical intervention. Compliance was demonstrated by therapeutic plasma levels of anticonvulsants. Drug side effects included diplopia and severe fatigue.

The patient had been born at term, by elective C-section, after an unremarkable maternal pregnancy. He had borderline hypothyroidism as a younger child. Developmental milestones were normal and he was an above-average student. There was no family history of seizures. His sister



Correspondence:

M. Duchowny
Department of Neurology,
Miami Children's Hospital,
3200 S.W. 60th Court, Suite 302,
Miami, Florida 33155-4079, USA
<michael.duchowny@mch.com>

has neurofibromatosis type 1. Neurological examination revealed two, small, "café au lait" patches, but no other stigmata of neurofibromatosis. There were no focal neurological abnormalities.

Pre-surgical investigations

Previous EEG studies had revealed independent, left and right central and parietal epileptiform discharges, with nonspecific slowing over a wide bilateral field. However, multiple video-EEG studies between ages 15 and 17 years, localized interictal sharp wave discharges in the right frontal and central regions (F4/Fp2 > C4), with a field incorporating the frontal-central midline (Fz/Cz) (figure 1). There were no independent, left hemispheric discharges. His seizures were induced by alternating rapid movements of the hands on two separate occasions, and he consistently described an inability to initiate movement in his right hand at seizure-onset. The earliest observable clinical change was a sudden head tilt/gaze to the right, at times accompanied by atonia of the upper limbs. Longer events evolved into clonic motor activity of the left arm and versive, left, head turning. Secondary generalized tonic-clonic activity accompanied a minority of seizures after drug withdrawal. Speech arrest occurred at seizure-onset, but fluency returned soon after seizure-offset. He remained fully conscious and remembered words spoken during the seizures. Electrographic ictal onset localized to the right frontal and midline regions (figure 2), with later involvement of the contralateral hemisphere during longer events.

Anatomical and functional neuroimaging

MRI studies at 1.5 and 3 T were negative. Functional MRI revealed left-sided language dominance and normal activation patterns during motor tasks. Ictal SPECT revealed a subtle area of hyperperfusion in the right anterior frontal convexity. Repeat ictal SPECT (figure 3) revealed a more robust area of hyperperfusion in the same location, with subtle, increased perfusion in the surrounding regions. PET imaging (FDG/flumazenil) revealed focal hypometabolism in the left mesial temporal and inferior frontal regions. A cluster of seizures had occurred immediately prior to scanning (figure 4). A repeat PET in the interictal state revealed bi-parietal hypometabolism.

Neuropsychological assessment

Neuropsychological assessment at age 16 demonstrated normal, full-scale verbal and non-verbal intelligence but a specific disorder in mathematics suggesting dominant parietal lobe dysfunction.

Pre-surgical case conference discussion

The sensation of right arm akinesia was correlated to an ictal EEG onset zone in the ipsilateral right frontocentral region; the right head tilt and left arm clonic activity further suggested right frontal lobe involvement. Seizures induced by alternating movements indicate involvement of anterior frontal motor planning systems.

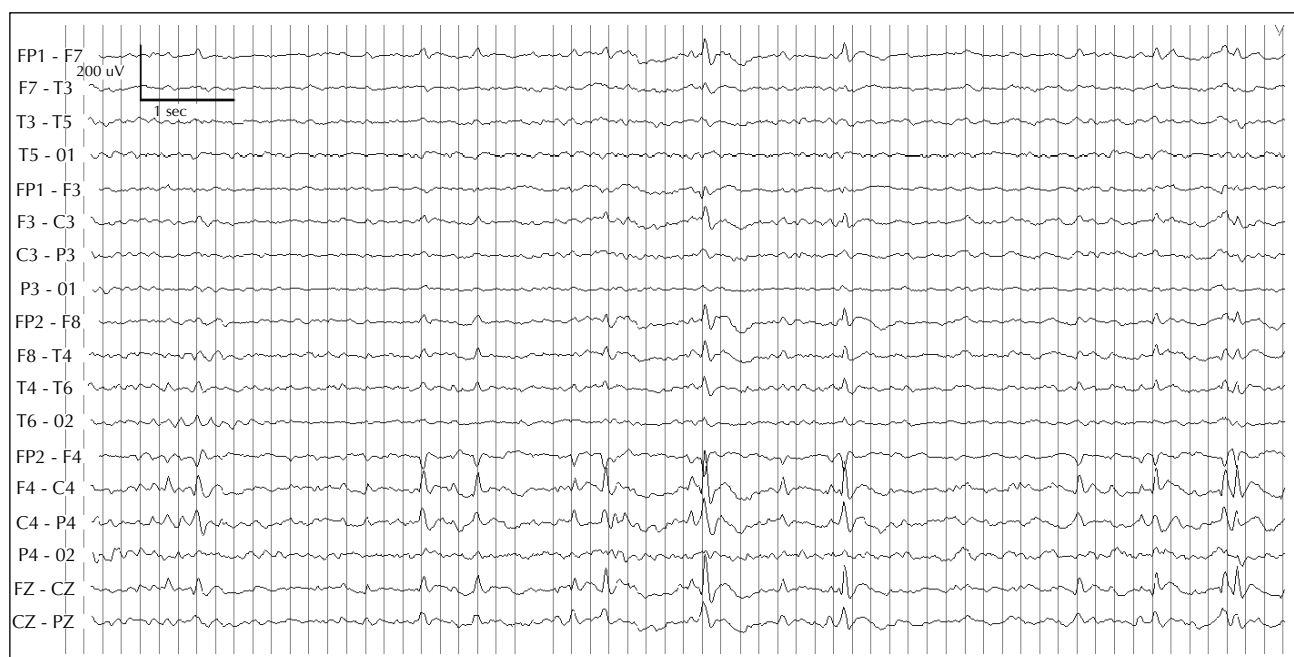

Figure 1. Interictal sleep EEG recording at age 17 years showing frequent, epileptiform sharp and sharp-slow wave discharges over the right frontocentral region, with wide right hemisphere and midline electrode field.

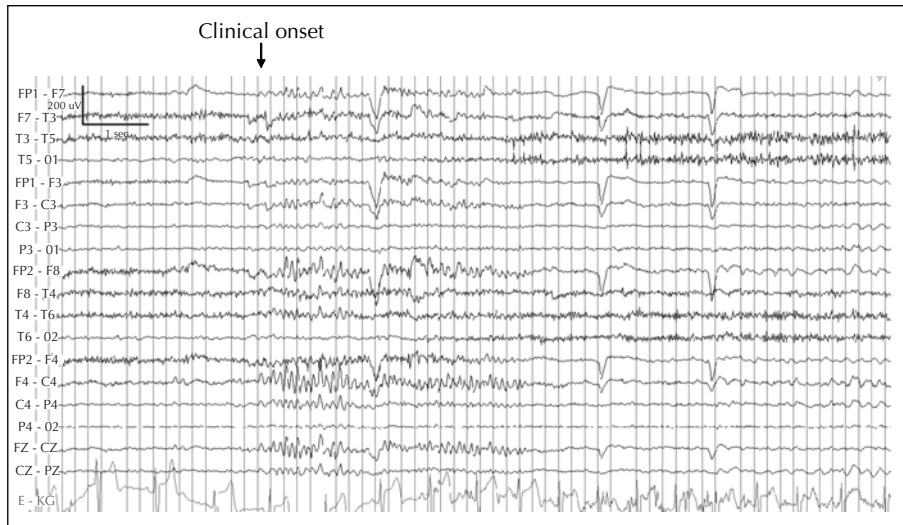


Figure 2. Ictal scalp EEG during a scalp-recorded, habitual seizure. Burst of high voltage fast activity is noted over the right frontocentral area having a wide field but with midline emphasis, followed by late rhythmic theta frequencies in the same location and occurring until the end of the electrographic sequence. Clinical onset corresponded to electrical onset (*see video sequence 1*).

The presence of bilateral upper limb atonia during some seizures suggested possible bilateral involvement of both motor cortices or unilateral involvement of the supplementary sensorimotor area (SSMA).

The epileptogenic region was hypothesized to involve right premotor cortex and ipsilateral SSMA with secondary involvement of the right motor cortex. Left hemisphere involvement was a concern, given the early, negative,

right-hand motor phenomenon, PET findings, and dominant hemisphere dysfunction as suggested by neuropsychological evaluation. However, the hyperperfusion in the right frontal region on ictal SPECT reliably co-localized seizure origin to the region of maximal EEG abnormality.

Surgical plan and procedure, and outcome

A 48-contact, subdural grid that included motor cortex was implanted over the right frontal convexity, and an 8-contact strip was placed in the right interhemispheric

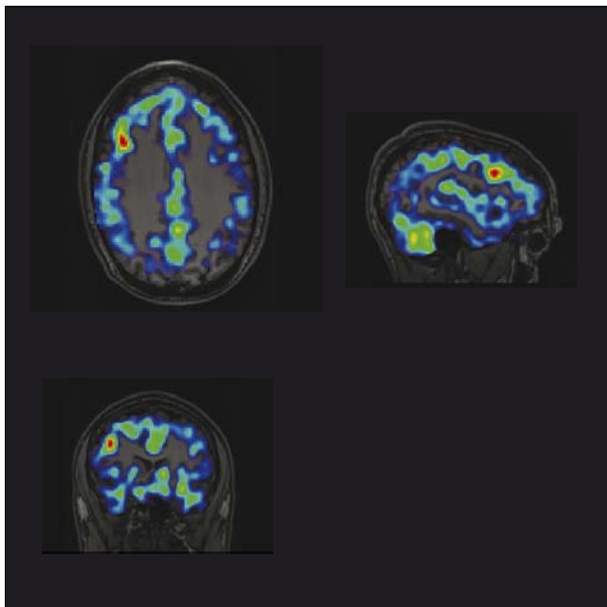


Figure 3. Ictal SPECT (Tc-HMPAO) performed during a typical seizure. Injection took place 15 seconds after seizure-onset. Hyperperfusion is noted in the right frontal convexity.

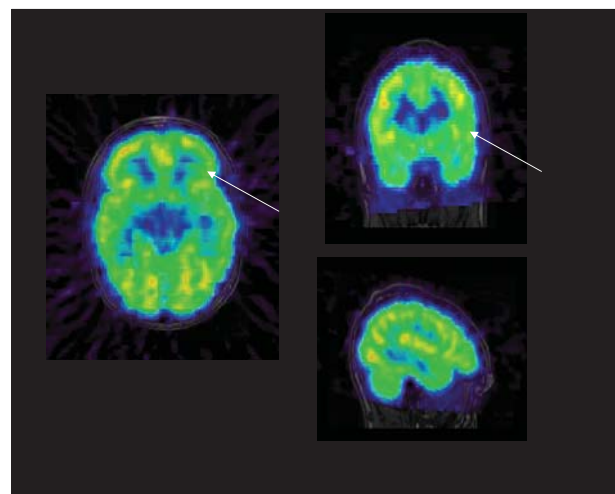


Figure 4. Flumazenil PET imaging demonstrating asymmetric metabolism in the left inferior frontal region. FDG PET performed the day prior revealed an additional region of hypometabolism in the left mesial temporal region. Scans were performed after seizure clusters.

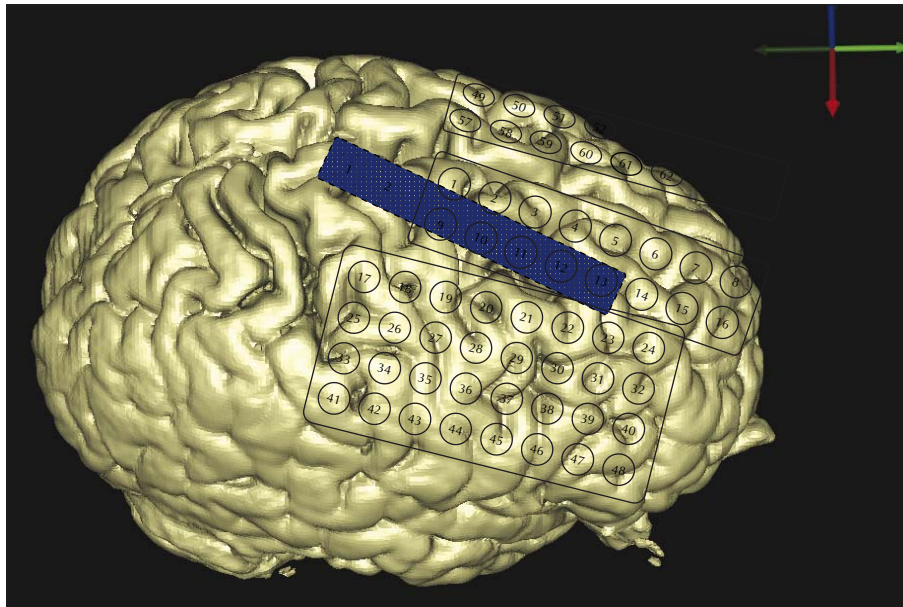


Figure 5. Supero-lateral view of implanted electrodes: 48 contacts over the right frontal region, with 8 contact electrode (blue) in the right interhemispheric area. A 16-contact grid was placed epidurally over left frontal lobe, overlapping the central area posteriorly.

region. A 16-contact grid was located epidurally, over the left frontoparietal convexity (figure 5).

Subdural monitoring revealed continuous epileptiform discharges over the right frontal lobe, with a consistent

lead from area 6 on the convexity (figure 6), just anterior to the hand motor cortex identified via electro-cortical stimulation mapping. Epileptiform discharges recorded from the right interhemispheric SSMA region were synchronous,




Figure 6. Interictal invasive EEG recording. Subdural contacts G1-48 (right convexity), Epidural contacts G49-64 (left frontocentral convexity). Subdural contacts IH 1-8 (right interhemispheric). Continuous epileptiform spike-slow wave discharges emanating from the superior frontal contacts, with wide propagation over inferior dorsolateral contacts, and less frequent epileptiform activity in the right interhemispheric region. Bipolar montage. Epidural contact sensitivity ($50 \mu\text{V}/\text{mm}$) increased to approximate amplitude from the subdural electrodes ($150 \mu\text{V}/\text{mm}$).

but usually less prominent than those recorded over the convexity. Infrequent, independent epileptiform activity was noted in the left interhemispheric and perirolandic regions (*figure 7*).

Clinical seizures were accompanied by ictal onset from area 6 over the right frontal convexity and spread to the interhemispheric region (*figure 8*). Electrical stimulation during mapping over area 6 on the convexity induced his habitual seizures but none were induced upon stimulation of the SSMA region. Independent ictal sequences were recorded from the left frontal convexity contacts, and correlated with episodes of bilateral, tonic, limb stiffening lasting seconds and occurring in clusters.

A corticectomy was performed involving the right frontal premotor region. The resection plane included the regions of early, subdural, ictal involvement and the SPECT abnormality (*figure 9*). The interhemispheric region was not resected and motor cortex was spared.

Immediately post-operatively, the patient was emotionally blunted and exhibited a resting tremor of the upper limb that was exacerbated by movement. The emotional blunting disappeared over the subsequent week, although subtle, bilateral, upper extremity tremor has remained. The patient had a cluster of non-typical seizures, following a brief reduction of anticonvulsant medication on the third and fourth post-operative days. He has been seizure-free for nine months following surgery, and is taking fewer

anticonvulsant medications. Quality of life has subjectively improved. Neuropathology of the tissue revealed Palmini type 2b cortical dysplasia.

Discussion

Our patient's ictal ipsilateral hand akinesia is an unusual finding that, to our knowledge, has not been previously reported. Clinically, the patient's motor paresis closely resembled an ictal limb apraxia in that he had no evidence of neuromuscular weakness during his daily activities, and the immobility occurred only during his seizure while he was awake and aware. The occurrence of inhibitory motor phenomena during seizures and the concept of "negative motor areas" have been previously reviewed (Noachtar and Lüders 2000). Immobility of the upper limb may be produced by focal cortical stimulation of prefrontal cortex anterior to the motor face area, but the response is typically contralateral (Penfield and Jasper 1954, Noachtar and Lüders 2000). Stimulation of the anterior SSMA also generates a negative motor response (Lim *et al.* 1994). Although purely ipsilateral atonia has not been reported during functional stimulation of SSMA, ipsilateral positive motor responses are well described, reflecting the bilateral output of SSMA to motor pathways (Fried *et al.* 1991). The speech arrest observed during SSMA seizures is also conceptualized as an akinetic event (Noachtar and Lüders




Figure 7. Interictal invasive EEG recording in sleep with continuous epileptiform activity seen over the right high frontal convexity contacts. Independent epileptiform activity is noted over the left frontal convexity, maximal anteriorly (contacts 55-56). Referential montage. (Epidural contacts 50 $\mu\text{V}/\text{mm}$; subdural contact 150 $\mu\text{V}/\text{mm}$).

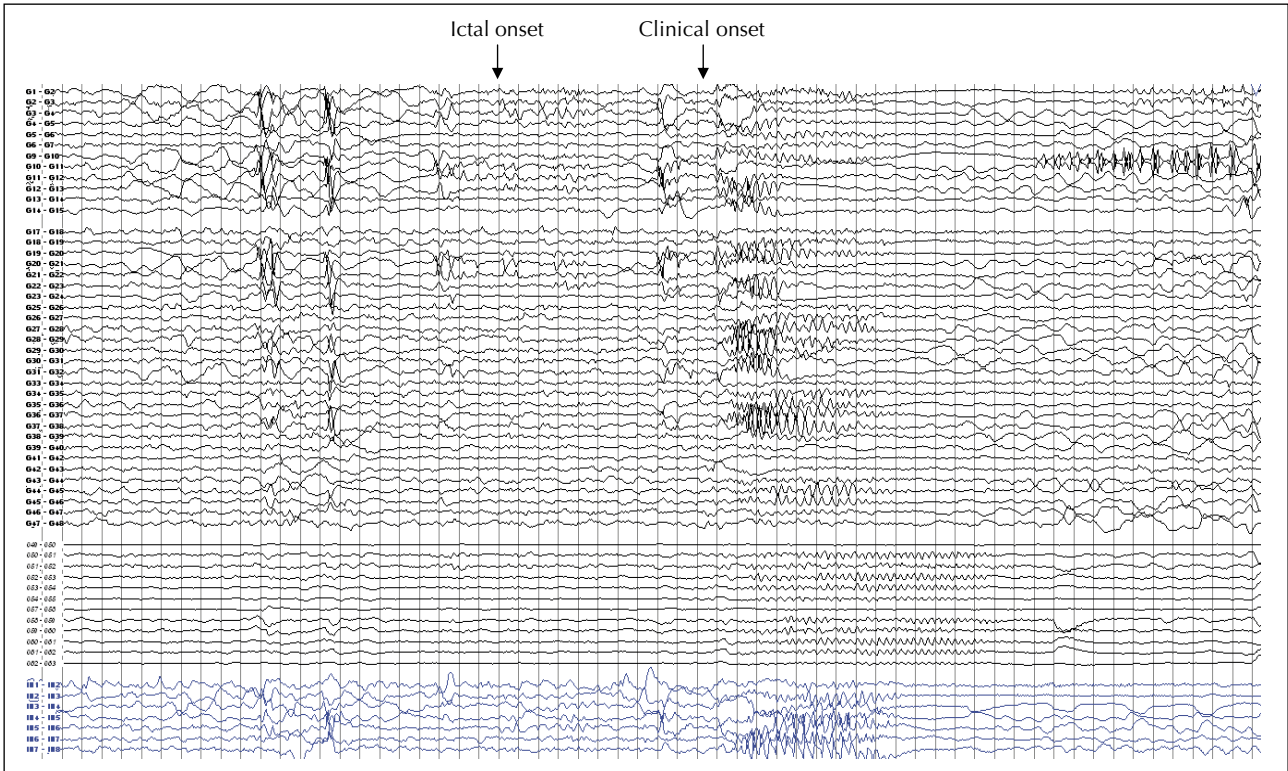


Figure 8. Subdural seizure-onset during habitual seizures. Initial fast activity and attenuation over the superior convexity is followed by rapid involvement of interhemispheric region (see video sequence 2).

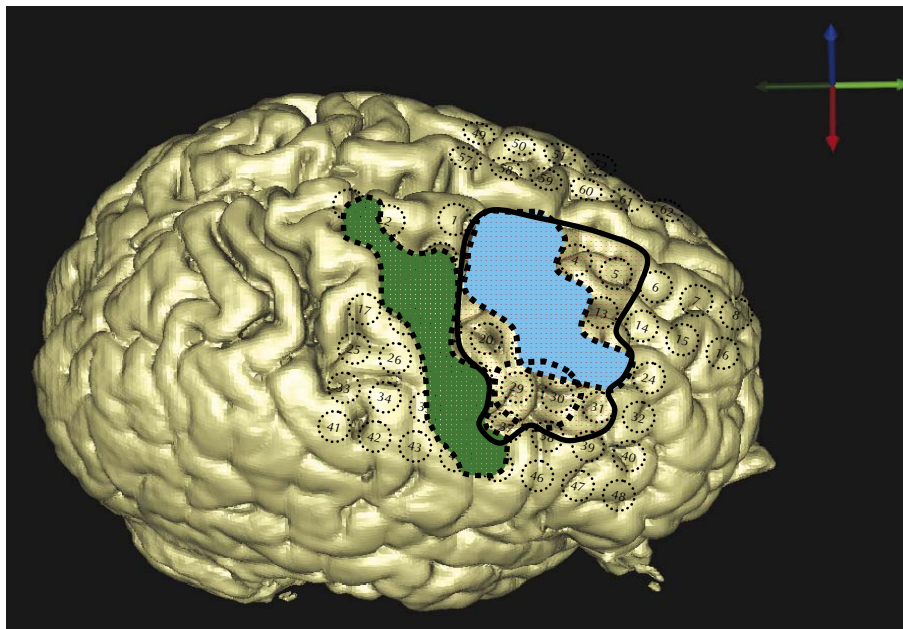


Figure 9. Overlay of motor cortex as defined by functional mapping (green), ictal onset zone (blue), SPECT hyperperfusion (orange), and final resection (dark-bordered region including pink).

Legends for video sequences

Video sequence 1

Typical seizure, recorded by scalp video-EEG, and occurring during sequenced finger movements. Cessation of movement is followed by head tilt to the right and the appearance of bilateral upper limb atonia. Clinical change coincided with initial scalp electrographic change (*figure 2*). With progression, there is a toing-froing movement of the head, and mild upper limb tonic stiffening, the left being greater than right. Intermittent grunting vocalization is audible. Ipsilateral weakness or asymmetry is not apparent on the video or during the immediate post-ictal examination, although this was consistently reported by the patient at seizure-onset. The patient was able to remember a word spoken during the seizure. The seizure lasted for 12 seconds.

Video sequence 2

Patient's habitual seizure, obtained during subdural monitoring, occurring from drowsiness. As with sequence 1, abrupt head rightward tilt is noted and accompanied by early tonic stiffening of the left arm. Rapid left finger movements are seen during the late phase, with admixed clonic activity. Subsequent bilateral motor spread is seen. The patient was able to verbalize promptly after seizure-offset. The early part of the ictal EEG is shown in *figure 8*, showing earliest involvement of the right upper convexity contacts, with rapid interhemispheric spread.

2000). In our patient, the convexity and interhemispheric premotor regions were involved early in the ictal discharge, but electrical stimulation of only the convexity led to habitual seizures leading us to postulate that the lateral premotor region was responsible for the ipsilateral akinesia.

It is of interest that our patient's seizures were at times provoked by sequenced motor tasks, suggesting an intermittent reflex ictal component. Subdural recording revealed ictal involvement of cortical regions known to subserve the planning and sequencing of ipsilateral and bilateral motor movements (Krakauer and Ghez 2000). In animal studies, the lateral prefrontal area and SSMA participate in the learning phase of coordinated movements; the lateral prefrontal area being preferentially involved (Krakauer and Ghez 2000). In our patient, seizures may have been triggered by prefrontal and SSMA activation during the fine motor tasks offered. Lateral frontal and premotor seizures with a reflex component have been reported previously, usually as a response to different somatosensory stimuli (Manford *et al.* 1996).

Our case also highlights the need for careful clinical interpretation of preoperative investigations and a consideration of the limitations of each test. Regional abnormali-

ties on FDG/flumazenil PET imaging strongly correlate with the epileptogenic region in children with focal seizures (Muzik *et al.* 2000). Initial PET imaging performed on our patient implicated the left temporal and inferior frontal areas in seizure-origin. However, the study was performed during the immediate post-ictal period when PET findings are often inconsistent (Chugani *et al.* 1993). Relative hypermetabolism may also be recorded in the hemisphere of ictal onset, falsely suggesting 'hypometabolism' in the contralateral hemisphere (Henry and Chugani 2008).

This case demonstrates some of the challenges in the assessment of MRI-negative, frontal lobe epilepsy, particularly in the presence of discordant preoperative investigations. Our patient had an additional level of complexity due to early symptoms ipsilateral to the seizure focus. The resective strategy was guided primarily by ictal onset zone and maximal interictal subdural EEG abnormalities, and included the region of hyperperfusion on ictal SPECT. Although the right SSMA was significantly involved, the independent, potential epileptogenicity over the left dictated a more conservative corticectomy of the convexity alone; the long term success of this approach in our patient is awaited. □

References

- Chugani HT, Shewmon DA, Khanna S, *et al.* Interictal and Postictal Focal Hypermetabolism on Positron Emission Tomography. *Pediatr Neurol* 1993; 9: 10-5.
- Fried I, Katz A, McCarthy G, *et al.* Functional organization of human supplementary motor cortex studied by electrical stimulation. *J Neurosci* 1991; 11: 3656-66.
- Henry TR, Chugani HT. Positron Emission Tomography. In: Engel J, Pedley T, eds. *Epilepsy: A comprehensive Textbook*. Philadelphia: Lippincott Williams and Wilkins, 2008: 945-64.
- Krakauer J, Ghez C. Voluntary movement. In: Kandel ER, Schwartz JH, Jessel TM, eds. *Principles of Neural Science 4th Edition*. McGraw-Hill Medical, 2000: 757-81.
- Lim SH, Dinner DS, Pillay PK, *et al.* Functional anatomy of the human supplementary sensorimotor area: results of extraoperative electrical stimulation. *Electroencephalogr Clin Neurophysiol* 1994; 91: 179-93.
- Manford MR, Fish DR, Shorvon SD. Startle provoked epileptic seizures: features in 19 patients. *J Neurol Neurosurg Psychiatry* 1996; 61: 151-6.
- Muzik O, da Silva EA, Juhasz C, *et al.* Intracranial EEG versus flumazenil and glucose PET in children with extratemporal lobe epilepsy. *Neurology* 2000; 54: 171-9.
- Noachtar S, Lüders HO. Akinetic seizures. In: Lüders HO, Noachtar S, eds. *Epileptic seizures: Pathophysiology and Clinical Semiology*. Philadelphia: Churchill Livingstone, 2000.
- Penfield W, Jasper H. Functional localization in the cerebral cortex. In: Penfield W, Jasper H, eds. *The functional anatomy of the Human Brain*. Boston: Churchill Livingstone, 1954: 41-155.