

Positron emission tomography in epileptogenic hypothalamic hamartomas

Philippe Ryvlin^{1,2}, C. Ravier¹, S. Bouvard^{1,2},
François Mauguière¹, D. Le Bars², Alexis Arzimanoglou³,
Jérôme Petit⁴, Philippe Kahane⁵

1. Department of Functional Neurology and Epileptology, Neurology Hospital, and
2. CERMEP, Lyon
3. Epilepsy Unit, Child Neurology and Metabolic Diseases Dpt. University Hospital Robert Debré, Paris
4. Centre de la TEPPE, Tain l'Hermitage
5. Physiopathology of the Epilepsies Department, University Hospital of Grenoble, France

ABSTRACT – Whether the intrinsic epileptogenicity of hypothalamic hamartomas (HH) is responsible for the entire clinical spectrum of epileptic, neuropsychological and behavioural disorders associated with HH, remains an open issue, in as much as morphologically similar HH can be associated with dramatically different seizure types and cognitive outcomes.

The aim of this study was to investigate brain glucose metabolism in patients with epileptogenic HH, in an attempt to identify signs of focal cortical and subcortical dysfunction which might correlate with other clinical data.

We have studied five patients with epileptogenic HH using [¹⁸F]-fluorodeoxyglucose and positron emission tomography (FDG-PET). All our patients also underwent an optimal MRI and a video-EEG monitoring, as well as an intra-cranial EEG recording in one of them. The anatomical distribution of FDG-PET abnormalities was compared to that of interictal and ictal electro-clinical findings.

All five patients demonstrated focal hypometabolism, ipsilateral to the predominant EEG abnormalities and side of HH. Hypometabolic areas greatly varied between patients, but were grossly concordant with the cortical regions suspected to participate in the ictal discharges in each individual.

Epileptogenic hypothalamic hamartomas are usually associated with focal cortical hypometabolism in regions which might participate in the overall HH-driven epileptic network. Whether these cortical abnormalities only reflect the propagation of ictal discharges, or a potentially independent seizure onset zone remains unknown.

KEY WORDS: hypothalamic hamartoma, glucose metabolism, FDG, PET, epilepsy

Correspondence:

Pr. Philippe Ryvlin, Unit 301,
Department of Functional Neurology
and Epileptology, Hôpital Neurologique,
59 bd Pinel, 69003 Lyon. France.
E-mail: ryvlin@cermep.fr

Presented at the International Symposium on
Hypothalamic Hamartoma and Epilepsy,
Montreal Neurological Institute, Montreal,
Canada, November 29th 2001.

In recent years, a consensus has emerged regarding the brain structures to be surgically targeted in drug-resistant epilepsy associated with hypothalamic hamartoma (HH) [1-11]. Indeed, several series demonstrated that the surgical treatment of the HH

proper was the only therapeutic option likely to control seizures [4-6, 8-9], whereas cortectomies, guided by intra-cranial EEG recordings always proved ineffective [12]. Some uncertainties persist, however, as to the reasons why HH surgery still fails in some

patients. The role of an incomplete resection of the hamartoma appears to be the most likely explanation [13], but the participation of an associated epileptogenic cortical network cannot be excluded. On the one hand, this latter hypothesis would be consistent with the stereo-EEG findings reported by Claudio Munari's group [1-2] showing that epileptic discharges associated with gelastic seizures arose from the HH, whereas other partial or generalized-like seizures started elsewhere in cortical brain regions. In the context of a hamartoma, one might suspect the presence of other malformations of cortical development, too subtle to be detected by MRI, that could underlie an independent cortical epileptic focus. No histological changes however, were found on resected cortical specimens [12]. On the other hand, all types of seizures can be controlled by HH removal only [6, 13-15], suggesting the possibility that the putative associated cortical epileptic network might result from secondary epileptogenesis, and then normalize after eliminating the primary HH focus. A better understanding of the anatomy of cortical dysfunction associated with HH might help to address this issue. [¹⁸F]fluorodeoxyglucose positron emission tomography (FDG-PET) can detect cortical abnormalities in epileptic patients whose MRI is normal [16]. In HH, FDG-PET was reported in only two independent case reports, showing a lateralized temporal lobe hypometabolism consistent with the localization of EEG abnormalities in both patients [12, 17].

Apart from the issue of seizure origin, PET study of cortical dysfunction might also provide new insights in the pathophysiology of the behavioural and neuropsychological disorders frequently associated with HH [18-21].

With the aim of addressing these issues, we have prospectively studied five patients with drug-resistant epilepsy and HH, using FDG-PET.

Patients and methods

Subjects

The five patients were referred to the epilepsy departments of Lyon and Grenoble University Hospitals, for drug-resistant epilepsy. There were three boys and two girls, aged 13 to 25 years at the time of the PET study. They all had suffered from gelastic seizures, starting at birth or up to the age of 8 years old, as well as having other types of seizures. Pertinent clinical data are presented in *table 1*.

A hypothalamic hamartoma had been previously detected on MRI in three of these patients (No 1 to 3), whereas HH was first diagnosed during the evaluation performed at our institution in the other two (No 4 and 5).

Electro-clinical data

All patients had undergone several standard EEG recordings and a video-EEG monitoring, before entering the study. In addition, patient No 2 had an intra-cranial EEG investigation, performed at the epilepsy surgery department of Grenoble [22]. Electro-clinical data derived from these investigations were reviewed by two of the investigators (PR and PK), in an attempt to define the brain areas predominantly involved during interictal and ictal epileptic discharges, outside the HH. Interictal behavioural and neuropsychological disorders were also assessed, based on the patient's history.

MRI

All patients underwent a standardized MRI during this study on a 1.5 tesla device (Magnetom 63SP; Siemens, Erlangen), and included a 3D mpr T1 acquisition (TR: 9.7 ms, TE: 4 ms), providing 1 mm thick slices in all desired planes, as well as axial spin echo T2 sequence (TR: 2 260 ms, TE: 45 and 90 ms), and coronal turbo-spin echo T2 sequence (TR: 3 000 ms, TE: 16 and 98 ms). We clas-

Tableau I. Clinical data.

Patient n°	Epilepsy onset	Gender	Handeness	Gelastic seizures	Other seizures	Other clinical findings	Agressive behavior	Cognitive disorders	Type of hamartoma
1	Birth	M	Left	+	+	Facial asymmetry	+	-	Intra
2	6 years	F	Left	+	+	Facial asymmetry Obesity precocious puberty	+	Moderate	Intra
3	Birth	F	Left	+	+	Facial asymmetry Obesity precocious puberty	-	Severe	Extra
4	3 months	M	Right	+	+	Sixth finger (<i>Pallister Hall syndrome</i>)	-	Moderate	Intra
5	8 years	M	Right	+	+	-	+	-	Intra

M: male; F: female; Intra: intra-hypothalamic; Extra: extra-hypothalamic.

sified the HH as either intra-hypothalamic, when confined to the hypothalamus, and extra-hypothalamic when hanging down into the interpeduncular cistern. We also considered the lateralization of the hamartoma.

PET

PET was performed using a high-resolution tomograph (HR +, Siemens, Erlangen), providing 2.4 mm thick slices, with an isotropic spatial resolution of 5 mm. A thermolabile, plastic facemask ensured the stable position of the head in these patients. Attenuation correction was measured in each individual using a ^{68}Ge transmission scan. A bolus of 2 to 3 mCi of [^{18}F]FDG was then injected intravenously, while patients were lying at rest in a dimly lit room, with eyes closed and ears unplugged. When a steady state was reached, 40 min later, we performed a 10 min duration, image acquisition. The resulting PET images were qualitatively reviewed by one of the investigator (PR), blinded to other data.

Surgery

Patient 2 underwent a partial and unsuccessful resection of the HH. Patient 1 recently underwent radiosurgical treatment, the therapeutic effect of which can not yet be evaluated.

Results

Localization of interictal and ictal epileptic discharges (see *table 2* for details)

Patient No 1

This patient had non-localizing, left predominant, interictal EEG findings, and ictal discharges pointing to the left temporal and central regions. Ictal symptoms included a pressure to laugh, suggestive of intra-hypothalamic discharge, followed by a rising epigastric sensation, associated with throat discomfort, and dreamy state. These latter symptoms could also occur without, prior sensation of pressure to laugh. Altogether, available electro-clinical data in this patient suggested that the left temporal lobe was the most affected cortical region.

Patient No 2

This patient had non-localizing right predominant interictal scalp-EEG findings. Seizures were only recorded during intra-cerebral EEG recordings, showing two different patterns: dacrystic seizures associated with an intra-hamartoma discharge; seizures starting with a rising, thoracic warm feeling, followed by auditory illusions, dizziness, a painful sensation in the left leg, left facial contraction and hemibody hypertonia, associated with a right temporo-fronto-central stereoEEG ictal discharge which did not involve the hamartoma [23].

Patient No 3

This patient had right fronto-temporal spikes and slow waves, and various types of gelastic seizures. Those recorded during video-EEG monitoring were followed by left hemibody, tonic-clonic manifestations associated with a right frontal EEG discharge, followed by a post-ictal, left-sided Todd's paralysis. Thus, in this patient, the right frontal lobe was regarded as the most affected cortical region.

Patient No 4

This patient had intermittent left, temporo-occipital slow waves. Ictal symptoms included a rising, thoracic warm sensation, followed by blush, smile or laughter, and spatial disorientation, associated with a bi-temporal EEG discharge evolving into a left-predominating, widespread rhythmic activity. Based on these data, the left temporal lobe, and possibly the left temporo-occipital area were thought to represent the predominantly involved cortical region in this patient.

Patient No 5

This patient had non-localizing, predominantly right interictal and ictal slow waves. Apart from gelastic seizures, the patient suffered nocturnal fits characterized by a right-sided gyration of the whole body, followed by secondary generalisation. This ictal sequence was poorly localizing, as gyration can occur ipsilateral or contralateral to seizure onset, depending on the brain region involved by the ictal discharge [24, 25]. Since the lateralization of interictal spikes favored a predominantly right-sided cortical involvement, we interpreted the gyration as most likely ipsilateral, which would then be consistent with a right temporo-parieto-occipital ictal discharge.

Behavioural and neuropsychological manifestations

Three of the five patients (No 1, 2 and 5) had a history of aggressiveness and sudden violent behaviour. Intellectual disabilities were observed in three patients, and rated as severe in one (No 3), and moderate in the two others (No 2 and 4).

MRI

Four of the five HH were small, sessile, intra-hypothalamic hamartomas (*figure 1*), whereas the remaining one was large and pedunculated (*figure 2*). Three HH were right sided, whereas two had a left predominance. No other malformation of cortical development was observed, but a mild hippocampal asymmetry of uncertain significance was noted in patient No 1, pointing to the side of HH predominance as possibly atrophic.

FDG-PET

All patients demonstrated clear-cut metabolic abnormalities on FDG-PET images. These metabolic abnormalities

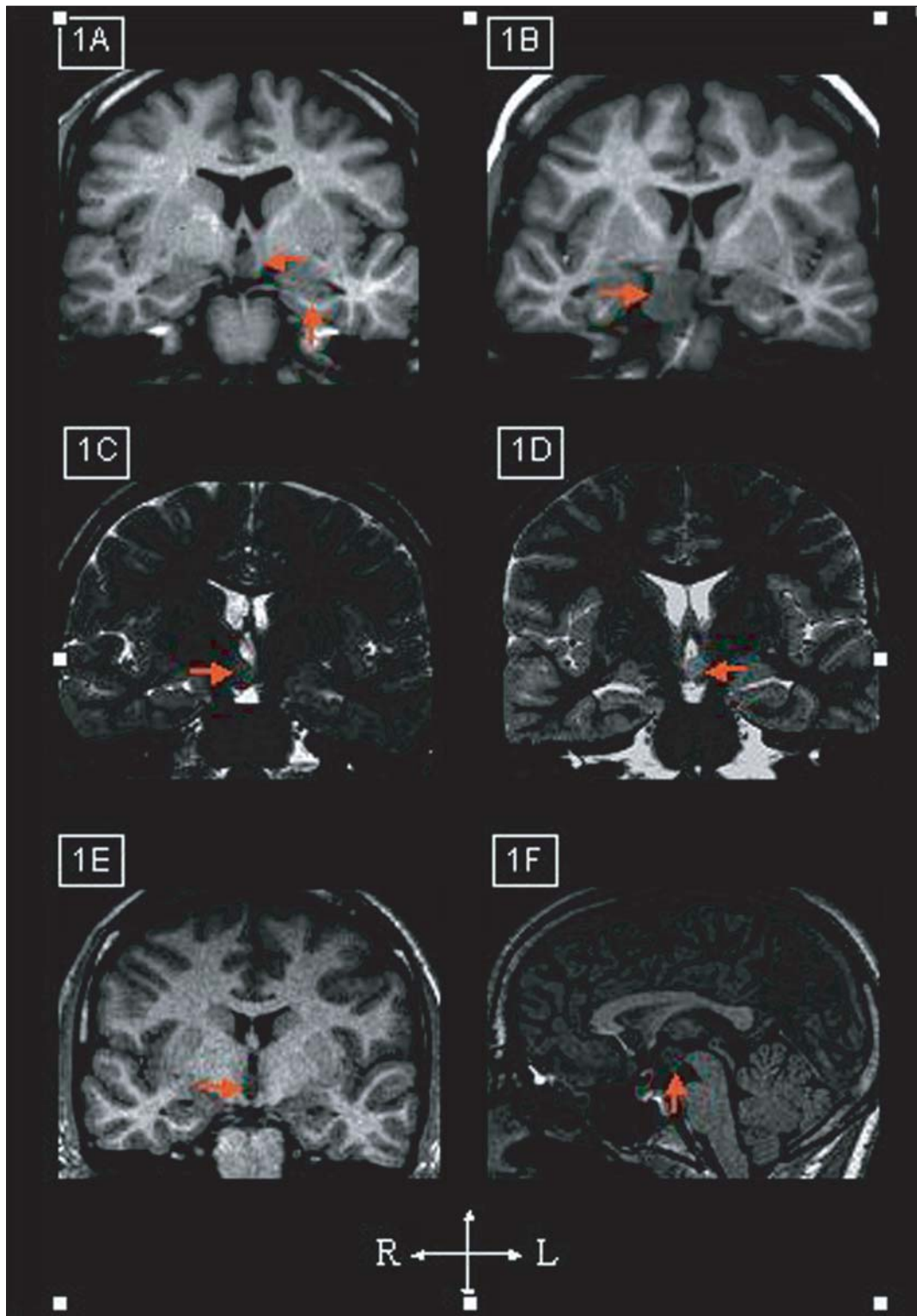


Figure 1. MRI findings.

A) Patient No 1 showing a left-sided, intra-hypothalamic hamartoma associated with a subtle hippocampal asymmetry of uncertain significance; **B)** Patient No 2 showing a large, right-sided extra-hypothalamic hamartoma; **C)** Patient No 3 showing a right-sided, intra-hypothalamic hamartoma; **D)** Patient No 4 showing a left-sided, intra-hypothalamic hamartoma; **E)** and **F)** Patient No 5 showing a right-sided, intra-hypothalamic hamartoma on both coronal and sagittal T1 sequences.

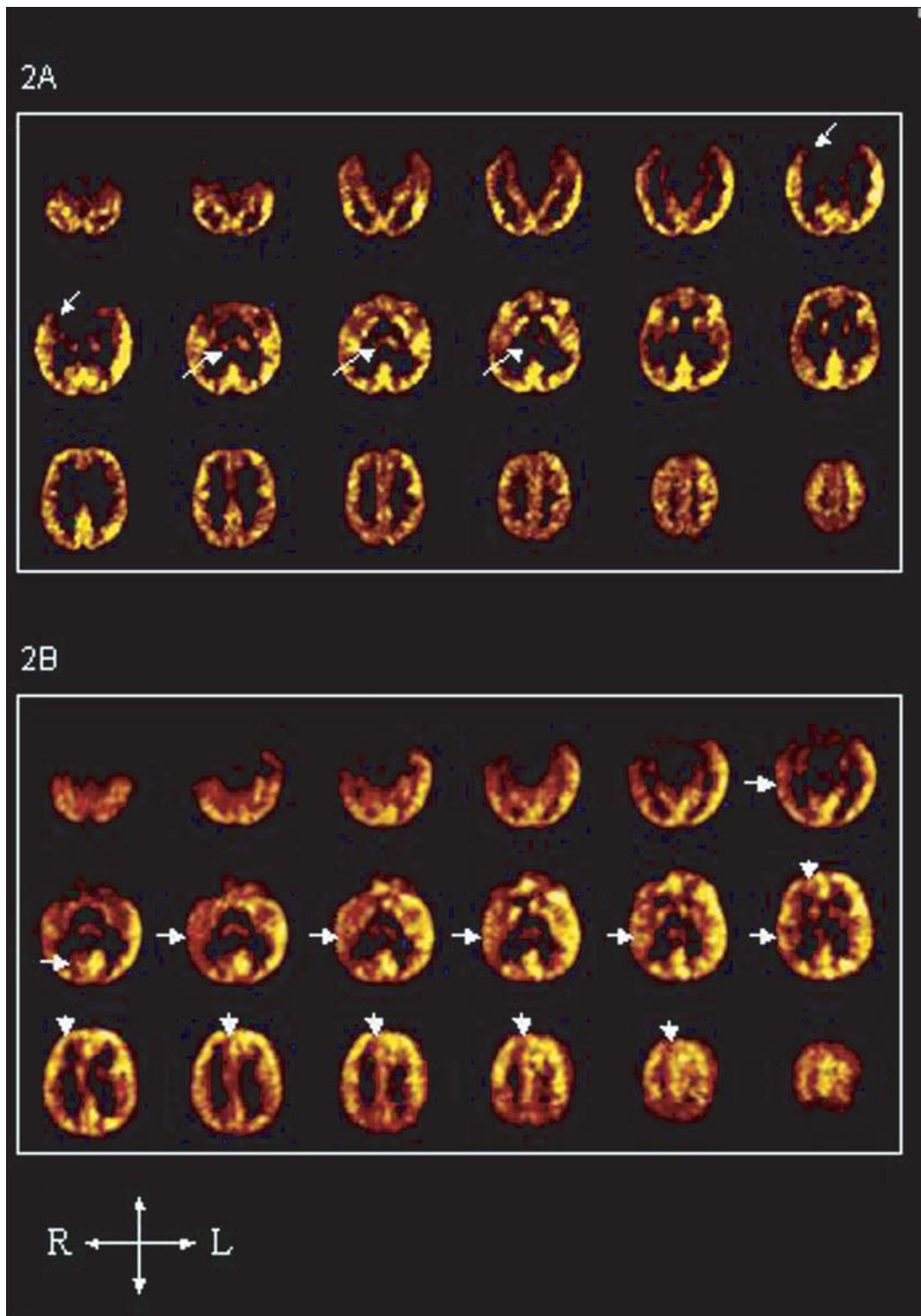


Figure 2. FDG-PET.

A) Patient No 2 demonstrated right thalamic and, to a lesser extent, right temporo-polar hypometabolism. **B)** Patient No 3 showed an extensive, right hemispheric hypometabolism, involving the lateral temporal cortex, the orbito-frontal and fronto-polar cortex, the peri-sylvian region, and the mesial and lateral occipital lobe.

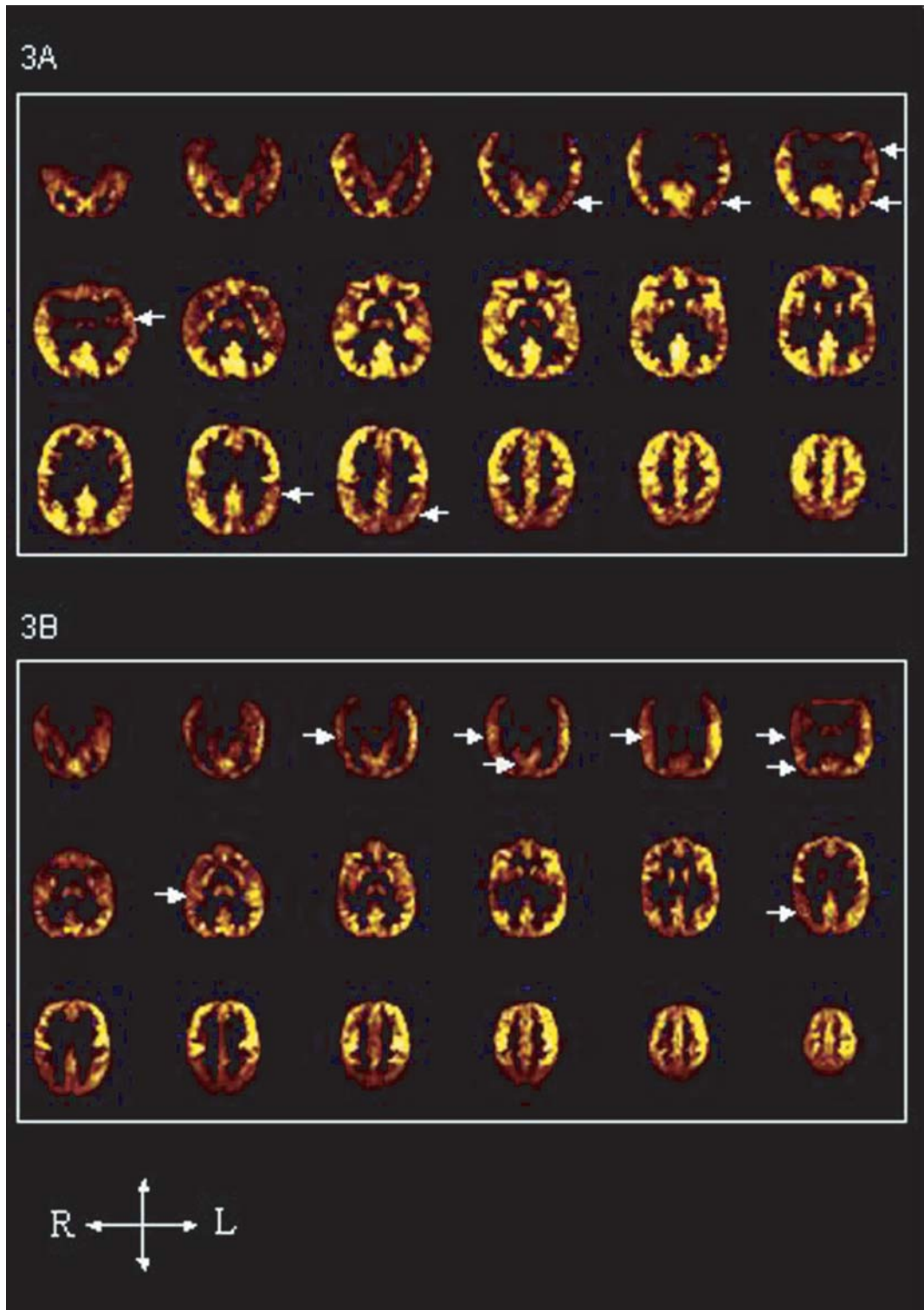


Figure 3. *FDG-PET.* **A)** Patient No 4 demonstrated left, lateral, temporo-occipital hypometabolism, but also left parietal abnormalities; **B)** Patient No 5 showed an extensive, right hemispheric hypometabolism, involving the lateral temporal cortex, the TPO junction, and the inferior parietal lobule.

consisted of well-lateralized focal or multifocal hypometabolic zones, the pattern of which varied considerably from one patient to the other (see *table 2*).

The hypometabolic areas were always ipsilateral to the predominant EEG abnormalities, and to the HH. They also grossly matched part of the cortical areas considered as being most affected in each individual patient.

Patient No 1, whose left temporal lobe appeared predominantly involved during seizures, had a left mesial temporal hypometabolism.

Patient No 3, with electro-clinical findings pointing to the right frontal lobe, showed right frontal, but also right temporal and occipital hypometabolism.

In patient No 4, both EEG and FDG-PET pointed to the left temporo-occipital regions.

Patient No 5, whose electro-clinical data were poorly localising but yet consistent with a predominantly right temporo-occipital or inferior parietal involvement, had a right temporo-parietal hypometabolism. There were discordant findings, however, *in patient No 2* whose intracranial EEG investigation pointed to a right fronto-centro-temporal region (excluding mesio-temporal lobe structures and the temporal pole), whereas PET demonstrated ipsilateral thalamic, and possibly temporo-polar, hypometabolism.

There was no clear association between the presence of extensive hypometabolism and behavioural or neuropsychological disorders, but the sample size was small and PET findings heterogeneous.

Discussion

To our knowledge, this is the first series to investigate FDG-PET in epileptic patients with hypothalamic hamartoma. Our main finding is that such patients usually present one or several hypometabolic areas in the hemisphere predominantly affected by the interictal and ictal epileptiform discharges. The anatomical pattern of FDG-PET abnormalities, like that of electro-clinical findings, varied greatly from one patient to another. In fact, the lobar distribution of hypometabolism tended to grossly match that of the cortical network suspected to be predominantly involved during non-gelastic seizures, although some discordances were observed. Two independent case reports of FDG-PET in epileptogenic hypothalamic mass or HH have been previously published, and agree with our findings [12, 17]. One of the two patients presented with a temporal lobe hypometabolism ipsilateral to a non-specified hypothalamic mass [17], whereas the other demonstrated a left, temporal lobe hypometabolism consistent with the scalp and epidural strip-EEG findings [12]. This latter patient continued to suffer gelastic seizures after a left, temporal lobectomy [12]. Interestingly, our series provides the first evidence of extra-temporal cortical hypometabolism associated with epileptogenic HH.

Several limitations of our study must be pointed out. Firstly, only scalp EEG data were available in four patients, the localizing value of which is usually poor in HH associated seizures. Thus, the conclusion as to which cortical areas were most affected during the recorded seizures remains doubtful, although usually consistent with the ictal semiology. This limitation seems to have much less

Tableau 2. Comparative lateralization and localization of clinical, MRI, EEG and PET data.

Patient N°	Lateralizing data				Localizing data	
	Hamartoma	EEG	Metabolic	Ictal semiology (by order of appearance)	EEG	Metabolic
1	Left	Left	Left	± pressure to laugh rising epigastric sensation throat discomfort dreamy state	Interictal: non-localizing Ictal: temporal and central	Mesial temporal
2	Right	Right	Right	Rising thoracic warm feeling, auditory illusions, dizziness, left leg painful sensation, left facial contraction left hemibody hypertonia	Interictal: non-localizing Ictal: temporo-fronto-central	Thalamic ± temporo-polar
3	Right	Right	Right	Laughter left hemibody tonic-clonic post-ictal left sided Todd's paralysis	Interictal: fronto-temporal Ictal: frontal	Fronto-temporal + occipital
4	Left	Left	Left	Rising thoracic heat sensation blush, smile or laughter spatial disorientation	Interictal: temporo-occipital Ictal: non localizing	Temporo-occipital
5	Right	Right	Right	Right-sided gyration secondary generalisation	Interictal: non-localizing Ictal: non-localizing	Temporo-parietal

impact on the identification of the predominantly involved hemisphere, according to the consistent lateralization found between electro-clinical, MRI and PET findings in this series, as well as in previously published case reports. Another limitation is represented by the lack of quantitative assessment of the PET data. Visual analysis of FDG-PET asymmetry has proved to be a very sensitive and reliable tool for assessing individual epileptic patients. However, it is not appropriate for detecting bilateral abnormalities, nor for investigating group effect, within a homogeneous patient population. In any event, HH-related, bilateral hypometabolism would be difficult to assess due to the young age of some patients for whom no control data is available, and to the confounding effect of anti-epileptic drugs [26-29]. Similarly, looking for a group effect in a limited number of patients who demonstrate strikingly different metabolic patterns on visual analysis, seems unlikely to disclose pertinent findings.

The relation observed between the anatomical distribution of metabolic and EEG abnormalities, deserves several comments. The lack of a perfect match between the two might be due to factors other than the limitations of our analysis. Indeed, in neocortical epilepsies, areas of maximal hypometabolism appear to more closely match the border separating the normal cortex from the epileptogenic zone, than the seizure, onset zone proper [30]. More generally, the origin of metabolic abnormalities in epileptic disorders remains uncertain and likely to be multifactorial, depending on various parameters such as seizure frequency, duration of epilepsy, and the associated MRI and EEG changes [31-39]. Nevertheless, the presence of lateralized hypometabolism grossly concordant with EEG data in patients with epileptogenic HH, reinforces the view that localized cortical areas are affected in the course of the disease. This has been well demonstrated by intra-cranial EEG recordings, as discussed in detail in another article of this issue [22]. Whether the affected cortical areas represent independent epileptogenic zones, generated by a process of secondary epileptogenesis remains an open issue. The natural evolution of epileptogenic HH is often characterized by an initial period where only brief gelastic seizures are observed, typically followed, several years later, by the occurrence of new seizure types, some of which lack laughter [40]. This evolution suggests progressive kindling of various brain regions. In addition, complete resection of HH associated with multiple seizure types often leads to a complete seizure control [4-6, 8-9], indicating that the cortical areas involved in HH associated epilepsy do not usually develop as independent epileptogenic zones. Accordingly, the resection of these cortical areas alone, guided by intra-cranial EEG data, has proved ineffective [12]. However, complete resection of HH has not always enabled patients to achieve complete seizure freedom [6]. It is therefore possible that some individuals with HH develop a truly independent cortical epileptogenic zone, as suspected in patient No 2. In this

patient, intra-cranial EEG recordings demonstrated that a well-circumscribed hamartoma discharge was responsible for dacrystic seizures, whereas other complex partial seizures originated in the right temporo-fronto-central region without affecting the HH. This patient was not cured after two, unsuccessful attempts to fully remove the hamartoma, preventing us from determining whether the origin of the persisting seizures was the HH, the right temporo-fronto-central cortex, or both [22, 23]. Future studies might ultimately solve this issue, as well as the earlier recognition of HH-associated gelastic seizures and the development of safer and more effective neurosurgical procedures, which will probably result in more HH patients undergoing surgery before they develop catastrophic epilepsies.

The great anatomical variability of metabolic and electro-clinical abnormalities observed in our patients, as well as in other series, indicates that HH-associated seizures can follow multiple routes of propagation through the brain. The fact that the lateralization of hypometabolism always proved ipsilateral to EEG and MRI findings in our patients, suggests that the underlying process is not random, but rather depends on the connectivity of the hamartoma. Particularly, one may wonder whether the mamillo-thalamo-cingulate tract could relay the repetitive intra-hamartoma discharges, as indirectly suggested by the presence of thalamic hyperperfusion during gelastic seizures [3], and by our finding of lateralized, interictal, thalamic hypometabolism in one of our patient.

Finally, we could not correlate the extent of the metabolic abnormalities with the intensity of the behavioural and intellectual disabilities. Yet, no definite conclusion can be made regarding this issue, due to the very small number of patients of our series. Future PET studies are thus warranted with the hope of better understanding the complex pathophysiology of epileptogenic HH. □

References

1. Munari C, Kahane P, Francione S, *et al.* Role of hypothalamic hamartoma in the genesis of gelastic fits (a video-stereo-EEG study). *EEG Clin Neurophysiol* 1995; 95: 154-60.
2. Kahane P, Munari C, Minotti L, *et al.* The role of the hypothalamic hamartoma in the genesis of gelastic and dacrystic seizures. In: Tuxhorn I, Holthausen H, Boenigk K, eds, *Paediatric epilepsy syndromes and their surgical treatment*. London: John Libbey, 1997: 447-61.
3. Kuzniecky R, Guthrie B, Mountz J, *et al.* Intrinsic epileptogenicity of hypothalamic hamartomas in gelastic epilepsy. *Ann Neurol* 1997; 42: 60-7.
4. Delalande OR, Fohlen MJ, Jalin C, *et al.* Surgical treatment of epilepsy due to hypothalamic hamartoma: Technique and preliminary results in five cases. *Epilepsia* 1998; 39 (Suppl 6): 90-1.
5. Rosenfeld JV, Harvey AS, Wrennall J, Zacharin M, Berkovic SF. Transcallosal resection of hypothalamic hamartomas, with control of seizures, in children with refractory epilepsy. *Neurosurgery* 2001; 48: 108-18.

6. Palmini A, Chandler C, Andermann F, *et al.* Resection of the lesion in patients with hypothalamic hamartomas and catastrophic epilepsy. *Neurology* 2002; 58: 1338-47.
7. Berkovic SF, Arzimanoglou A, Kuzniecky R, Harvey AS, Palmini A, Andermann F. Hypothalamic hamartoma and seizures: a treatable epileptic encephalopathy. *Epilepsia* 2003; 44: 969-73.
8. Harvey S, Freeman JL, Rosenfeld JV, Berkovic S. Transcallosal resection of hypothalamic hamartomas in patients with intractable epilepsy. *Epileptic Disord* 2003; 5: 239-47.
9. Fohlen M, Lellouch A, Delalande O. Hypothalamic hamartoma with refractory epilepsy: Surgical procedures and results in 18 patients. *Epileptic Disord* 2003; 5: 267-73.
10. Kuzniecky R, Guthrie BL. Stereotaxic surgical approach in hypothalamic hamartomas. *Epileptic Disord* 2003; 5: 275-9.
11. Polkey C. Resective surgery for hypothalamic hamartoma. *Epileptic Disord* 2003; 5: 281-6.
12. Cascino GD, Andermann F, Berkovic SF, *et al.* Gelastic seizures and hypothalamic hamartomas: Evaluation of patients undergoing chronic intracranial EEG monitoring and outcome of surgical treatment. *Neurology* 1993; 43: 747-50.
13. Valdueza JM, Cristante L, Dammann O, *et al.* Hypothalamic hamartomas: With special reference to gelastic epilepsy and surgery. *Neurosurgery* 1994; 34: 949-58.
14. Machado HR, Hoffman HJ, Hwang PA. Gelastic seizures treated by resection of a hypothalamic hamartoma. *Child's Nerv Syst* 1991; 7: 462-5.
15. Nishio S, Morioka T, Fukui M, Goto Y. Surgical treatment of intractable seizures due to hypothalamic hamartoma. *Epilepsia* 1994; 35: 514-9.
16. Ryvlin P, Bouvard S, Le Bars D, *et al.* Clinical utility of Flumazenil-PET versus FDG-PET and MRI in refractory partial epilepsy: a prospective study in 100 patients. *Brain* 1998; 121: 2067-81.
17. Meyer MA. Temporal lobe hypometabolism ipsilateral to a hypothalamic mass. Relationship to gelastic seizures. *Clin Positron Imaging* 2000; 3: 75-7.
18. Berkovic SF, Andermann F, Melanson D, Ethier RE, Feindel W, Gloor P. Hypothalamic hamartomas and ictal laughter: evolution of a characteristic epileptic syndrome and diagnostic value of magnetic resonance imaging. *Ann Neurol* 1988; 23: 429-439.
19. Deonna T, Ziegler AL. Hypothalamic hamartoma, precocious puberty and gelastic seizures: a special model of "epileptic" developmental disorder. *Epileptic Disord* 2000; 2: 33-7.
20. Fratelli CM, Liow K, Korenman LM, *et al.* Cognitive deficits in children with hypothalamic hamartoma. *Neurol* 2001; 57: 43-6.
21. Weissenberger A, Dell M, Liow K, *et al.* Aggression and psychiatric comorbidity in children with hypothalamic hamartomas and their unaffected siblings. *J Am Acad Adolesc Psychiatry* 2001; 40: 696-703.
22. Kahane P, Ryvlin P, Hoffmann D, Minotti L, Benabid AL. From hypothalamic hamartoma to cortex: what did we learned from depth recordings and stimulation? *Epileptic Disorders* 2003; 5: 205-17.
23. Kahane P, Di Leo M, Hoffmann D, Munari C. Ictal bradycardia in a patient with a hypothalamic hamartoma: a stereo-EEG study. *Epilepsia* 1999; 40: 522-7.
24. Bancaud J, Talairach J, Munari C, *et al.* Introduction à l'étude clinique des crises épileptiques rétrorolandiques. *Can J Neurol Sci* 1991; 18: 566-9.
25. Vercueil L, Kahane P, Francois-Joubert A, *et al.* Basal ganglia involvement in rotational seizures. *Epileptic Disord* 1999; 1: 107-12.
26. Theodore WH, Bairamian D, Newmark ME, *et al.* Effect of phenytoin on human cerebral glucose metabolism. *J Cereb Blood Flow Metab* 1986; 6: 315-20.
27. Theodore WH, DiChiro G, Margolin R, *et al.* Barbiturates reduce human cerebral glucose metabolism. *Neurology* 1986; 36: 60-4.
28. Leiderman DB, Balish M, Bromfield EB, Theodore WH. Effect of valproate on human cerebral glucose metabolism. *Epilepsia* 1991; 32: 417-22.
29. Gaillard WD, Zeffiro T, Fazilat S, DeCarli C, Theodore WH. Effect of valproate on cerebral metabolism and blood flow: An (18)F 2 deoxyglucose and (15)O water positron emission tomography study. *Epilepsia* 1996; 37: 515-21.
30. Juhasz C, Chugani DC, Muzik O, *et al.* Is epileptogenic cortex truly hypometabolic on interictal positron emission tomography? *Ann Neurol* 2000; 48: 88-96.
31. Theodore WH, Fishbein D, Dubinsky R. Patterns of cerebral glucose metabolism in patients with partial seizures. *Neurology* 1988; 38: 1201-6.
32. Ryvlin P, Cinotti L, Froment JC, *et al.* Metabolic patterns of non specific magnetic resonance imaging abnormalities in temporal lobe epilepsy. *Brain* 1991; 114: 2363-83.
33. Ryvlin P, Philippon B, Cinotti L, *et al.* Functional neuroimaging strategy in temporal lobe epilepsy: a comparative study of 18FDG-PET and 99mTc-HMPAO-SPECT. *Annals of Neurology* 1992; 31: 650-6.
34. Leiderman DB, Albert P, Balish M, Bromfield E, Theodore WH. The dynamics of metabolic change following seizures as measured by positron emission tomography with fludeoxyglucose F18. *Arch Neurol* 1994; 51: 932-6.
35. Ryvlin P, Manguière F, Sindou M, Froment JC, Cinotti L. Interictal cerebral glucose metabolism and epilepsy in cavernous angiomas. *Brain* 1995; 118: 677-87.
36. Semah F, Baulac M, Hasboun D, *et al.* Is interictal temporal hypometabolism related to mesial temporal sclerosis? A positron emission tomography/magnetic resonance imaging confrontation. *Epilepsia* 1995; 36: 447-56.
37. Cornford EM, Gee MN, Swartz BE, *et al.* Dynamic [¹⁸F]fluorodeoxyglucose positron emission tomography and hypometabolic zones in seizures: reduced capillary influx. *Ann Neurol* 1998; 43: 801-8.
38. Koutroumanidis M, Binnie CD, Elwes RD, *et al.* Interictal regional slow activity in temporal lobe epilepsy correlates with lateral temporal hypometabolism as imaged with 18FDG PET: neurophysiological and metabolic implications. *J Neurol Neurosurg Psychiatry* 1998; 65: 170-6.
39. Choi D, Na DG, Byun HS, *et al.* White matter changes in mesial temporal sclerosis: correlation of MRI with PET, pathology, and clinical features. *Epilepsia* 1999; 40: 1634-41.
40. Berkovic SF, Kuzniecky RI, Andermann F. Human epileptogenesis and hypothalamic hamartomas: New lessons from an experiment of nature. *Epilepsia* 1997; 38: 1-3.