

Resective surgery for hypothalamic hamartoma

Charles E Polkey

Academic Neurosciences Centre Institute of Psychiatry, London, England

ABSTRACT – Hypothalamic hamartoma presents with precocious puberty, epilepsy or both. There are two epileptic syndromes, one presenting initially in infancy with gelastic seizures evolving rapidly into a syndrome with multiple seizures, developmental delay and a moderate to severe behaviour disorder. The other presents later with a milder epileptic syndrome, again usually including gelastic seizures, but with normal intellect and behaviour. Magnetic resonance imaging identifies and gives a detailed anatomical picture of these lesions. Direct surgery, using microsurgical techniques and neuronavigation guidance has been used for these lesions. Three surgical approaches have been used, one lateral pterional, another midline frontal through the lamina terminalis and a third is a transcallosal interforaminal approach. In addition a disconnection procedure, usually pterional, aims to disconnect the lesion without the risks of major resection. The transcallosal interforaminal approach is the most successful with 69% of patients seizure-free. There are complications in about 24% of patients, the same as other approaches, but the complications are milder and include fewer neurological deficits than the other routes. Alternate strategies include stereotactic radiosurgery and radiofrequency ablation under stereotactic control.

KEY WORDS: hypothalamic hamartoma, epilepsy, surgery, outcome, complications, children, gelastic epilepsy, precocious puberty, stereotactic radiosurgery

Hypothalamic hamartoma, as a cause of gelastic epilepsy, was first described in 1969 [1]. However, it was a difficult lesion to detect using neuro-imaging, especially when small, and it is only with the development and application of sophisticated MRI techniques that these lesions have become more easily recognised, and therefore interest in their management has increased. Apart from the surgical approach itself, their management is complex, requiring consideration of the mode of presentation and the epileptic syndrome. A study of 140 children with precocious puberty in India showed that 26 had a neurogenic origin, which was commoner in boys than girls, although precocious puberty as a whole was commoner in girls than boys, (4.4:1). Only nine of the 26 chil-

dren in this group had a hypothalamic hamartoma, the remainder had other conditions [2]. Patients with hypothalamic hamartoma and only precocious puberty, were the first patients to be operated upon with this lesion [3, 4]. Some of the patients with epilepsy had precocious puberty, and the epilepsy syndromes themselves vary. Some patients had late onset of a mild partial epilepsy with gelastic seizures, against a background of normal intellect and behaviour. In the most severe form, the onset of the epilepsy is early, often at birth, and although at first there may be only gelastic seizures the seizure disorder soon broadens with multiple seizure types, and in addition there is developmental delay and severe behavioural problems [5]. Nor is hypothalamic hamartoma the sole

Correspondence:

CE Polkey, MD FRCS Emeritus Professor of Neurosurgery
Academic Neurosciences Centre; Institute of Psychiatry
De Crespigny Park
Denmark Hill
London SE5 8AF
Tel: +44(0)2078485187
Fax: +44(0)2078485186

Presented at the International Symposium on Hypothalamic Hamartoma and Epilepsy, Montreal Neurological Institute, Montreal, Canada, November 29th 2001.

cause of gelastic seizures, and therefore it is necessary to demonstrate the origin of the seizures from the lesion. Finally, the evolution of the seizure disorder itself may influence the outcome of surgery.

Problems

The lesion

Demonstration of the lesion is not always easy and may require careful MRI examination with thin slice volume sequences to demonstrate small lesions. The lesion does not usually enhance with gadolinium. They also vary considerably in size and location, factors that determine the surgical approach. In particular, the relationship of the lesion to the hypothalamus, the interpeduncular cistern and the wall of the third ventricle are all important and need to be demonstrated by the imaging. Angiography may be necessary, in addition to careful MRI studies, to demonstrate the relationship between important vascular structures and the lesion, although these lesions are not hypervascular. The histology of these lesions is also relevant, they are often not sufficiently different from the surrounding tissue to allow neuropathologists to make a positive diagnosis from a smear or frozen section.

Epileptogenicity

StereoEEG recordings have shown that in some cases spikes and seizure initiation occurs within these lesions [6, 7]. Other investigators, including ourselves, have found that when an array of depth electrodes is used to investigate these patients, including one or more lesional electrodes, the picture can be quite complex and, to an extent, confusing. The Melbourne group has used ictal SPECT as a measure of the epileptogenicity of these lesions [8]. A recent paper has also shown that interictal EEG source analysis in four cases suggested that the majority of cortical spikes could be best explained by a deep source in the hamartoma [9]. The evolution of the syndrome is also important. In many patients, there are multiple seizure types and bilateral severe EEG abnormalities. Whether this is the consequence of a severe epileptic syndrome in the developing brain, or whether these patients have multiple structural abnormalities, including the hamartoma, as a cause of their epilepsy syndrome is not clear, and may not be of practical importance.

Age

Many of the patients, especially those with the more severe syndromes, present as infants or young children. Therefore, they have the additional difficulties associated with major intracranial surgery in this age group.

Approaches

The technical problem

Two technical supports are '*de rigueur*' in dealing with these lesions. The first is the use of an operating microscope, which with improved visualisation of detail and illumination of the operator's target, gives the surgeon the best chance of resecting the lesion. The second, especially important with the longer approaches, is some form of neuronavigation or frameless stereotaxy system which will both guide the operator to the lesion and permit some assessment of the amount of lesion removed. In general, when these lesions are encountered, they differ in consistency from the surrounding cerebral tissue and the resection is halted when it is no longer possible to make this distinction.

The anatomical problem

These lesions vary greatly in their size and location. A classification, originally proposed by Arita [10], distinguishes between pedunculated lesions, which hang down into the interpeduncular cistern, and sessile lesions that are confined to the hypothalamus. In practice, lesions may present a combination of these features. It is therefore appropriate to have more than one approach, although protagonists of each approach, particularly the transcallosal interforaminal approach, may assert that the majority of lesions can be dealt with in this way.

The interpeduncular cistern approach

This was the first approach described originally by Northfield in 1967, [3] and was devised to deal with pedunculated lesions, which were causing precocious puberty. The approach is through a temporal craniotomy, going down to the floor of the middle fossa, and unless the lesion is extremely asymmetric, which is unusual, from the non-dominant side, usually the right. To obtain more exposure, it may be justified to remove 1 - 2 cm of the temporal tip. An extension of access using an orbitocranial approach has also been described [11].

The advantages of this approach are the relatively short distance to the lesion and the relative ease of dividing the stalk of the lesion if it is narrow. The disadvantages are that it is necessary to manoeuvre past a number of important structures including the internal carotid artery and the optic nerve, chiasm and tracts. The third nerve also restricts access superiorly. Therefore, if there is a substantial sessile component within the floor of the third ventricle it will be impossible to resect it completely from this approach. If the lesion extends posteriorly, as with one of our cases, then deep branches from the posterior cerebral and basilar arteries may be a problem. Even with the assistance of neuronavigation, if the stalk of the lesion is broad, then it may be difficult to know when the capsule remote from the operator has been breached. Therefore, structures

which are close to the capsule, such as the opposite internal carotid artery, are in danger.

The lamina terminalis approach

It has been known for some time that access to lesions occupying the wall or floor of the third ventricle could also be obtained through the lamina terminalis. Through an appropriate craniotomy, usually on the non-dominant side, the frontal lobe is retracted and the anterior communicating artery sought by following the appropriate anterior cerebral artery. The lamina terminalis above the anterior communicating artery, can be opened without problems, which then gives access to the floor of the third ventricle. A significant lesion will usually be visible at this point and can then be resected [12]. The advantages of this approach are that it gives good visualisation of the lesion, and once the lamina terminalis is identified and passed, there are no crucial structures between the operator and the lesion. The disadvantages are that considerable retraction is needed resulting in frontal lobe damage, plus the hazards associated with operating around the anterior cerebral/anterior communicating complex. The approach is oblique and access to the more posterior and inferior parts of the lesion may be limited.

The transcallosal, interforaminal approach

This, the most elegant approach was first described for this condition by the Melbourne group [8]. Through an appropriate craniotomy, the operator uses an incision in the trunk of the corpus callosum to gain access to the lateral ventricle and thence the foramen of Monro. It is then necessary to enlarge the foramen by dividing between the fornices to gain access to the third ventricle and the lesion. The approach is almost vertical; the advantage is that it has been shown in practice to give access to all parts of these lesions. The surgeon is able to resect both the sessile (intra-hypothalamic) part of the lesion and also any extra-hypothalamic component whether within the third ventricle or protruding inferiorly into the interpeduncular cistern. There are few disadvantages, but the incision between the fornices can have cognitive disadvantages.

The disconnection approach

This has been used by Delalande, apparently from a subtemporal route [13]. The aim is to disconnect the bulk of the lesion from its connections to the hypothalamus, but not to remove the bulk of the lesion, thus avoiding risk to the surrounding structures in the interpeduncular cistern.

These approaches are summarised in *figure 1*. It must be clear from these descriptions that the best approach is the transcallosal, interforaminal approach, but in a minority of cases, the location of the lesion may indicate that one of the other approaches may be better.

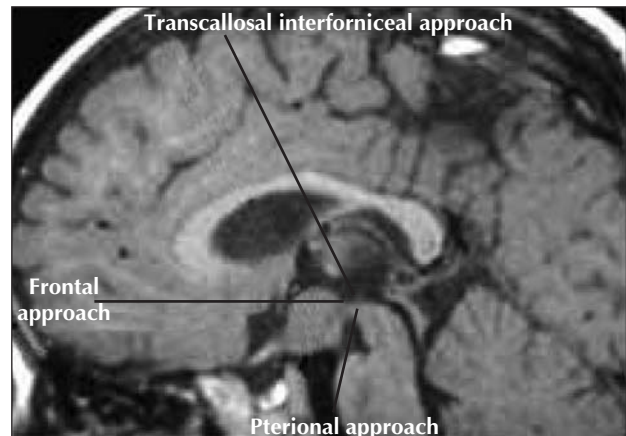


Figure 1. Summary of resective approaches to an hypothalamic hamartoma.

Outcome

There is a clear difference in outcome and complications, between patients treated for epilepsy and those treated for precocious puberty alone. This is, in large part due to the location of the lesions. Arita *et al.* classified the lesions found in 11 children. In seven, they were parahypothalamic, and these were all patients with only precocious puberty. In the remaining four cases they were intra-hypothalamic and these were the cases with the epilepsy syndrome [10]. Similar findings were reported by Debenix *et al.* in an analysis of 19 cases [14], in six children reported from China [15] and in a mixed group reported by Mottolese and colleagues in which the patients treated for precocious puberty did best and had pedunculated lesions [16]. In essence, all the patients treated for precocious puberty had a good result, with resolution of the syndrome in the majority and a low complication rate.

There are three substantial series of patients treated with resection. There is a multicentre study of 13 patients published by Palmiini *et al.* [7]. All had gelastic, complex partial and generalised seizures, with drop attacks in eight patients. Four patients had precocious puberty. All had marked behavioural and cognitive difficulties. Virtually all of the lesions had a sessile intra-hypothalamic component. A number of different surgical approaches were used. In the majority, the initial approach was by a fronto-temporal craniotomy and pterional approach. In five patients, a second procedure was required, and in at least two of these patients it was by a midline frontal approach via the lamina terminalis. Seizure outcome was assessed with follow-up periods of 1.5 - 6 years. Two patients were seizure-free and the remaining 11 patients had all achieved either freedom from or a 90% reduction in drop attacks and generalised tonic-clonic seizures. Minor gelastic seizures, complex partial seizures and atypical absence seizures persisted, although markedly reduced in

Table 1. Results of surgery and gamma knife therapy in the treatment of epilepsy due to hypothalamic hamartoma

Series	No	1A	3A + (improved)	3B- (not improved)	Complications
Rosenfeld (17)	28 (21)	14 (67%)	5 (24%)	2 (9%)	5 (24%)
Palmini <i>et al.</i> (7)	13	2 (15%)	11 (85%)		7 (54%)
Fohlen <i>et al.</i> (13)	13	5 (38%)	7 (54%)	1 (8%)	3 (23%)
Regis <i>et al.</i> (19)	10 (8)	4 (25%)	2 (25%)	2 (25%)	1 (10%)

Notes: figure in brackets indicates the number of patients available for follow-up. Complications – estimate of the permanent complications without specifying precisely, includes all complications mentioned in text.

frequency, in these 11 patients. Most patients had a dramatic improvement in behaviour and cognition.

In four patients, there were capsular infarcts, one after a second surgery, all resolved to leave a minor deficit or no deficit. One patient had a homonymous field defect after a second operation. Four patients had a third nerve paresis, all of which recovered. There was one case of hyperphagia [7].

A French series, initially reported only in abstract, describes 13 patients treated with a combination of resection and disconnection. The disconnection is primarily through the interpeduncular cistern. Five patients became Engel 1, seven patients in class 2 or 3 and one patient in class 4. One patient had a transient hemiparesis and third nerve palsy, one a permanent hemiparesis and one an asymptomatic frontal infarct [13]. Follow-up and new patients in this series are reported in this volume (Fohlen *et al.* 2003).

The transcallosal interforaminal approach has been used in Melbourne, and the last report describes 28 patients [17]. All had intractable epilepsy, with symptomatic generalised epilepsy in 21 cases, gelastic and partial epilepsy in five cases and gelastic seizures only in two cases. Seizure onset was neonatal in 15 cases. There had been previous surgery to the lesion in eight cases, radiofrequency lesioning in three cases, gamma knife surgery in one case. Twelve patients had precocious puberty, 18 intellectual impairment and 19 had a behavioural disturbance, 12 of whom had autistic traits. In 16 patients, more than 95% of the tumour was resected, in the remaining 12 patients 25 - 95% of the lesion was resected with disconnection in 12 patients, near complete in four.

Follow-up of 8-57 months was available for 21 patients. Fourteen patients were completely seizure-free (67%) and five had a better than 95% reduction in their seizure frequency (24%). Early complications included hypernatraemia, somnolence, temperature instability, small thalamic infarct, low thyroxine, low growth hormone and anxiety and depression. These all settled with time. In 12 patients, there was appetite stimulation, which remained in five patients, and short-term memory disturbance in 13 cases, which persisted to a mild extent in three patients. Results on this series are updated in this volume (Harvey *et al.* 2003).

A summary of the seizure outcome from these series and radiosurgery are presented in *table 1*.

Discussion

In treating patients with precocious puberty alone, where the lesions are mostly within the interpeduncular cistern, the pterional approach seems to give the best result with a high chance of relieving the endocrine syndrome and with few complications.

Operations directed to targets other than the lesion, such as temporal lobectomy and callosotomy are recognised to be unsuccessful. Therefore, the direct approach to the lesion has to be considered.

The results from the various surgical techniques for treating the hamartoma directly in patients with epilepsy clearly suggest that the transcallosal interforaminal approach has the highest success rate. The complication rate, though not insignificant, is nevertheless better than that seen with other approaches. This lower complication rate is probably because it gives excellent access whilst avoiding major vascular targets with their accompanying smaller but important branches, in particular the internal carotid, in some cases the basilar artery and certainly the anterior cerebral complex. However, it does not explain the higher seizure relief outcome, especially as in their 2001 abstract, the group explain that seizure outcome is not related to completeness of removal [18]. Perhaps two or three other factors may explain the improved result. They were very strict about demonstrating that the seizures arose from the lesion, using mostly ictal SPECT, their patients were all in a young age group, the oldest operated upon was 10 years of age, and they had observed that patients with generalised seizures did less well (personal communication). Therefore, it seems reasonable to infer that except in those cases where such an approach is clearly wrong, the transcallosal interforaminal approach is to be preferred. Purely pedunculated interpeduncular lesions are in the minority in this group of patients. It also seems reasonable to infer that the earlier this treatment is applied, before the epilepsy syndrome has diversified, the more likely it is to be successful. This is particularly apposite because it is clear from all the series that the other

benefits such as improved behaviour, intellectual performance and quality of life depend upon relief of the seizure disorder.

The alternative treatments also need to be considered. There are anecdotal accounts of the use of the gamma knife in the treatment of these lesions, but Regis has reported a multicentre study of ten patients [19], the treatment is not easy because, as Regis observes, the 50% isodose field is constrained by surrounding structures such as the optic apparatus. In the multicentre study, ten patients were treated who are comparable in age, symptomatology etc, with the surgical series already discussed. All the lesions were sessile; the mean age at treatment was 13.5 years (range 1-32 yrs). There are ten patients, eight of whom are available for follow-up with a mean of 35 months (range 12-71 months). Four patients were seizure-free, one had rare nocturnal seizures, one had rare partial seizures and the remaining two patients had an improvement in seizure control. The only morbidity was one patient who had poikilothermia. Improvements in behaviour were also evident. Radiosurgery, at present, does seem to have a significant effect in these patients, with seizure relief that is not quite as good as the transcallosal interforniceal approach, but with fewer complications and without the problems associated with major intracranial surgery.

This treatment and the alternative described thereafter do not give the opportunity to establish the nature of the lesion, which is implicit in the resective surgical approaches, where a specimen suitable for neuropathological examination is obtained. The MRI appearance of these lesions is characteristic and static, but in cases of doubt, a stereotactic biopsy might be appropriate and is relatively safe.

This raises a final question regarding the size of these lesions. Although neuronavigation is now extremely accurate, nevertheless when it comes to finding and removing lesions less than 5 mm this may be difficult. By contrast, there are accounts of the use of stereotactic radiofrequency lesioning of these hamartomas [20]. In our own experience, this has been a useful technique in two patients who were unwilling to undergo major surgery, in one of whom the lesion was small and mostly in the wall of the third ventricle.

Conclusions

Hypothalamic hamartoma is the cause of a devastating epilepsy syndrome, which can be treated by resective surgery.

This surgery is only effective when directed to the lesion itself.

The best approach is the transcallosal interforniceal approach, first described by the Melbourne group.

In rare cases, the location of the lesion may favour an alternative surgical approach.

Radiosurgery using the gamma knife may be a reasonable alternative in a significant number of cases. □

References

1. Paillas JE, Roger J, Toga M, *et al.* [Hamartoma of the hypothalamus. Clinical, radiological and histological study. Results of excision]. *Rev Neurol (Paris)* 1969; 120: 177-94.
2. Bajpai A, Sharma J, Kabra M. Precocious puberty: clinical and endocrine profile and factors indicating neurogenic precocity in Indian children. *J Pediatr Endocrinol Metab* 2002; 15: 1173-81.
3. Northfield DW, Russell DS. Pubertas praecox due to hypothalamic hamartoma: report of two cases surviving surgical removal of the tumour. *J Neurol Neurosurg Psychiatry* 1967; 30: 166-73.
4. Albright AL, Lee PA. Neurosurgical treatment of hypothalamic hamartomas causing precocious puberty. *J Neurosurg* 1993; 78: 77-82.
5. Berkovic SF, Andermann F, Melanson D, Ethier RE, Feindel W, Gloor P. Hypothalamic hamartomas and ictal laughter: evolution of a characteristic epileptic syndrome and diagnostic value of magnetic resonance imaging. *Ann Neurol* 1988; 23: 429-39.
6. Kahane P, Di Leo M, Hoffmann D, Munari C. Ictal bradycardia in a patient with a hypothalamic hamartoma: a stereo-EEG study. *Epilepsia* 1999; 40: 522-7.
7. Palmieri A, Chandler C, Andermann F, *et al.* Resection of the lesion in patients with hypothalamic hamartomas and catastrophic epilepsy. *Neurology* 2002; 58: 1338-47.
8. Rosenfeld JV, Harvey AS, Wrennall J, Zacharin M, Berkovic SF. Transcallosal resection of hypothalamic hamartomas, with control of seizures, in children with gelastic epilepsy. *Neurosurgery* 2001; 48: 108-18.
9. Leal AJ, Passao V, Calado E, Vieira JP, Silva Cunha JP. Interictal spike EEG source analysis in hypothalamic hamartoma epilepsy. *Clin Neurophysiol* 2002; 113: 1961-9.
10. Arita K, Ikawa F, Kurisu K, *et al.* The relationship between magnetic resonance imaging findings and clinical manifestations of hypothalamic hamartoma. *J Neurosurg* 1999; 91: 212-20.
11. Siomin V, Spektor S, Beni-Adani L, Constantini S. Application of the orbito-cranial approach in pediatric neurosurgery. *Childs Nerv Syst* 2001; 17: 612-7.
12. Watanabe T, Enomoto T, Uemura K, Tomono Y, Nose T. [Gelastic seizures treated by partial resection of a hypothalamic hamartoma]. *No Shinkei Geka* 1998; 26: 923-8.
13. Fohlen M, Jalin C, Delalande O. Surgical treatment of hypothalamic hamartoma in children with refractory epilepsy. *Epilepsia* 2000; 41, S183.
14. Debeneix C, Bourgeois M, Trivin C, Sainte-Rose C, Brauner R. Hypothalamic hamartoma: comparison of clinical presentation and magnetic resonance images. *Horm Res* 2001; 56: 12-8.
15. Luo S, Li C, Ma Z, Zhang Y, Jia G, Cheng Y. Microsurgical treatment for hypothalamic hamartoma in children with precocious puberty. *Surg Neurol* 2002; 57: 356-62.
16. Mottolese C, Stan H, Bret P, Berlier P, Lapras C. Hypothalamic hamartoma: the role of surgery in a series of eight patients. *Childs Nerv Syst* 2001; 17: 229-36.

17. Rosenfeld JV. James IV Lecture. Epilepsy surgery, hypothalamic hamartomas and the quest for a cure. *J R Coll Surg Edinb* 2002; 47: 653-9.
18. Harvey AS, Freeman JL, Rosenfeld JV, Zacharin M, Wrennall JA, Bailey C, *et al*. Postoperative course and seizure outcome following transcallosal resection of hypothalamic hamartoma in seventeen children with intractable gelastic epilepsy. American Epilepsy Society, Philadelphia, 2001 (*conference abstract*).
19. Regis J, Bartolomei F, de Toffol B, *et al*. Gamma knife surgery for epilepsy related to hypothalamic hamartomas. *Neurosurgery* 2000; 47: 1343-51.
20. Parrent AG. Stereotactic radiofrequency ablation for the treatment of gelastic seizures associated with hypothalamic hamartoma. Case report. *J Neurosurg* 1999; 91: 881-84.