

Senile myoclonic epilepsy in Down syndrome: a video and EEG presentation of two cases

Roberto De Simone^{1,2}, Géraldine Daquin², Pierre Genton²

¹ Department of Neurology, S. Eugenio Hospital, Rome, Italy

² Centre Saint Paul, Hôpital Henri Gastaut, Marseille, France

Received February 2, 2006; Accepted May 19, 2006

ABSTRACT – Myoclonic epilepsy is being increasingly recognized as a late-onset complication in middle-aged or elderly patients with Down syndrome, in association with cognitive decline. We show video and EEG recordings of two patients, both aged 56 years, diagnosed with this condition. At onset, myoclonic epilepsy in elderly DS patients may resemble, in its clinical expression, the classical juvenile myoclonic epilepsy with the characteristic occurrence of jerks on awakening. It is clearly associated with an Alzheimer-type dementia, and may also occur in non-DS patients with Alzheimer's disease: hence the possible denomination of "senile myoclonic epilepsy".

[Published with video sequences]

Key words: senile myoclonic epilepsy, Down syndrome, generalized epilepsy, Alzheimer's disease, myoclonic jerks

Epilepsy is recognized as a significant cause of additional handicap and morbidity in Down syndrome (Veall 1974, Stafstrom *et al.* 1988, 1991, Van Allen *et al.* 1999). Specific forms of epilepsy may be found with a high prevalence at various ages in Down syndrome (DS) patients, including infantile spasms (Tatsuno *et al.* 1984, Stafstrom 1993), reflex seizures and epilepsies (Guerrini *et al.* 1990), and a sharp increase in the incidence of epilepsy with age has been stressed repeatedly (Pueschel *et al.* 1991, McVickers *et al.* 1994) reported. Indeed, elderly patients with DS survive today because of increasing quality of medical and social care. The increased number of elderly DS patients has brought to

light late onset complications of this condition, which include dementia (Mann 1993), and a specific type of myoclonic epilepsy that is associated with cognitive decline and which we have observed repeatedly since our first publication on "senile myoclonic epilepsy" (Genton and Paglia 1994). This condition has also been reported as late onset myoclonic epilepsy in DS (Li *et al.* 1995, Möller *et al.* 2001, 2002).

Patients and methods

Two patients with DS were diagnosed with myoclonic epilepsy at the Centre Saint Paul-Hôpital Henri Gastaut,



Correspondence:

R. De Simone,
Viale Cesare Pavese 32,
00144 Rome,
Italy
<r.desimone@libero.it>

Marseille, in 2004. In both, the characteristic myoclonic jerks were recorded by means of a digital video-EEG system (Deltamed) with polygraphy (EEG recording according to the 10-20 international system with surface EMG of at least both deltoid muscles).

Case 1 - born in 1948 (video, patient 1)

This woman was first referred to the Centre Saint Paul in 1981, at age 33 years, because of a few presumably complex partial seizures, with interictal focal EEG anomalies over the left temporal region. These seizures were not documented further. She was given carbamazepine (CBZ) 400 mg/d, with a full control of seizures until withdrawal in 1994; she was no longer referred to our center for epilepsy. She lived in a special home for the handicapped, and had neither a family history of epilepsy nor other organic complications of DS. From 1998, she showed a progressive deterioration of cognitive functions – memory, concentration, orientation, and behaviour. She was seen in September 1998, and Alzheimer’s dementia (AD) was diagnosed. She was given piracetam 1600 mg/d without major effect. She was seen again in January 2001, and

further cognitive decline was noted; the EEG evidenced slight diffuse slowing without epileptiform changes. Segmental and diffuse myoclonus, involving arms and legs, face and trunk, was noted with increasing frequency by her carers in late 2004. In December 2004, she was referred again because the jerks had increased in frequency and intensity, becoming debilitating, following a prescription by her home physician of CBZ 400 mg/d, paroxetine 20 mg/d and hydroxyzine 90 mg/d. The jerks occurred systematically at morning awakening, and occasionally at other times of the day. The video-EEG performed showed isolated spikes and fast spike-waves (SW), especially evident over the central regions (*figure 1*). Some generalized SW were associated with bilateral myoclonic jerks, while segmental jerks occurred without clear EEG changes. Photic stimulation increased jerks with maximum effect at 10-15 Hz. CBZ was withdrawn, and levetiracetam (LEV) 1000 mg/d was given, with a clear improvement of jerks that became less frequent and less debilitating. At the last telephone contact (September 2005), we were informed that her cognitive deterioration was slowly progressing, and that the jerks persisted at a minor level. There was no other type of seizure.

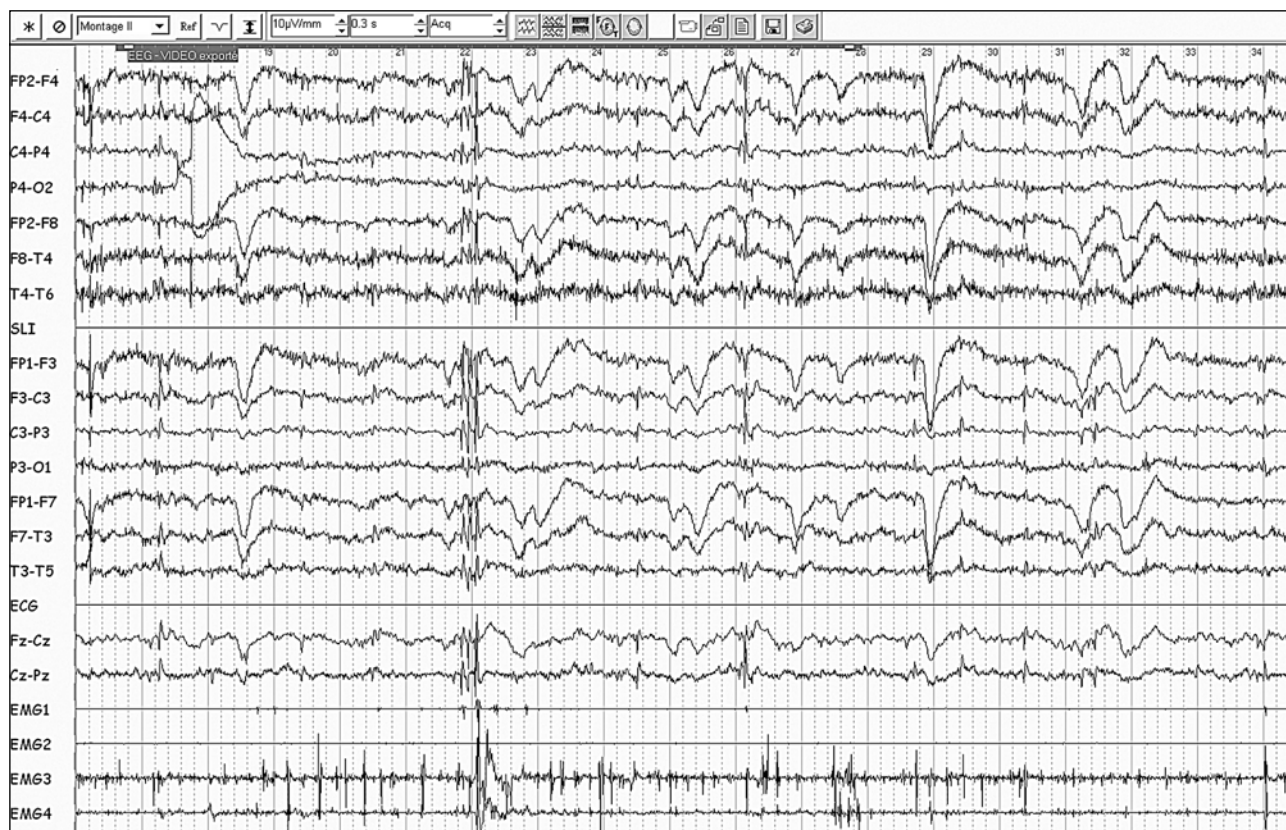


Figure 1. Patient 1. Polygraphic EEG with four EMG channels (right and left deltoids; right forearm extensor and flexor muscles) recorded around 11 AM. Presence of multiple myoclonic jerks, coupled inconsistently to diffuse fast spike and spike-wave discharges, with predominance on central and vertex regions. Only the bilateral myoclonic jerks appear to be associated with diffuse EEG changes.

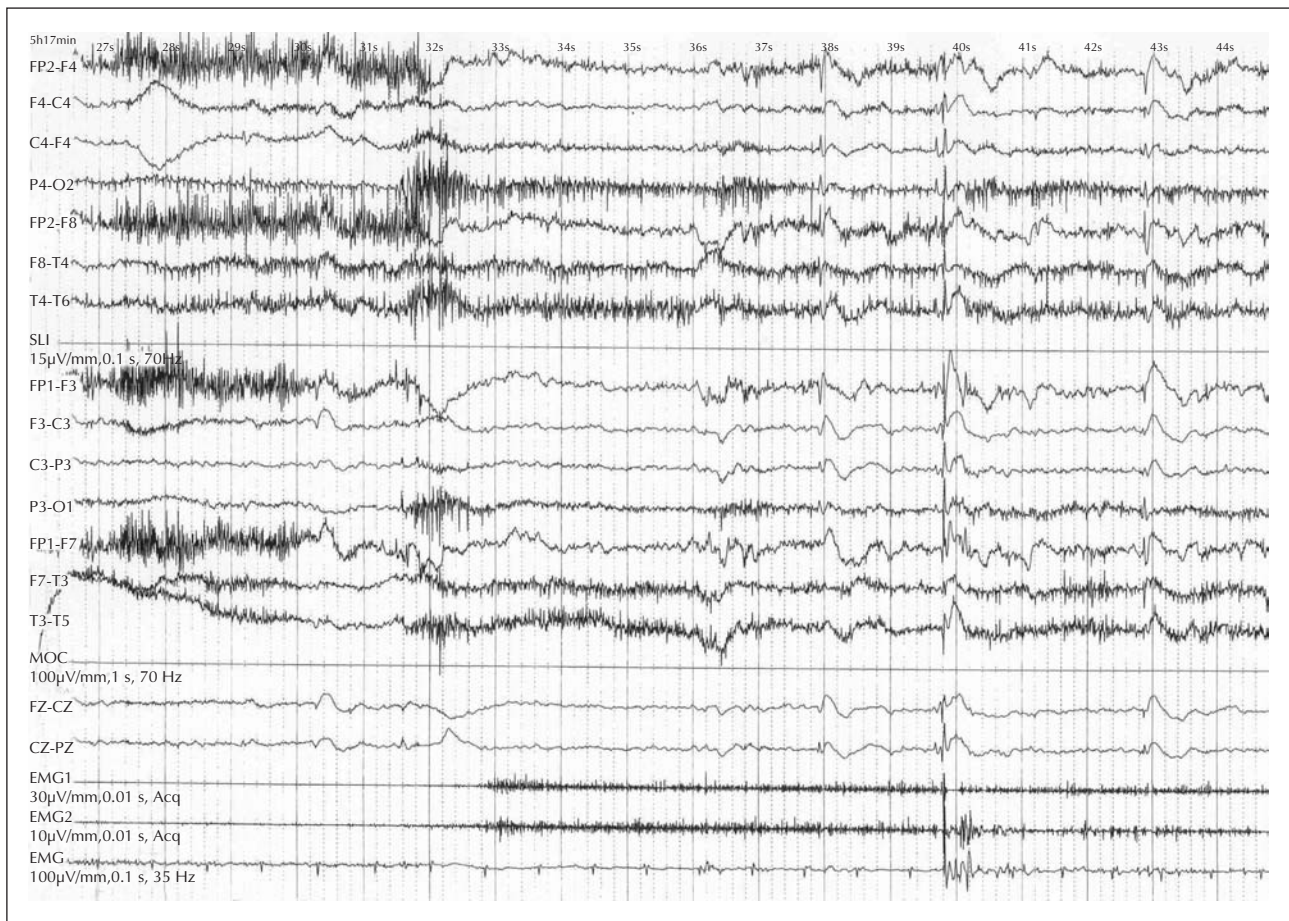


Figure 2. Patient 2. Polygraphic EEG with EKG and EMG (both deltoids) recorded soon after morning awakening. Evidence of three successive diffuse spike-wave discharges; only the second, which has the highest amplitude and most generalized aspect, is coupled to a massive, bilateral myoclonic jerk, followed by a brief atonia.

Case 2 - born in 1948 (video, patient 2)

This man was referred in 2004 at age 55 years. History taking revealed that he had no personal or familial history of epilepsy, and no other complication of DS forepart from hypothyroidism diagnosed the same year and controlled with L-thyroxine. In 2000, he developed a progressive cognitive deterioration, characterized by apraxia, loss of memory, and disorientation. A brain MRI showed mild brainstem and sub-cortical atrophy. Blood examination showed a folate deficiency which was treated with 5 mg/d folic acid. Treatment with donepezil brought some initial benefit, but the cognitive decline progressed. In October 2003, erratic and massive myoclonus appeared, occurring mostly on awakening, and often causing falls. A generalized tonic-clonic seizure (GTCS) occurred in January 2004 and resulted in hospitalization in a local hospital. CBZ was prescribed, with no improvement of the myoclonus, and was stopped after two months. There were no further GTCS.

He was referred to us in October 2004: a full-night video-EEG showed diffused spike-wave complexes predominant in frontal regions, occurring in all sleep stages as isolated and subclinical events, but after awakening, numerous, often violent myoclonic jerks were recorded (*figure 2*). Myoclonus could be erratic, on both sides, or axial, positive or negative. Valproate (VPA) 1000 mg/d, was prescribed, with a moderate improvement of jerks. At the last telephone contact (September 2005), we were informed that his cognitive deterioration was still slowly progressing, and that the jerks persisted but caused less impairment. There was no other type of seizure.

Discussion

Both patients experienced the onset of segmental and massive incapacitating myoclonic jerks, predominating after the morning arousal that began progressively three to six years after the onset of a progressive and global cognitive impairment. In both cases, the jerks were apparently

increased or revealed by a low-dose treatment with CBZ, but persisted and progressed in intensity after CBZ was discontinued. Patient 2 experienced a single GTCS. LEV and VPA were given because of their well-known broad-spectrum effect. In both patients, the jerks subsided partially on LEV and VPA, respectively, while the cognitive deterioration continued to progress.

The clinical picture and the overall evolution of our patients are in accordance with what is reported by other authors. Veall (1974) in his study of 1654 patients with DS, showed an increased prevalence of epilepsy with increasing age (1.9% under 20 years and 12.2% over 55 years), and underlined the absence of an obvious cause of epilepsy. After a follow-up of 12 years, 36.8% of DS subjects experience epilepsy (Van Allen *et al.* 1999). Many authors agree on a bi- or triphasic distribution of epilepsy according to age in DS: Puschel *et al.* (1991), in a study of 405 patients aged 0.5 to 45 years, suggested a triphasic distribution: infancy, early adulthood, and a special epilepsy in patients over 50-55 years. McVickers *et al.* (1994) have reported, in a population of 191 DS patients, a prevalence of epilepsy of 9.4%, increasing to 46% in those over 50 years.

In late stages of DS, myoclonus may become the most characteristic epileptic symptom. A report published in abstract form (Pedersen, 1990) mentioned that elderly DS patients could present myoclonic jerks, with normal EEGs. More recently, several authors (Genton and Paglia, 1994, Li *et al.* 1995, Möller *et al.* 2001, 2002) have described a form of late epilepsy in DS, characterized by seizure onset after the fourth decade, myoclonic jerks, occasional tonic-clonic seizures, and progressive dementia, identified either as "senile myoclonic epilepsy" or as "late-onset myoclonic epilepsy in Down syndrome" (LOMEDS). Their observations were supported by previous epidemiologic studies (Evenhuis 1990, Johannsen *et al.* 1996). Möller *et al.* (2001, 2002) have proposed the inclusion of LOMEDS among the possible causes of epileptic myoclonus in the differential diagnosis of adult-onset myoclonic epilepsies. EEG features, showing generalized epileptiform discharges (Genton and Paglia, 1994, Möller *et al.* 2001, 2002), with polyspike-wave complexes preceding the myoclonic jerk, allow the classification as generalized epileptic myoclonus (Hallet 1979).

The exact mechanism for such a significant presence of epilepsy in DS is not clear: it has been hypothesized that structural abnormalities and biochemical aberrations of the central nervous system (CNS) may be responsible, but several other causes, such as cardiovascular disease and infections, may play a determinant role. In any case, the final pathway of the different causal mechanisms leads to a hyper-excitability of CNS. Several authors have observed in DS patients a lower brain neural density and abnormal neuronal distribution, in particular in cortical layer II and IV (Kemper, 1988), dysgenesis of dendritic spines in the form of longer and thinner necks (Wisniewski *et al.* 1984),

hyper-excitability membrane properties in cultured dorsal root ganglion neurons from fetuses with DS (Scott *et al.* 1982). A decisive role can be played by a defect in a gene coding for a subunit of glutamatergic receptor, the GluR5, coded in the distal arm of chromosome 21, a critical region for DS. Finally, epilepsy can be caused by a mix of several factors, such as modifications of cellular membranes to hyper-excitability, structural modification, and alteration of inhibitory transmission.

The high frequency of myoclonus in DS, especially in elderly patients (Johannsen *et al.* 1996), has been explained by the frequent and early onset of dementia in DS. DS patients over the age of 40 showed neuropathological changes characteristic of AD, including neurofibrillary tangles, neuritic plaques, and neuron cell loss (Bugiani *et al.* 1991). The presence of AD in DS has been explained by a dose effect of the amyloid precursor protein gene on chromosome 21 (Rumple *et al.* 1989). In an extensive survey of autopsy data for adults with DS (Schweber 1989), brain pathology of AD was universal in those aged 37 and over. Seizures, mostly tonic-clonic, emerge in 84% of DS patients with AD (Lai and Williams, 1989). Myoclonus is not an exclusive aspect of AD in DS. Some authors (Hauser *et al.* 1986) found in a population of 83 AD cases (without DS), a cumulative risk of myoclonus of 12% by 10 years after the onset of AD symptoms and of 17% by 16 years. Therefore, myoclonus is an accepted symptom of AD, with a physiological basis that is not clearly understood: Wilkins *et al.* (1984) suggested a cortical origin, such that seizures (also present in AD patients with a 10-fold increased risk) and myoclonus could be linked. In contrast to patient 2, who had no prior history of epilepsy, patient 1 had been previously treated for a cryptogenic, partial epilepsy which was fully controlled by monotherapy, without relapse after discontinuation of treatment, and which after a seizure-free period had the same course as patient 2; it can be further noted that CBZ was effective in her first, focal epilepsy, but not (and even possibly aggravating) against myoclonus. Her history shows that a patient with DS can experience different types of epilepsy successively. Both patients clearly satisfy the criteria of a recognizable, probably frequent form of myoclonic epilepsy associated with dementia in elderly DS patients.

Conclusion

The occurrence of late-onset complications of DS may be a consequence of increased life span in DS. Given the higher prevalence of epilepsies in DS, it is likely that the precocious development of an Alzheimer-type dementia translates, in many patients with DS and AD, versus only a few with AD without DS, into recognizable, "senile" myoclonic epilepsy. The clinical picture, as illustrated here by the clinical observations, the EEG changes and the videos, make it an easily identifiable entity. □

Legend for video sequences*Patient 1 – parts 1-2-3-4*

Video-EEG recording (only the video shown here) obtained in the clinic around 11 AM. In the first two parts, evidence of massive and of segmental myoclonus involving the face, limbs and trunk. In part 3 and 4, evidence of increased jerks on 10-14 Hz IPS, with massive or segmental myoclonic jerks more evident on facial and shoulder muscles.

Patient 2 – parts 1-2-3-4

Video recorded after a full-night polygraphic EEG, in the early morning after awakening. Presence of segmental myoclonus involving both arms with a right predominance (part 1), massive axial myoclonus (part 2), positive and negative myoclonic jerks involving both arms (part 3), massive myoclonus involving predominantly trunk, left shoulder and left arm, with a consequent dropping of a cup (glass).

References

- Bugiani O, Tagliavini F, Giaccone G. Preamyloid deposits, amyloid deposits, and senile plaques in Alzheimer's disease, Down syndrome, and aging. *Ann N Y Acad Sci* 1991; 640: 122-8.
- Evenhuis HM. The natural history of dementia in Down's syndrome. *Arch Neurol* 1990; 47: 263-7.
- Hallett M, Chadwick D, Marsden CD. Cortical reflex myoclonus. *Neurology* 1979; 29: 1107-25.
- Hauser WA, Morris ML, Heston LL, et al. Seizures and myoclonus in patients with Alzheimer's disease. *Neurology* 1986; 36: 1226-30.
- Genton P, Paglia G. Epilepsie myoclonique sénile? Myoclonies d'apparition tardive dans le syndrome de Down. *Epilepsies* 1994; 1: 5-11.
- Guerrini R, Genton P, Bureau M, et al. Reflex seizures are frequent in patient with Down syndrome and epilepsy. *Epilepsia* 1990; 31: 406-17.
- Johannsen P, Christensen JEJ, Goldstein H, et al. Epilepsy in Down syndrome – prevalence in three age groups. *Seizure* 1996; 5: 121-5.
- Kemper TL. Neuropathology of Down syndrome. In: Nadel L, ed. *The Psychopathology of Down Syndrome*. Cambridge, Mass: MIT Press, 1988: 269-89.
- Lai F, Williams RS. A prospective study of Alzheimer disease in Down syndrome. *Arch Neurol* 1989; 46: 849-53.
- Li LM, O'Donoghue MF, Sander JW. Myoclonic epilepsy of late onset in trisomy 21. *Arch Neuropsychiatr* 1995; 53: 792-4.
- Mann DM. Association between Alzheimer's disease and Down syndrome: neuropathological observations. In: Berg JM, Karlinsky H, Holland AJ, eds. *Alzheimer Disease, Down Syndrome, and their relationship*. New York, NY: Oxford University Press, 1993: 72.
- McVickers RW, Shanks OEP, McClelland RJ. Prevalence and associated features of epilepsy in adults with Down's syndrome. *B J Psychiatry* 1994; 164: 528-32.
- Möller JC, Hamer HM, Oertel WH, et al. Late-onset myoclonic epilepsy in Down's syndrome (LOMEDS). *Seizure* 2001; 10: 303-5.
- Möller JC, Hamer HM, Oertel WH, et al. Late-onset myoclonic epilepsy in Down's syndrome (LOMEDS). *Seizure* 2002; 11(Suppl A): 303-5.
- Pedersen B. Epilepsy of late onset in Down's syndrome: A new epileptic syndrome. *Epilepsia* 1990; 5: 613.
- Pueschel SM, Louis S, Mc Knight P. Seizure disorders in Down syndrome. *Arch Neurol* 1991; 48: 318-20.
- Rumple B, Retallack R, Hilbich C, et al. Amyloid A4 protein and its precursor in Down's syndrome and Alzheimer's disease. *N Engl J Med* 1989; 320: 1446-52.
- Schweber MS. Alzheimer's disease and Down syndrome. *Prog Clin Biol Res* 1989; 317: 247-67.
- Scott BS, Petit TL, Becker LE, et al. Abnormal electric membrane properties of Down's syndrome DRG neurons in cell culture. *Brain Res* 1982; 2: 257-70.
- Stafstrom CE, Gilmore HE, Ehrenberg GL. Seizures in persons with Down syndrome: cause and prognosis. *Ann Neurol* 1988; 24: 308-9.
- Stafstrom CE, Patxot OF, Gilmore HE, et al. Seizures in children with Down syndrome: etiology, characteristics and outcome. *Dev Med Child Neurol* 1991; 33: 191-200.
- Stafstrom CE. Epilepsy in Down syndrome: clinical aspects and possible mechanisms. *Am J Ment Ret* 1993; 98(suppl): 12-26.
- Tatsuno M, Hayashi M, Iwamoto H, et al. Epilepsy in childhood Down syndrome. *Brain Dev* 1984; 6: 37-44.
- Van Allen MI, Fung J, Jurenka SB. Health care concerns and guidelines for adults with Down Syndrome. *Am J Med Genet* 1999; 89: 100-10.
- Veall RM. The prevalence of epilepsy among mongols related to age. *J Ment Def Res* 1974; 18: 99-106.
- Wilkins DE, Hammett M, Berardelli A, et al. Physiological analysis of the myoclonus of Alzheimer's disease. *Neurology* 1984; 34: 898-903.
- Wisniewski KE, Laure-Kamionowska M, Wisniewski HM. Evidence of arrest of neurogenesis and synaptogenesis in brains of patients with Down's Syndrome. *N Engl J Med* 1984; 311: 1187-8.