

Vasovagal syncope misdiagnosed as epilepsy for 17 years: prime importance of clinical history

Marianna V. Spanaki¹, Patricia Garcia¹, Claudio D. Schuger²,
Brien J. Smith¹

¹ Neurology Department,

² Cardiology Department, Henry Ford Hospital, HFHS, USA

Received February 6, 2006; Accepted June 19, 2006

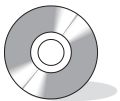ABSTRACT – Distinguishing epilepsy from syncope often can be challenging. We report a case of a 20-year-old patient with presumed refractory epilepsy since the age of 3 years. Although the clinical suspicion of syncope was raised at the age of 9 years, key historic features were not identified, cardiac work-up was not pursued and despite lack of electrographic evidence of epilepsy, he received anticonvulsant treatment. During his presurgical evaluation for “refractory epilepsy”, one typical event was captured that was associated with asystole and normal electroencephalogram. The diagnosis of vasodepressor syncope was made and anticonvulsant medication was discontinued. With this case report, we would like to emphasize the importance of a meticulous history and the need to perform continuous video electroencephalographic with simultaneous electrocardiographic recordings in the evaluation of paroxysmal events with atypical presentation.

[Published with video sequences]

Key words: asystole, vasovagal syncope, epilepsy, video-EEG, epilepsy misdiagnosis

It is estimated that the misdiagnosis rate of epilepsy in adults is 25% (Smith *et al.* 1998). Syncope is the condition most commonly misdiagnosed as epilepsy (Smith *et al.* 1998). The main cause of inaccurate diagnosis is incomplete history (Smith *et al.* 1998). The importance of history in distinguishing syncope from seizures has been addressed by a number of studies (McLeod 2002; Sheldon *et al.* 2002). Some investigators have developed a point score of symptoms (his-

torical criteria) and have shown that the two conditions can be correctly diagnosed with very high sensitivity and specificity (Sheldon *et al.* 2002). We present a patient who had been erroneously diagnosed with epilepsy for 17 years, who was admitted to the Henry Ford Hospital Epilepsy Monitoring Unit (EMU) for presurgical evaluation of “refractory seizures”. In our case, the diagnosis of syncope was delayed because key historic features such as precipitating factors and



Correspondence:

M.V. Spanaki, MD, PhD
Neurology Department,
Henry Ford Hospital
2799 West Grand Boulevard,
Detroit, MI 48202-2689,
USA
<spanaki@neuro.hfh.edu>

prodromal symptoms were overlooked, and the presence of motor phenomena was thought to be supportive of the diagnosis of epilepsy rather than of syncope.

Case study

A 20-year-old, right-handed male with the diagnosis of refractory epilepsy was admitted to our EMU for presurgical evaluation. He was a product of a normal, full term pregnancy with no risk factors for epilepsy. He reached his developmental milestones at an appropriate age. His paternal uncle was treated for one year with phenytoin for episodes of loss of consciousness. The patient's first seizure occurred at the age of three while he was sitting in a restaurant and it was described as a generalized tonic-clonic seizure. Despite normal head CT and EEGs, he was started on phenobarbital. After initial failure of phenobarbital and discontinuation of valproic acid due to rash, he was maintained on phenytoin for three years. At the age of six he was weaned off phenytoin. Three years later, while visiting a museum he complained of blurry vision and abdominal pain, followed by a fall, a brief tonic-clonic seizure and postictal fatigue. An internist witnessed the episode and was convinced that it was an epileptic seizure. Although his treating physician suspected vasovagal syncope, he eventually treated the patient with phenytoin based on the internist's description of the event. He remained episode-free until the age of 11 when the paroxysmal events reoccurred. His episodes were best described as a funny feeling in his head and throat, heart pounding, arching of the body, unresponsiveness and post-event confusion. Urinary incontinence was documented only once. The patient identified triggering factors such as febrile illnesses, pain, emotional distress and alcohol use. At the age of 15, he was evaluated in a pediatric EMU, and a paroxysmal episode was documented with presumed temporal lobe origin but unclear EEG localization. MRI and PET were unremarkable. At the age of 16, he was treated with levetiracetam and carbamazepine and he was episode-free until a few months prior to his admission to our EMU. Numerous routine and prolonged ambulatory EEGs over seventeen years failed to document interictal epileptiform abnormalities. At presentation, he reported recurrent episodes with a frequency of one per week. One event, witnessed in our outpatient clinic prior to admission, was described as initial head and eye deviation to the right while sitting, with subsequent movement to the left, changes in respiration, cyanosis and impaired consciousness. During his hospital stay, antiepileptic medications were gradually tapered, then stopped. His continuous awake and sleep EEGs failed to document interictal abnormalities. However, upon analysis of simultaneous EEG/ECG data and review of vital signs, frequent episodes of sinus tachycardia alternating with bradycardia were identified. Caffeine was completely stopped and

thyroid hormones were checked and found to be normal. A cardiology consultation was obtained and Holter monitoring was advised. After 10 days of prolonged video-EEG/ECG monitoring off medication, one habitual event was recorded. Prior to the episode, the patient was very distressed over the lack of symptoms during his hospitalization and was praying with his mother. He was sitting in bed when he reported a sensation in his throat and a feeling as if he were going to faint. He pushed the button and leaned backwards. The patient was neither holding his breath nor was he hyperventilating during the episode. He remained alert and oriented, but was clinically pale and cyanotic. Blood pressure and oxygen saturation in the supine position were not significantly different from his baseline. ECG demonstrated a 5 second asystole followed by bradycardia prior to push button activation. Two additional episodes of asystole (4 and 7 second duration) were noted before appearance of normal sinus rhythm (figure 1A, B). Before, during and after the episode, the EEG was unchanged from baseline and no slowing was observed. Cardiology recommended a tilt-table test and 2-D echocardiogram. The tilt-table test with isoproterenol was negative. Echocardiogram revealed an ejection fraction of 55-60% with mild mitral regurgitation (rate of 1+ on a scale of 0-4), mild pulmonic regurgitation, and trivial tricuspid regurgitation. Despite an unremarkable tilt-table test, cardiology concluded that the patient's symptoms resulted from asystole in the context of vasodepressor syncope of undetermined cause. The diagnosis was based on reconsideration of key historic features, lack of ictal or interictal electrographic evidence of epilepsy, exclusion of dysrhythmias and cardiomyopathy and presence of episode-related EKG changes. Metoprolol was initiated by the inpatient cardiology service and antiepileptic drugs were not restarted. The patient was evaluated in the outpatient cardiology clinic by one of the co-authors (CS), who recommended discontinuation of metoprolol and initiation of fludrocortisone (Florinef 0.1 mg daily). The patient refused to consider changes in his regimen. He has not experienced any symptoms in the last 8 months.

Discussion

This case highlights important points in the management of episodes of impaired consciousness that may be overlooked and which may lead to inaccurate diagnosis and treatment. The family history of events with loss of consciousness was interpreted as supportive of a diagnosis of epilepsy, and other organic conditions were not considered. Precipitating factors such as pain, stress and prolonged standing were ignored. Prodromal symptoms such as abdominal pain and strange sensations in the head and throat were viewed as auras. Motor phenomena (tonic-clonic seizures, head and eye deviation) and post-event disorientation led to the misdiagnosis of epilepsy,

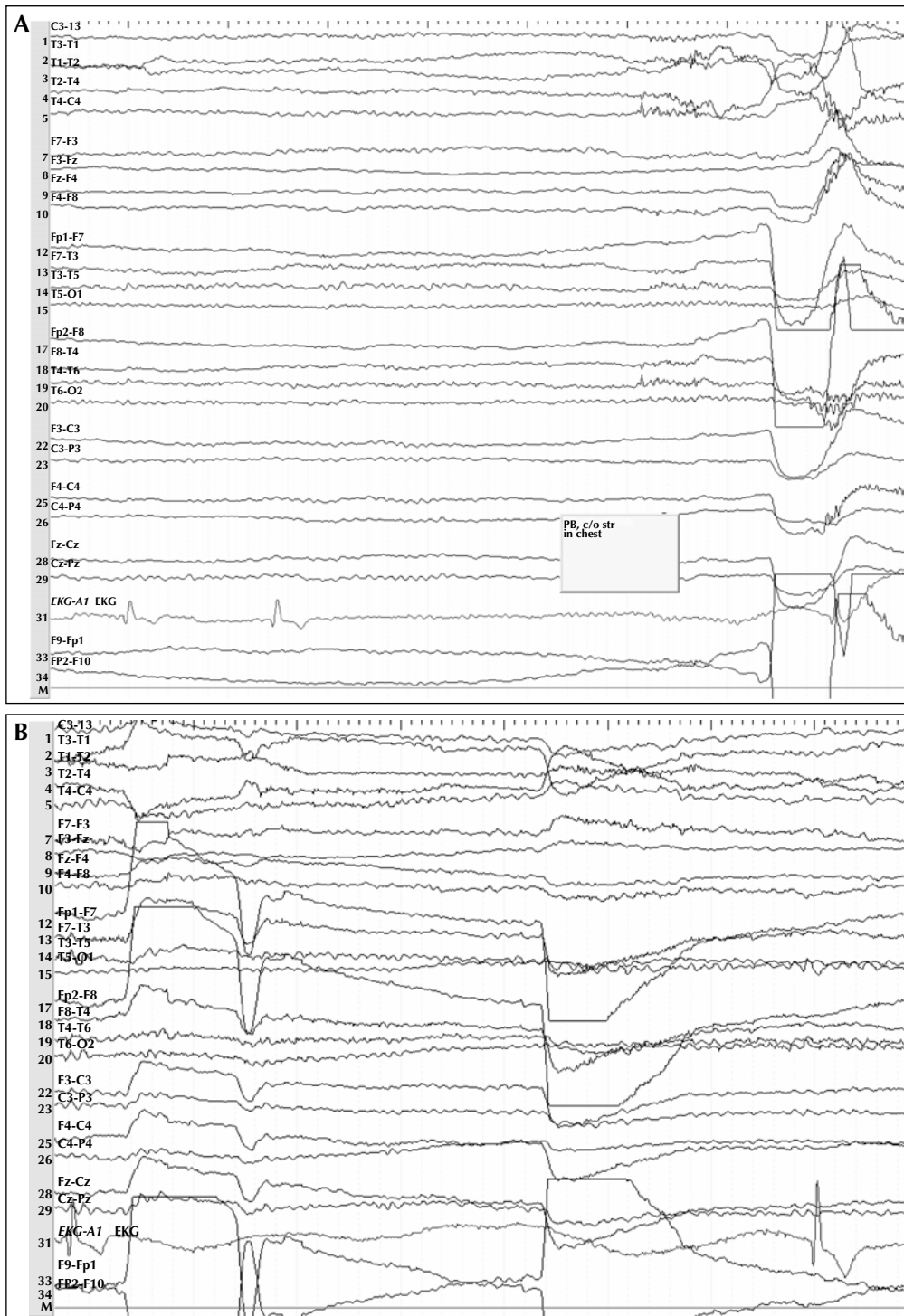


Figure 1. Clinical description: prior to the episode at 11:39:01 the patient is sitting in bed with his knees bent to the chest and arms crossed over the knees. He is emotionally charged due to lack of events over a 10-day hospitalization. He is praying along with his mother. At 11:39:09, he is asking his mother to stop and at 11:39:11 he is pushing the button. He is feeling a sensation in his throat and is lying on his bed. At 11:39:33 he is interacting with the nurse. At 11:39:49 he is following commands. He is aware of time. He is describing that he had a feeling of fainting. At 11:40:50, although he is slow in his responses, he is appropriate. The patient admitted that his symptoms were typical of his habitual "auras". His mother confirmed that the events that she witnessed in the past were very similar to the one recorded.

EEG description: From 11:39:06 to 11:39:12 asystole is seen. Two more episodes of asystole are captured from 11:39:20 to 11:39:24 and 11:39:59 to 11:40:06 followed by sinus arrhythmia. At 11:40:31, sustained regular sinus rhythm is observed.

although these phenomena may also be observed in association with syncope. Review of the literature shows that it is more common to misdiagnose cardiovascular syncope as epilepsy rather than the other way around (Smith *et al.* 1999). No-one is immune to making a false clinical diagnosis of epilepsy, not even physicians who witness the events. Syncope is a common symptom in otherwise healthy children and adolescents, particularly between the ages of 9 and 14 years. Neurocardiogenic (vasodepressor or neurally-mediated syncope) is the most common type and is considered to be benign (McLeod 2002). Nonetheless, in 1% to 2% of children presenting with syncope, a serious underlying disorder may be present, such as aortic stenosis, hypertrophic cardiomyopathy or coronary malformations that necessitates prompt diagnosis (Batra and Balaji 2005).

Ictal bradycardia and asystole have been reported in seizures that originate in the temporal lobes, and most often occurs in association with bilateral hemispheric seizure activity (Britton *et al.* 2006). Only thorough analysis of simultaneous ECG and video/EEG data increases the diagnostic yield and facilitates the distinction between ictal autonomic changes and vasodepressor syncope (Heckmann *et al.* 2001).

The use of sodium channel blocking drugs such as phenytoin and carbamazepine in cardiac-related syncope may worsen undetected heart disease through their negative chronotropic and dromotropic effects (Kenneback G *et al.* 1991). In our case, it is plausible that the increase in episode frequency may have been attributed to aggravation of bradycardia with prolonged use of carbamazepine. Our diagnosis was not supported by the tilt-table test that failed to reproduce the patient's events. Sensitivity of the tilt test with the use of provocative agents such as isoproterenol is estimated to be 64% in syncope of unknown cause, which may explain why the diagnosis can not be ruled out in cases like ours where the test is unremarkable (Kapoor 1999). Even if appropriate diagnostic work-up, that includes electrocardiogram (ECG), blood pressure measurements and the tilt test, is performed, the cause of syncope is not identified in approximately 30% of patients (Strano *et al.* 2005).

The mainstay of therapy in vasovagal syncope is reassurance and sometimes counterpressure maneuvers (McLeod 2003). There is no consensus on the most effective treatment of vasovagal syncope. Most recently, metoprolol was

found to be ineffective. In our case, the response to metoprolol may indicate a placebo effect (Sheldon *et al.* 2006). Misdiagnosis of syncope as epilepsy has significant prognostic and therapeutic implications. Correct diagnosis can be achieved through detailed history, aggressive diagnostic work up with Holter, tilt-table test and simultaneous ECG/video EEG recording, as well as collaborative work of relevant specialists. □

Acknowledgements. We thank Diane Budzyn, REEGT, CNIM for her assistance in preparing the video material.

References

- Batra AS, Balaji S. Management of syncope in pediatric patients. *Curr Treat Options Cardiovasc Med* 2005; 7: 391-8.
- Britton JW, Ghearing GR, Benarroch EE, *et al.* The ictal bradycardia syndrome: Localization and lateralization. *Epilepsia* 2006; 46: 737-44.
- Heckmann JG, Portwich P, Kerling F, *et al.* Simultaneous EEG and ECG recording of sinus arrest. *Intens Care Med* 2001; 27: 1432.
- Kapoor W. Using a tilt table to evaluate syncope. *Am J Med Sci* 1999; 317: 110-6.
- Kenneback G, Bergfeldt L, Vallin H, *et al.* Electrophysiologic effects and clinical of carbamazepine treatment for neurologic disorders in patients with abnormalities of the cardiac conduction system. *Am Heart J* 1991; 121: 1421-9.
- McLeod KA. Syncope in childhood. *Arch Dis Child* 2003; 88: 350-3.
- Sheldon R, Rose S, Ritchie D, *et al.* Historical criteria that distinguish syncope from seizures. *J Am Coll Cardiol* 2002; 40: 142-8.
- Sheldon R, Connolly S, Rose S, *et al.* Prevention of syncope trial (POST). A randomized placebo-controlled study of metoprolol in the revention of vasovagal syncope. *Circulation* 2006; 113: 1164-70.
- Smith D, Defalla BA, Chadwick DW. The misdiagnosis of epilepsy and the management of refractory epilepsy in a specialist clinic. *Q J Med* 1999; 92: 15-23.
- Strano S, Colosimo C, Sparagna A, *et al.* Multidisciplinary approach for diagnosing syncope: a retrospective study on 521 outpatients. *J Neurol Neurosurg Psychiatry* 2005; 76: 1597-600.