

# Video-EEG study in an adult and a child with eyelid myoclonia with absences

J.G. Burneo MD, MSPH<sup>1</sup>, S. Miller RN, BSN<sup>2</sup>, E.M. Bebin MD<sup>2</sup>, A. Prasad MD<sup>2</sup>

<sup>1</sup> Epilepsy Programme, Department of Neurological Sciences, University of Western Ontario, London, Canada

<sup>2</sup> Department of Neurology, UAB Epilepsy Center, University of Alabama School of Medicine, Birmingham, AL, USA

Received April 13, 2004; Accepted August 10, 2004

**ABSTRACT** – Two patients with eyelid myoclonia with absences (EMA) are described. Videotape of the eyelid myoclonia in one patient is presented. An interesting feature in one patient was the induction of clinical seizures only with daylight, and in another the presence of rare, focal, epileptiform discharges during drowsiness. Valproic acid only partially controlled eyelid myoclonia in both cases. Lamotrigine, alone or in combination with valproate, can be used as an alternative but was ineffective in our cases. [Published with video sequences].

**KEYWORDS:** Eyelid myoclonia with absences, myoclonic seizures, myoclonic epilepsy, idiopathic generalized epilepsy

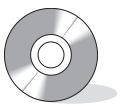Eyelid myoclonia with absences (EMA), is an idiopathic, myoclonic, epileptic syndrome manifesting as eyelid myoclonia that may occur alone or evolve to a short-duration absence [1]. The diagnosis of EMA becomes more likely when these clinical features are associated with photosensitivity, and becomes pathognomonic when these clinical features occur after eye closure [1]. The ictal EEG consists of generalized 3-6 Hz polyspike-slow wave complexes that are more likely to occur after eye closure in an illuminated room. The clinical features distinguishing EMA from other syndromes of idiopathic generalized epilepsies are described in the literature [1, 2]. The hallmark of EMA is the localized myoclonia of the eyelids and not the absences that are seen as part of the seizure. *Examination of the spells on videotape is extre-*

*mely helpful in the diagnosis; once seen, EMA is never forgotten* [1]. EMA is more difficult to control than typical absence or other types of idiopathic generalized epilepsy [2]. We present two patients with eyelid myoclonia with absences (EMA), one adult and one child, and discuss the role of lamotrigine in the treatment.

## Case reports

### Case 1

A 32-year-old male was referred for eye blinking spells that started at age 12. These consisted of rapid eye fluttering, upward rolling of eyeballs, head retroflexion, and myoclonus of the shoulder. These occurred several times a day and lasted a few seconds. These were triggered by bright sunlight, but not by artificial or flashing



### Correspondence:

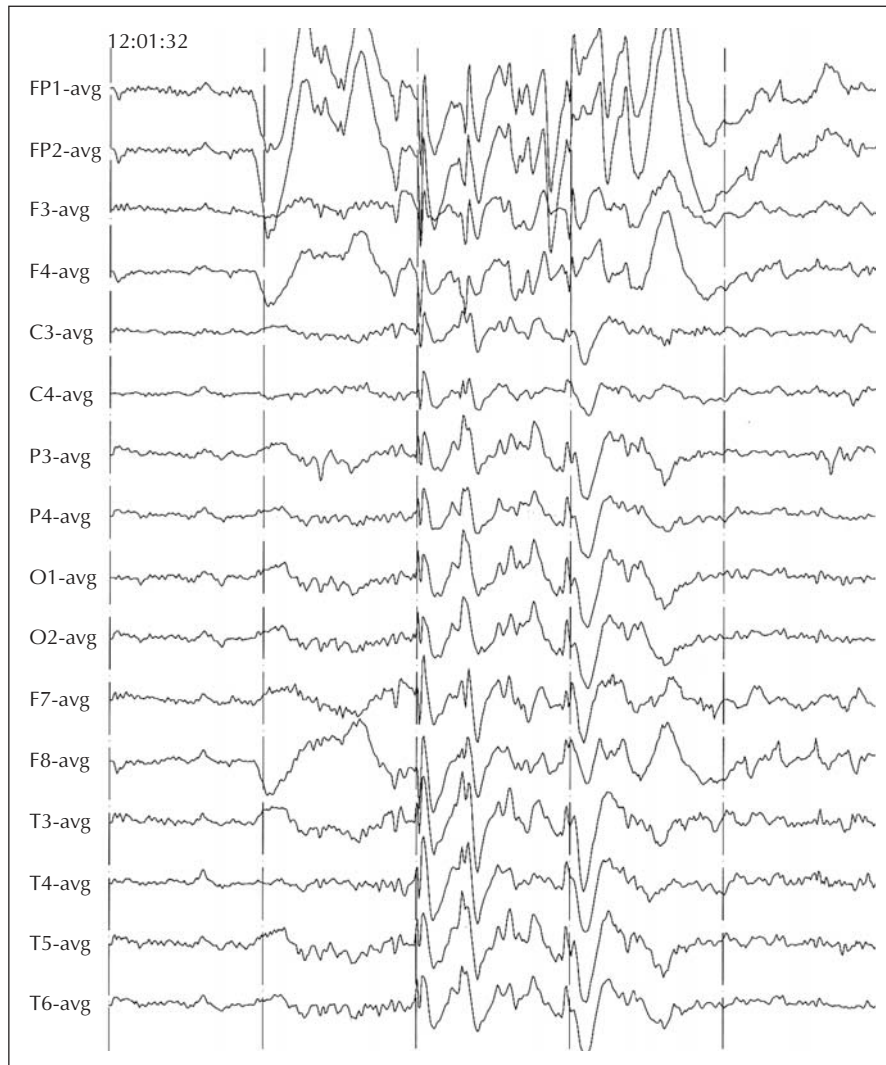
J.G. Burneo, MD  
Epilepsy Programme  
Department of Clinical Neurological Sciences  
The University of Western Ontario  
London Health Sciences Center  
339 Windermere Road  
London, ON. N6A 5A5, Canada.  
Tel.: +1-519-685-8500,  
Fax: +1-519-663-3753.  
<jburneo@uwo.ca>

lights. Impaired responsiveness in association with eyelid myoclonia occurred only during adolescence. He had two generalized tonic-clonic seizures at the age of 25 and 31 years.

No perinatal history was available because he was adopted at the age of three months. Developmental history was normal but he had two simple febrile seizures at the age of six and 13 months. Neurological examination, routine EEG, and brain MRI were normal. Phenobarbital was started after the second febrile seizure, and was continued until the age of five. At age 25, after the first generalized tonic-clonic seizure (GTC), valproate (VPA) was started, which moderately controlled eyelid myoclonia at a dose of 500 mg *tid* for approximately 12 weeks, but produced hair loss. Later, carbamazepine and gabap-

entin were tried for brief periods without success. At age 26, phenytoin (PHT) 300 mg/day was started.

During admission, we failed to induce seizures with photic stimulation on two consecutive days. Looking at the sunlight filtering through the window blinds in the morning failed, but at noon it induced three brief episodes of eyelid myoclonia, on each separate attempt. Ictal EEG revealed two-three second bursts of irregular, frontally dominant, generalized 3-5 Hz spike/polyspike-slow wave complexes. Interictal EEG revealed similar epileptiform discharges on eye closure, but these were briefer (*figure 1*). Photic stimulation induced 3-5 Hz spike/polyspike-slow wave complexes, but no photoparoxysmal response. Lamotrigine (LTG) was started and gradually increased, over a period of eight weeks, to 125 mg twice daily



**Figure 1.** Interictal EEG in patient 1 shows a single, 1.5 second burst of atypical, frontally dominant generalized 3.5 Hz spike/polyspike-slow wave complex on eye closure.

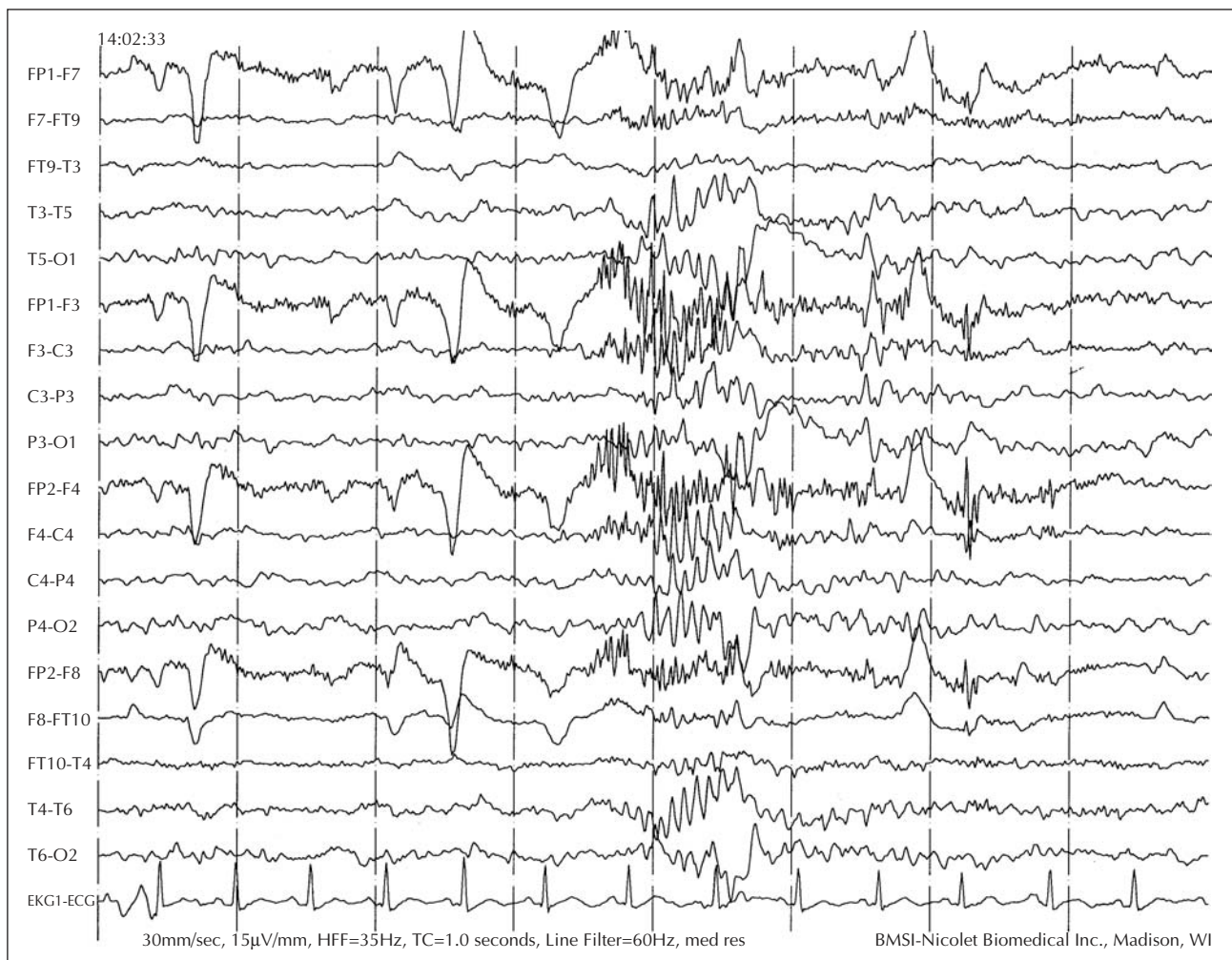
(4 mg/kg/day). Phenytoin was gradually discontinued. During a four-month follow-up, no GTC occurred, but EMA in response to bright sunlight remained unchanged.

## Case 2

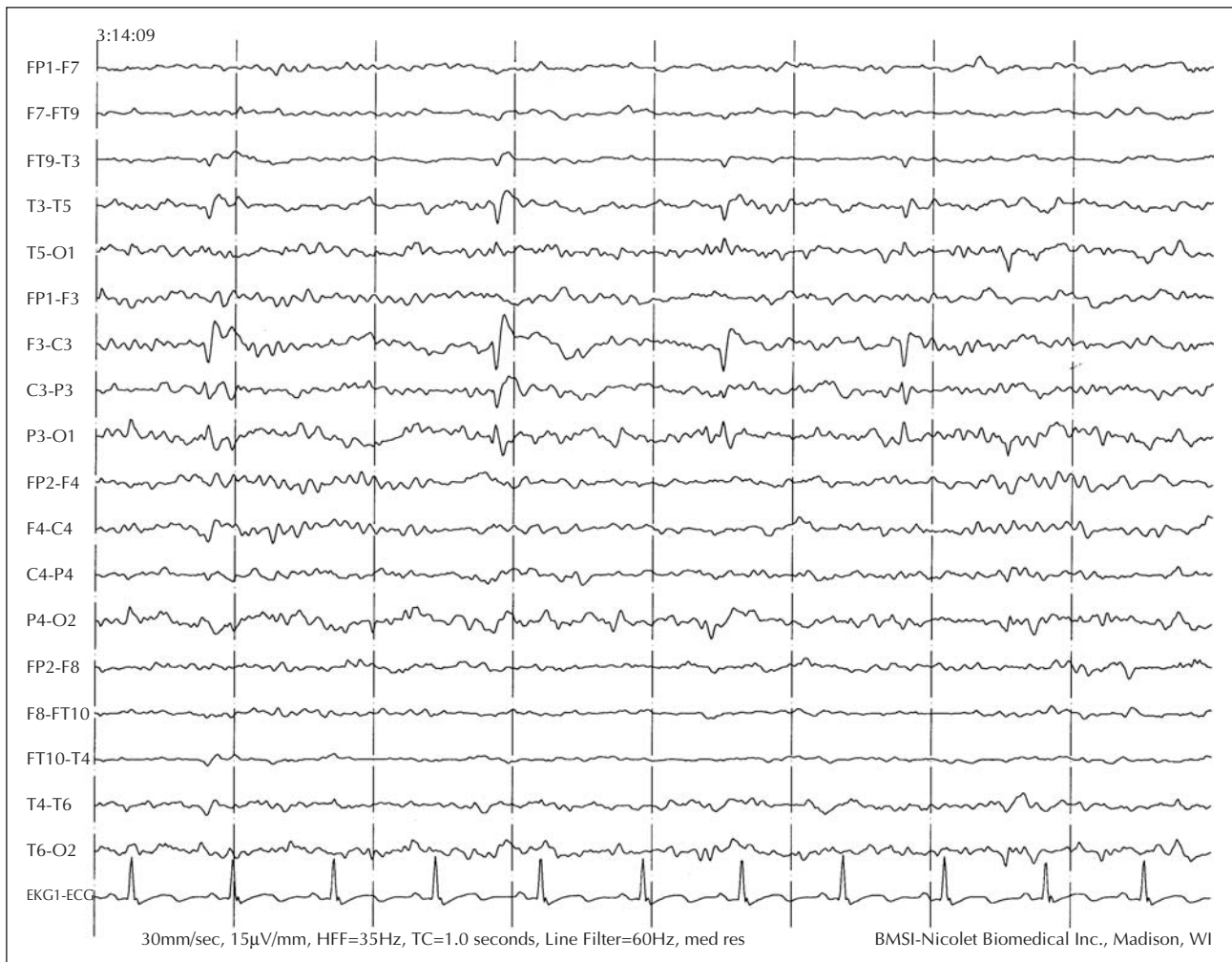A seven-year-old girl was admitted for evaluation of brief, eye blinking spells that started at age six. These consisted of rapid eye fluttering, upward rolling of the eyeballs, and occasionally head retroflexion. They occurred several times a day, lasted a few seconds, and were triggered by exposure to artificial or natural sunlight. Dark glasses decreased the frequency and duration of the events. She had never had GTC or absence seizures. Brain MRI was normal. She was initially treated with VPA with no apparent response. LTG was added, with the plan to switch her to monotherapy. Spells worsened when VPA was tapered. Clonazepam was added three months later to achieve better control of the eyelid myoclonia. At the time of

admission, she was taking 25 mg of LTG twice a day, 125 mg of VPA twice a day (serum level: 42 mcg/ml), and 0.25 mg of clonazepam at bedtime.

During hospitalization, clonazepam was discontinued. Video-EEG monitoring captured two typical seizures. Ictal EEG revealed frontally dominant, generalized polyspike-slow wave complexes lasting up to two seconds (*figure 2*). A seizure triggered by exposure to sunlight and captured on home-video is shown in *video segment 1*. Interictal EEG revealed frontally dominant, generalized polyspike-slow wave complexes on eye closure and rare, left parietal-posterior temporal spikes during drowsiness (*figure 3*). Photic stimulation induced 3-5 Hz spike/polyspike-slow wave complexes, but no photoparoxysmal response. Despite six months of treatment with LTG as polytherapy, the eyelid myoclonia failed to improve so LTG was replaced by topiramate (TPM), VPA remaining unchanged, however, with no success in controlling the eyelid myoclonia.



**Figure 2.** Ictal EEG in patient 2 shows a two-second burst of generalized polyspike-slow wave complex on eye closure.



**Figure 3.** Interictal EEG in patient 2 shows left parieto-posterior temporal spikes during drowsiness.

## Discussion

The electroclinical findings in our study are consistent with the diagnosis of EMA. We present a home video tape, which is easy to obtain and can capture the clinical semiology with great clarity. Nonetheless, an electroclinical study is necessary to substantiate the diagnosis by demonstrating that eye closure induces eyelid flicker, flutter or jerking in association with generalized EEG discharges. Absences can occur independent of eye closure during hyperventilation and intermittent photic stimulation [3, 4]. Both patients had interesting features. Our first patient reported clinical seizures triggered exclusively by bright sunlight and never by artificial light. During admission for video-EEG monitoring, photic stimulation failed, but bright, midday sunlight induced three, brief episodes of eyelid myoclonia without absences. In patients with EMA, photosensitivity decreases with age [5]. Whether

photic stimulation would have induced clinical seizures at an earlier age is unknown.

Our second patient had clinical seizures in response to sunlight and artificial light. An interesting feature was the presence of left parietal-posterior temporal spikes during drowsiness. Localization of the spikes only to the left hemisphere raised the question of whether an independent focus of epileptogenicity existed in the left parieto-temporal region. Nonetheless, the rarity of the spikes, the presence of spikes only during drowsiness suggesting fragmentation of the generalized spike, a normal alpha rhythm, the lack of focal slowing, and the semiology, would favor a diagnosis of an epilepsy syndrome related to idiopathic generalized epilepsy.

In eyelid myoclonia with absences, generalized tonic-clonic seizures respond well to antiepileptic treatment, but eyelid myoclonia are often medically refractory [6]. Both our patients reported only partial improvement in the



control of eyelid myoclonia with VPA. In a previous study of 11 patients treated for EMA, eyelid myoclonia persisted in nine patients, although control of absences improved in all patients and none had generalized tonic clonic seizures [5]. We found a similar dissociation in the response to antiepileptic drug treatment in patients with juvenile myoclonic epilepsy (JME) [7]. VPA, LTG, and topiramate in mono- or polytherapy, in our study, resulted in a good control of generalized tonic clonic seizures in 68-82 % of patients, in contrast to good control of myoclonic seizures in only 54-60 % of patients with JME. VPA monotherapy is the drug of choice for the treatment of EMA. Second line treatment includes ethosuximide, LTG, benzodiazepines, and acetazolamide, which may be used alone or in combination with VPA. Drugs like vigabatrin, carbamazepine or gabapentin usually have an aggravating effect. Five patients treated with LTG in monotherapy or polytherapy had a substantial reduction or cessation of seizures; four of these had failed VPA therapy [2, 8, 9]. Anecdotal evidence of the efficacy of LTG in patients with EMA [2, 8, 9], and evidence from other case series [10] suggest that LTG may be a useful drug for the treatment of EMA. We could have tried higher doses of LTG in our patients, but the first patient was lost to follow-up and the second patient could not tolerate a higher dose due to increased drowsiness and so was switched to TPM. The poor response to LTG therapy in both our patients however, illustrates that the response to LTG is not a constant finding in EMA. □

## References

1. Panayiotopoulos CP, Agathonikou A, Koutroumanidis M, *et al.* Eyelid myoclonia with absences: the symptoms. In: Duncan JS, Panayiotopoulos CP, eds. *Eyelid myoclonia with absences*. London: John Libbey, 1996.
2. Appleton RE. Typical absence and related epileptic syndromes. In: Duncan JS, Panayiotopoulos CP, eds. *Eyelid myoclonia with absences*. London: John Libbey, 1995.
3. Jeavons PM. Nosological problem of myoclonic epilepsies in childhood and adolescence. *Dev Med Child Neurol* 1977; 19: 3-8.
4. Covanis A, Gupta AK, Jeavons PM. Sodium valproate: monotherapy and polytherapy. *Epilepsia* 1982; 23: 693-720.
5. Giannakodimos S, Panayiotopoulos CP. Eyelid myoclonia in adults: clinical and EEG features. In: Duncan JS, Panayiotopoulos CP, eds. *Eyelid myoclonia with absences*. London: John Libbey, 1996.
6. Richens A. Treatment of eyelid myoclonia with absences. In: Duncan JS, Panayiotopoulos CP, eds. *Eyelid myoclonia with absences*. London: John Libbey, 1996.
7. Prasad A, Kuzniecky RI, Knowlton RC, *et al.* Evolving antiepileptic drug treatment in juvenile myoclonic epilepsy. *Arch Neurol* 2003; 60: 1100-5.
8. Covanis A, Skiadas K, Loli N, *et al.* Eyelid myoclonia with absence. *Epilepsia* 1994; 35(suppl 7): S13.
9. Smith SJM. Eyelid myoclonia with absences in adults: comparison with other absence seizures. In: Duncan JS, Panayiotopoulos CP, eds. *Eyelid myoclonia with absences*. London: John Libbey, 1996.
10. Schlumberger E, Chavez F, Palacios L, *et al.* Lamotrigine in treatment of 120 children with epilepsy. *Epilepsia* 1994; 32(suppl 1): S59.

## Legend for video sequences

Home-Video shows three brief episodes of eyelid myoclonia in patient 2 on exposure to sunlight.