

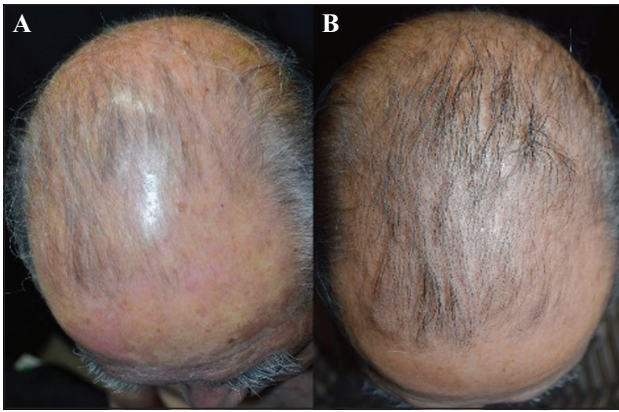Figure 1. Clinical manifestation before (A) and after (B) secukinumab administration.

Because the patient recognized hair growth after improvement of psoriatic skin inflammation, not only on the trunk and extremities but also on the scalp after secukinumab injection, our case suggests that recovery of hair growth could be expected in patients with psoriatic alopecia after anti-IL-17A antibody treatment. Therefore, androgenetic alopecia-like hair loss might be associated with psoriasis, manifesting as psoriatic alopecia in this case. Another possibility is that IL-17A could contribute to the pathogenesis of alopecia itself. In a previously reported case, alopecia complicated with psoriasis was documented to improve after administration of the anti-IL-23p40 antibody, ustekinumab [1]. Therefore, inhibition of IL-17A might exert a further beneficial impact on alopecia. In addition, the role of IL-17 blockade on hair pigmentation has yet to be assessed. Although our patient's hair was streaked with grey before secukinumab administration, he recognized an increased proportion of black hair on the top of his scalp after treatment. Therefore, this case suggests a possible role of IL-17A in hair depigmentation. In a representative depigmentation disease, vitiligo, skin-homing Th17 cells were observed and adoptive transfer of melanocyte-reactive Th17 cells induced rapid depigmentation [2]. From these findings, we speculate that IL-17A might trigger depigmentation of pigment cells in hair follicles, and IL-17A blockade might cancel these effects, resulting in repigmentation of hair.

Taken together, these observations suggest that anti-IL-17A antibody treatment can cause unusual clinical manifestations. These unexpected responses due to IL-17A blockade increase our knowledge on the role of IL-17A in other skin diseases. ■

Disclosure. Financial support: none. Conflict of interest: none.

Department of Dermatology,
University of Occupational and
Environmental Health, 1-1
Iseigaoka, Yahatanishi-ku,
Kitakyushu 807-8555, Japan
<long-ago@med.uoeh-u.ac.jp>

Emi MASHIMA
Yu SAWADA
Takashi YAMAGUCHI
Haruna YOSHIOKA
Shun OHMORI
Sanehito HARUYAMA
Etsuko OKADA
Motonobu NAKAMURA

1. Elkady A, Bonomo L, Amir Y, Vekaria AS, Guttman-Yassky E. Effective use of ustekinumab in a patient with concomitant psoriasis, vitiligo, and alopecia areata. *JAAD Case Rep* 2017; 3: 477-9.

2. Muranski P, Boni A, Antony PA, et al. Tumor-specific Th17-polarized cells eradicate large established melanoma. *Blood* 2008; 112: 362-73.

doi:10.1684/ejd.2018.3327

Granulomatous pigmented purpuric dermatosis containing *Propionibacterium acnes*

Granulomatous pigmented purpuric dermatosis (GPPD) is a rare variant of pigmented purpuric dermatoses [1]. Herein, we report a case of GPPD with localization of *Propionibacterium acnes* (*P. acnes*) in the granuloma, suggesting a sarcoidosis-like aetiology of GPPD.

A 60-year-old woman consulted us for a rash on her extremities. Purpura had appeared on her legs two years before her initial visit to a previous hospital. The lesions were refractory to topical steroids, and she was referred to our hospital. Physical examination revealed purpuric plaques on her extremities (figure 1A). Biopsy specimens from the purpuric lesions on her leg and arm showed epithelioid granulomas with extravasation of red blood cells in the superficial dermis (figure 1C). Red blood cell extravasation was particularly apparent around granulomas, involving capillaries (figure 1D). The granulomas were not associated with hair follicles histopathologically and necrobiosis was not found in the lesions. Histochemical staining (Fite's acid-fast stain, Grocott stain, and PAS) was negative. Chest, head, and neck X-ray and abdominal CT images did not disclose obvious abnormalities. The acetylcholine esterase test and beta-D glucan assay using the patient's serum and the interferon-gamma release assay using the patient's blood were negative. We suspected cutaneous sarcoidosis, and the lesions were treated with photodynamic therapy, which achieved resolution of the lesions.

Five years later, the lesions recurred on the patient's extremities (figure 1B). Skin biopsy specimens from the lesions from both the upper and lower limbs showed the same findings as those observed in the previous biopsies (figure 1E, F). Immunohistochemical analysis with *P. acnes*-specific monoclonal antibodies (PAB antibodies), which specifically react with the *P. acnes* cell membrane [2], revealed small round bodies within the granulomas, which were assumed to be *P. acnes* (figure 1G, H). The PAB antibody used in this study has been proven to react with a *P. acnes*-specific epitope of lipoteichoic acid [2]. In addition, the specificity and sensitivity of the antibody were confirmed previously [2, 3]. The patient refused our proposal of oral antibiotic treatment. Topical clindamycin gel was not effective for the exanthema.

To our knowledge, this is the first case report of GPPD with localization of *P. acnes* in the granuloma. In 2011, Bachmeyer *et al.* reported a case of systemic sarcoidosis with a purpuric skin manifestation that mimicked GPPD [4]. It is difficult to distinguish cutaneous sarcoidosis from pigmented purpuric lesions derived from GPPD based on clinicopathological features, and no clear criteria exist that

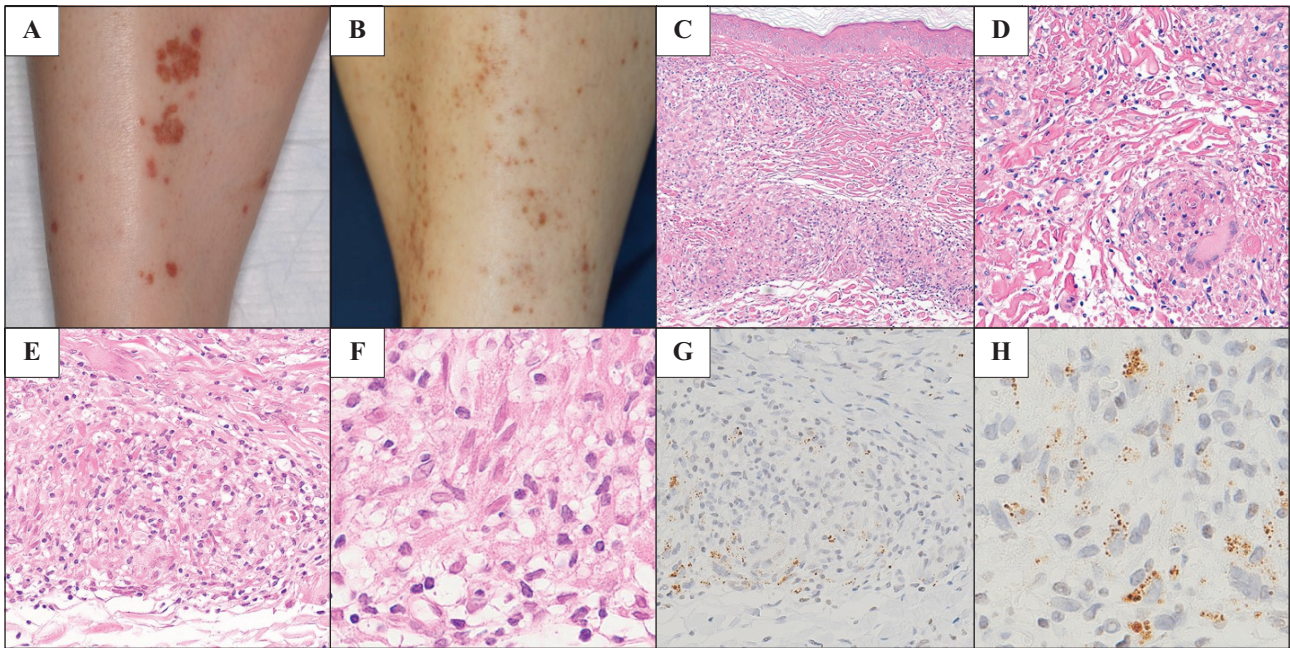


Figure 1. A) Purpuric plaques on the lower leg at the initial hospital visit. B) Recurrent punctate purpura on the lower leg. C, D) Pathological findings from an exanthema on the leg at the initial hospital visit. C) A biopsy specimen taken from a recurrent exanthema on the arm shows epithelioid granuloma in the superficial dermis. D) Involvement of the dermal capillaries and extravasation of red blood cells are also demonstrated (haematoxylin-eosin; original magnification: $\times 100$ [C] and $\times 200$ [D]). E, F) Pathological findings from a recurrent exanthema on the arm show an epithelioid granuloma with giant cells (haematoxylin-eosin; original magnification: $400\times$ [E] and $1,000\times$ [F]). G, H) Immunohistochemistry of the biopsy specimen using PAB antibodies showing small, round bodies within the sarcoid granuloma which are assumed to represent *P. acnes* (original magnification: $400\times$ [G] and $1,000\times$ [H]).

may be used to distinguish between GPPD and cutaneous sarcoidosis with purpuric manifestations if the patient has no other organ involvement [5]. Furthermore, systemic sarcoidosis with asymptomatic lesions of other organs could be misdiagnosed as GPPD.

The localization of *P. acnes* in granulomas is known to be important in the pathogenesis of sarcoidosis [2, 6]. A recent meta-analysis of 11 studies revealed a significant association between sarcoidosis and the presence of *P. acnes*, and the detection of *P. acnes* by immunohistochemistry and western blotting analysis was remarkably specific for sarcoidosis [7]. Therefore, in this case, the localization of *P. acnes* in granulomas suggests a role for sarcoidal reactions in the development of GPPD lesions.

To the best of our knowledge, positive cultures of *P. acnes* from skin lesions of cutaneous sarcoidosis have not been reported. Thus, to date, there is only indirect evidence of the pathogenic role of *P. acnes* infection in cutaneous sarcoidosis. There is only one reported case of cutaneous sarcoidosis associated with *P. acnes* which was a 25-year-old woman with livedoid sarcoidosis on her back and lower legs; the authors considered that specific staining for *P. acnes* within granulomas around the vessels might suggest haematogenous dissemination of *P. acnes*. Because our case had marked vascular involvement and was resistant to topical clindamycin gel, *P. acnes* in the granuloma of our case was also presumed to be disseminated haematogenously rather than transcutaneously.

To detect the localization of *P. acnes* in GPPD lesions, immunohistochemical analysis with PAB antibodies may be a powerful tool. Further research including more GPPD

and sarcoidosis patients is needed to clarify the association between *P. acnes* with GPPD and cutaneous sarcoidosis with pigmented purpuric lesions. ■

Disclosure. Financial support: none. Conflict of interest: none.

¹ Department of Dermatology, Aichi Medical University, Aichi, Japan

² Department of Dermatology, Nagoya University Graduate School of Medicine, Aichi, Japan

³ Department of Surgical Pathology, Aichi Medical University, Aichi, Japan

⁴ Division of Surgical Pathology, Tokyo Medical and Dental University Hospital, Tokyo, Japan

⁵ Department of Human Pathology, Graduate School of Medical Sciences, Tokyo Medical and Dental University, Tokyo, Japan

<yh_jp_hiroto@yahoo.co.jp>

Hiroyuki TAKAMA^{1,2}

Takeshi

YANAGISHITA¹

Jun MUTO¹

Yuichiro OHSHIMA¹

Emiko TAKAHASHI³

Toyonori TSUZUKI³

Keisuke UCHIDA⁴

Yoshinobu EISHI⁵

Masashi AKIYAMA²

Daisuke WATANABE¹

1. Battle LR, Shalin SC, Gao L. Granulomatous pigmented purpuric dermatosis. *Clin Exp Dermatol* 2015; 40: 387-90.

2. Negi M, Takemura T, Guzman J, et al. Localization of Propionibacterium acnes in granulomas supports a possible etiologic link between sarcoidosis and the bacterium. *Mod Pathol* 2012; 25: 1284-97.

3. Suzuki Y, Uchida K, Takemura T, et al. Propionibacterium acnes-derived insoluble immune complexes in sinus macrophages of lymph nodes affected by sarcoidosis. *PLoS One* 2018; 13: e0192408.

4. Bachmeyer C, Eguia B, Callard P, Moguelet P. Purpuric papulonodular sarcoidosis mimicking granulomatous pigmented purpura. *Eur J Dermatol* 2011; 21: 110-1.
5. Sezer E, Yalçın Ö, Erkek E, Şahin S. Pigmented purpuric dermatosis-like sarcoidosis. *J Dermatol* 2015; 42: 629-31.
6. Asahina A, Miura K, Saito I, Oshikata C, Ishii N, Eishi Y. Cutaneous sarcoidosis with livedoid lesions: evidence of the involvement of *Propionibacterium acnes*. *J Dermatol* 2013; 40: 501-2.
7. Zhou Y, Hu Y, Li H. Role of *propionibacterium acnes* in sarcoidosis: a meta-analysis. *Sarcoidosis Vasc Diffuse Lung Dis* 2013; 30: 262-7. doi:10.1684/ejd.2018.3329

***Lobonemoides robustus* Stiasny (jellyfish) anaphylaxis without poly- γ -glutamic acid sensitization**

We read with great interest the two articles entitled “Anaphylactic shock after the ingestion of jellyfish without a history of jellyfish contact or sting” [1] and “Anaphylaxis caused by ingestion of jellyfish” [2] published in this journal. The former case of anaphylaxis occurred after *Cephea cephea* ingestion without any history of jellyfish sting [1], and the latter occurred after *Rhopilema esculentum* ingestion, following sensitization through the skin by jellyfish stings [2]. Oral jellyfish challenge tests or skin-prick tests for poly- γ -glutamic acid (PGA) and natto (fermented soybean) were not conducted in either study. Here, we describe a case of anaphylaxis following *Lobonemoides robustus* (LR) ingestion, without any history of jellyfish sting, in which an oral jellyfish challenge test and skin-prick tests for jellyfish, PGA, and natto were administered. A 14-year-old Japanese boy developed wheezing and dyspnoea 1 hour after he had dinner at home, which included salted jellyfish (LR), and was rushed to our hospital. He had no history of jellyfish contact or stings. On arrival, he was alert, with a blood pressure of 124/74 mm Hg, oxygen saturation level <85%, bilateral bloodshot eyes, nasal discharge, and erythema. He was diagnosed with anaphylaxis. His symptoms resolved after treatment

with intramuscular adrenaline, inhaled procaterol, and intravenous hydrocortisone. Four weeks later, we administered an oral food challenge test to the patient for the same jellyfish. Forty-five minutes after having ingested the jellyfish (30 minutes after initially ingesting 2 g plus 15 minutes after additional ingestion of 6 g), he experienced the same symptoms. We diagnosed the patient with anaphylaxis following jellyfish ingestion. His symptoms resolved with the same treatment, as before. Skin-prick testing for PGA (20 mg/mL) and prick-to-prick tests with the same jellyfish and natto were also performed. The jellyfish yielded a positive result at 15 minutes with a wheal diameter of 5×5 mm, whereas the other results were negative (positive control: 10 mg/mL histamine hydrochloride, with a wheal diameter 10×10 mm; negative control: saline, yielding no wheal). The patient was diagnosed with anaphylaxis due to jellyfish ingestion, but not PGA. There are eight case reports of anaphylaxis following jellyfish ingestion, including ours, in the literature [1-7]. Seven were reported by Japanese physicians [1-6] and five were published after 2017 [3, 5-7]. Although anaphylaxis following jellyfish ingestion has been thought to be rare, reports have rapidly increased recently, especially in Japan, probably due to increased knowledge. Anaphylaxis of unknown cause might include jellyfish anaphylaxis. Regarding the actual type of jellyfish ingested, LR (our case), *Cephea cephea* [1], *Rhopilema esculentum* [2, 6], *Stomolophus meleagris* [3], and *Mastigias papua* [5] have been reported (figure 1). Positive skin-prick test results with LR (our case), *Cephea cephea* [1], *Rhopilema esculentum* [2, 5], *Stomolophus meleagris* [3], *Mastigias papua* [5], and *Nemopilema nomurai* [5] have also been reported (figure 1). In contrast, *Stomolophus meleagris* and *Lobonema smithi* were reported to show negative results on skin-prick testing [5] (figure 1). The results of skin-prick tests for several kinds of jellyfish suggest that the causative antigen may differ for each jellyfish. The oral jellyfish challenge tests with LR (our case) and *Mastigias papua* [5] have been reported, both yielding positive results (figure 1). Five cases have been reported with a history of contact with or stings by jellyfish [2-4, 6, 7].

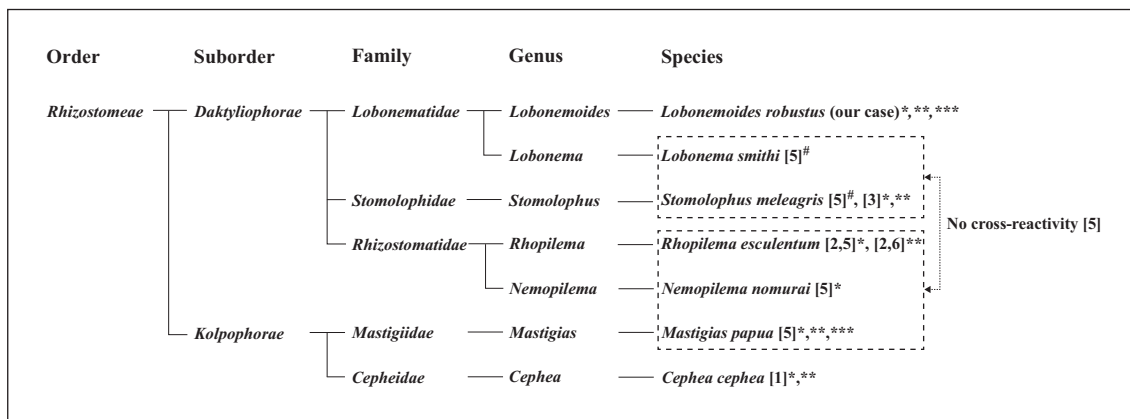


Figure 1. Taxonomic classification of jellyfish associated with anaphylaxis following ingestion. There has been no report of anaphylaxis following ingestion of *Lobonema smithi* or *Nemopilema nomurai*.
[#]Negative skin prick test result. *Positive skin prick test result. **Actual type of jellyfish ingested. ***Positive oral challenge test.