

A characteristic occipital epileptiform EEG pattern in ADCK3-related mitochondrial disease

Vibeke Arntsen¹, Trond Sand^{1,2}, Omar Hikmat^{3,4}, Christian Samsonsen^{1,2}, Laurence A. Bindoff^{4,5}, Eylert Brodtkorb^{1,2}

¹ Department of Neurology and Clinical Neurophysiology, St. Olavs Hospital, Trondheim University Hospital, Norway

² Department of Neuromedicine and Movement Science, Norwegian University of Science and Technology (NTNU), Trondheim, Norway

³ Department of Paediatrics and Adolescent Medicine, Haukeland University Hospital, Norway

⁴ Department of Clinical Medicine (K1), University of Bergen, Norway

⁵ Neuro-SysMed, Center of Excellence for Clinical Research in Neurological Diseases, Haukeland University Hospital, Norway

Received October 21, 2020:
Accepted December 5, 2020

ABSTRACT

Objective. ADCK3-related disease is a mitochondrial disorder associated with an abnormality of coenzyme Q10 metabolism. Ataxia and epilepsy are common, and the phenotype overlaps with other mitochondrial encephalopathies, particularly POLG-related disease. CoQ10 supplementation may be beneficial. We have noted a remarkable epileptiform pattern in ADCK3-related encephalopathy, and since EEG studies in this rare condition are limited, we wished to assess the evolution of EEG characteristics in patients with this disorder.

Methods. All EEG recordings of the four known patients from Mid-Norway were systematically reviewed. EEG graphoelements were classified according to the standardized computer-based organized reporting of EEG (SCORE) and international glossary terms. The evolution of EEG features was assessed. A total of 96 recordings spanning over 15-32 years were available, with a mean of 24 per patient (range: 17-28). Altogether, 50 digital recordings were reviewed, including four long-term and 46 selected paper segments.

Results. In three patients, EEG showed prominent bilateral asynchronous and synchronous epileptiform discharges in occipital and posterior-temporal regions. This intense activity included multiple epileptiform graphoelements, which occurred continuously, nearly continuously or in prolonged runs. The findings remained stable over many years.

Significance. Although the number of patients is small, we suggest that interictal EEG findings of continuous/nearly continuous bi-occipital spike-waves may serve as a biomarker for this potentially treatable condition. This peculiar EEG pattern might help to differentiate ADCK3-related disease from the more common POLG-related disease, which is usually characterized by lateralized or focal slowing with more sporadic epileptiform elements of similar topography.

Key words: ADCK3-related disease; CoQ10 deficiency; EEG; occipital epilepsy; POLG-related disease

• **Correspondence:**
Vibeke Arntsen
Department of Neurology and Clinical Neurophysiology, St. Olavs Hospital, Trondheim University Hospital 7006 Trondheim, Norway
<vibeke.arntsen@stolav.no>

The aarF domain-containing kinase 3 (ADCK3) is a mitochondrial protein belonging to the atypical kinase family. Loss of ADCK3 function results in coenzyme Q10 (CoQ10) deficiency and mitochondrial failure [1, 2]. CoQ10, also known as ubiquinone, is a small lipophilic molecule that has a central role

in mitochondrial respiration. Primary CoQ10 deficiency is caused by defects in the biosynthesis of ubiquinone that result in clinically and genetically heterogeneous conditions in which epilepsy is a prominent feature [3]. Autosomal recessive ADCK3 mutations are responsible for the most frequent

form of hereditary CoQ10 deficiency, manifesting with mainly spinocerebellar ataxia and seizures [3-5]. Other symptoms include exercise intolerance, dystonia and cognitive impairment [4, 6]. Presentation may range from infancy to late onset, and the disease progression is typically slow with variable severity. Epilepsy may be the presenting symptom, but in the majority, epilepsy is preceded by other symptoms [5, 7].

The clinical spectrum of ADCK3-related disease overlaps with other mitochondrial disorders, particularly the juvenile/adult-onset form of polymerase gamma (POLG)-related disease [5, 8]. Both POLG and ADCK3-related disease, as well as mitochondrial encephalomyopathy with lactic acidosis and stroke-like episodes (MELAS), cause cortical lesions with occipital lobe predominance. In these mitochondrial encephalopathies, seizure onset and EEG abnormalities also have a posterior predilection [5, 9].

Response to CoQ10 supplementation is variable in patients with ADCK3 mutations [5, 10-15]. While it is unlikely that treatment will reverse tissue damage, disease progression may be slowed or stopped [13], meaning that prompt diagnosis and treatment are crucial [3], as is the need for relevant clinical biomarkers. The addition of EEG to the diagnostic algorithm used in patients with mitochondrial disease and epilepsy has been suggested earlier [16, 17]. As we have noted a remarkable epileptiform pattern in ADCK3-related encephalopathy, we wished to assess the evolution of EEG characteristics over time in patients with this disorder.

Methods

We reviewed all available EEG recordings in four patients with known ADCK3-related epilepsy living in Mid-Norway. Clinical and genetic features of these patients have previously been reported [5]. The patients had slowly progressive ataxia, with cerebellar atrophy and epilepsy, which in three, was complicated by episodes of status epilepticus and clinical and imaging evidence of stroke-like episodes. Two were siblings of whom one died during *epilepsia partialis continua* at the age of 22 years (Patient 3). The data on phenotype and genotype, summarized by Hikmat *et al.* (2016), are presented in *table 1*. Patient 1 and 2 had sporadic focal to bilateral tonic-clonic seizures (FTCs) years apart, and Patient 4 had severe epilepsy with nearly daily seizures.

EEG elements were classified according to the standardized computer-based organized reporting of EEG (SCORE) and the international glossary of terms [18, 19]. The EEG features and their evolution were assessed along with the various seizure types. The

following EEG variables were evaluated: waveform, frequency, amplitude, localization, distribution, quantity, variability, morphological characteristics of interictal and ictal epileptiform activity, reactivity to eye opening and provocations (hyperventilation and photostimulation).

A total of 96 EEG recordings were assessed (*table 2*). The number of EEGs per patient ranged from 17 to 28 (mean: 24). Fifty were digital recordings and 46 were selected segments of paper recordings. Most were standard recordings; four were taken from long-term (24 hours) monitoring (LTM). The first available EEG was recorded at various ages, with a range of 2-10 years. The recording periods spanned from 1981 to 2020, and follow-up was 15 years for the deceased patient and between 23 and 32 years for the three others (*figures 1-4*).

Written informed consent from the patients or their parents had been obtained.

Results

Interictal epileptiform EEG activity

The findings are summarized for each patient in *table 2*. Patients 1-3: EEG showed prominent bilateral asynchronous and synchronous epileptiform discharges in occipital and posterior-temporal regions (*figures 1-3*). This activity was continuous in Patient 1 (*figure 1*) and nearly continuous in Patients 2 and 3 (*figures 2 and 3*). In these patients, the occipital epileptiform pattern was present in the first EEG, even prior to seizures in Patient 3. The abnormality persisted in all later recordings. Graphoelements were mainly high-voltage, up to 300 mV, atypical spike-waves. Spike-wave frequency varied from 2.5 to 4 Hz in the majority of recordings. Spikes and polyspike elements of variable morphology merged with spike-wave runs and 3-5 Hz slowing. The epileptiform activity was markedly suppressed by eye opening and increased during photic stimulation (*table 2*).

Patient 4: The first EEG at age two years prior to seizure occurrence was unremarkable. After epilepsy onset, EEG mostly showed multifocal and bilateral epileptiform discharges, particularly in the frontotemporal areas with independent posterior involvement, but the pattern varied (*figure 4*). We observed spike-waves, sharp-waves and sharp-and-slow-waves at up to 600 mV with variable 1.5-4 Hz frequency, as well as multifocal moderate voltage spikes and sometimes polyspikes.

Background EEG activity

Patients 1-3: The background activity was normal or nearly normal. In the first recordings, discrete

▼ **Table 1.** Demographic, clinical and MRI data (partly summarized from Hikmat *et al.* 2016).

Patients	1	2 ¹	3 ¹	4
Gender	Female	Male	Female	Female
Age at study (years)	39	39	22 ²	27
Age first seizure (years)	7	7	6	3
First seizure type	FTC	F	F	FTC
Later seizure types	FTC; M	FTC; F	FTC; F; EPC	FTC; multiple, including F, M and EPC
Antiseizure medications	Eslicarbazepine	Lamotrigine, valproate.	Carbamazepine, clonazepam, phenobarbital, topiramate	Clonazepam lamotrigine, levetiracetam, valproate
Other clinical signs and symptoms	From early teens: ataxia; mild dysarthria; tremor	From pre-school age: ataxia; moderate cognitive impairment; dysarthria	From age 3: ataxia; moderate cognitive impairment; dysarthria; tremor	From age 2: ataxia; severe cognitive and motor regression; wheelchair-bound from age 12
Brain MRI	Cerebellar atrophy	Cerebellar atrophy; stroke-like lesions temporo-occipital left and occipital right	Cerebellar atrophy; multiple bilateral stroke-like lesions	Cerebellar atrophy; global substance loss; extensive bi-occipital gliosis
Genotype	c.895C>T, p.R299W homozygous	c.895C>T, p.R229W; c.1732T>G, p.F578V compound heterozygous	c.895C>T, p.R229W; c.1732T>G, p.F578V compound heterozygous	c.895C>T, p.R299W homozygous
CoQ10 treatment	From age 33	From age 33	No	Short term at age 18
Treatment effect	Halt of progression of ataxia	Some improvement of balance, ataxia and speech		No improvement

FTC: focal to tonic-clonic seizures; F: focal seizures; M: myoclonic jerks; EPC: epilepsia partialis continua.

¹Siblings.

²Died from status epilepticus at age 22.

generalized slowing, mainly in the theta range, was present. In the frontotemporal regions, occasional intermittent bilateral 2-3 Hz waves occurred, sometimes as short generalized bursts.

Patient 4: Severe generalized slowing, mostly in the 2-5 Hz frequency range, was seen in all recordings, sometimes accentuated in epochs with variable location.

Posterior dominant EEG rhythm

Patient 1 had some intermittent 9.5 Hz rhythmical activity mostly in the parietal regions while her occipital activity was dominated by continuous epileptiform discharges. Fragmented 9.5-10.5 Hz occipital alpha

rhythm was identified in Patients 2 and 3, whereas a dominant posterior rhythm was absent in Patient 4.

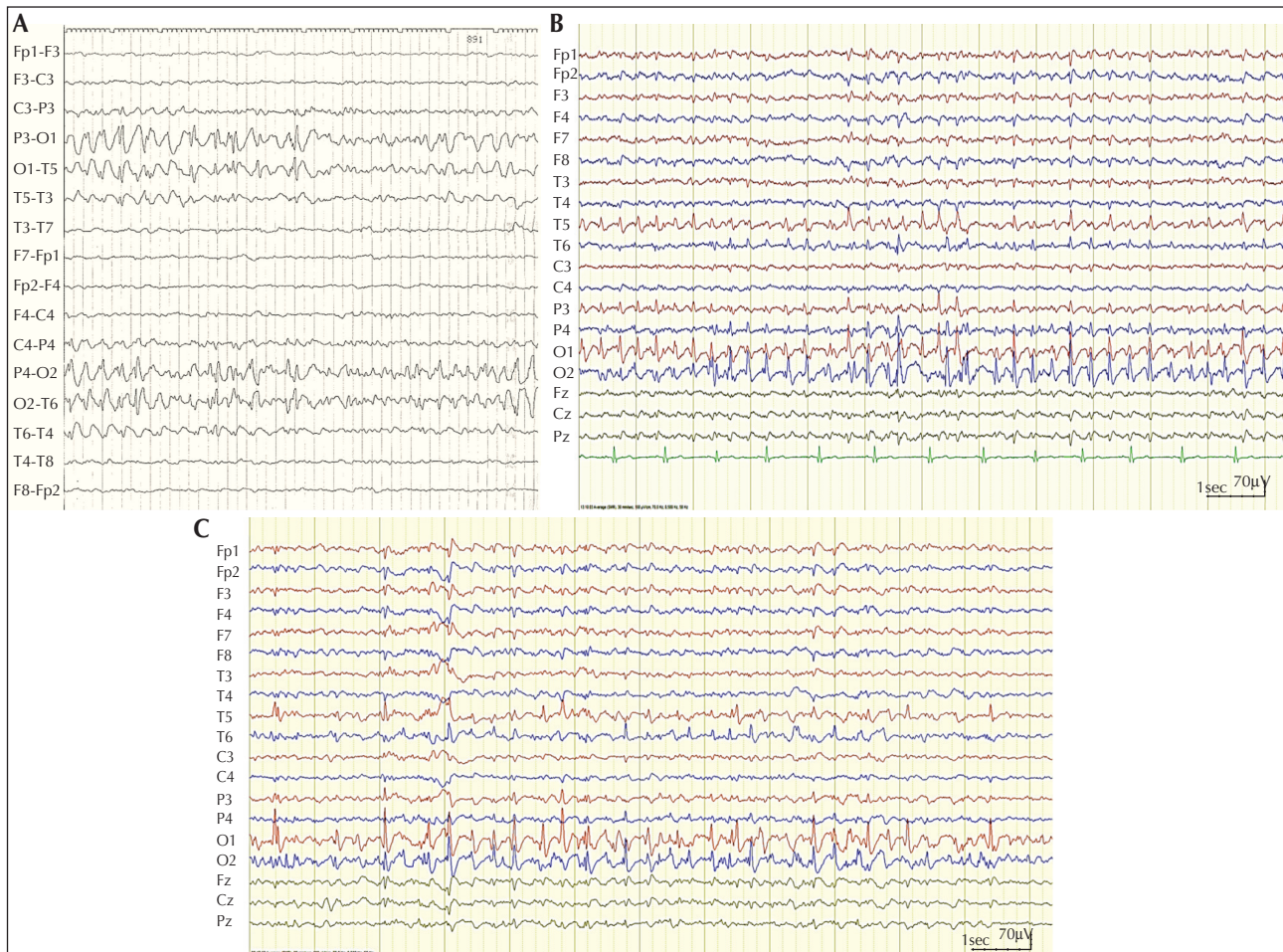
Evolution of EEG findings

The EEG patterns remained unchanged for many years in Patients 1-3. A mild increase in the occurrence of bursts with bilateral generalized epileptiform discharges with multifocal elements and slowing was seen at adult age (Patient 3 at 18 years, Patient 1 at 33 years). In Patient 2, the EEG changed in the form of decreased occurrence and voltage of the epileptiform discharges and less slowing in the posterior regions at the age of 38.

▼ **Table 2.** EEG recordings and interictal epileptiform abnormalities.

Patients	1	2	3	4
Number of recordings	28	17	28	23
Age at first recording (years)	10	7	6	2
Age range (years)	10-39	6-39	6-22	2-26
EEG type				
Standard	27	16	28	21
Long-term monitoring	1	1	0	2
Digital	19	11	0	20
Paper segments	9	6	28	3
Epileptiform activity				
Localization	Occipital/temporal (parietal)	Occipital/temporal	Occipital/temporal	Fronto-temporal and temporo-parieto-occipital predominance
Type	Bilateral /synchronous/asynchronous	Bilateral /synchronous/asynchronous	Bilateral /synchronous/asynchronous	Multifocal and bilateral synchronous/asynchronous
Persistence	Continuous	Nearly continuous	Nearly continuous/prolonged runs	Episodic. Variation within/between recordings
Evolution	Largely unchanged	Largely unchanged until improvement from age 38	Largely unchanged until recurrent EPC during last two years of life	Less posterior activity; focal activity in left temporal region, partly as EPC, from age 13-14
Suppression upon eye opening	yes	yes	yes	yes
Increase upon photostimulation	yes	yes	yes	yes
Epileptiform graphoelements				
Spikes	++	++	+++	++
Spike-waves and slow waves	+++	+++	+++	++
Polyspikes	++	++	++	++
Polyspike-waves	++	++	+	+
Sharp-waves	+	+	+	+++
Sharp-wave and slow waves	-	-	-	+++

EPC: epilepsy partialis continua; -/+/+/++/+++; not present/discrete/occasional/frequent.



■ **Figure 1.** EEG of Patient 1. (A) The first recording at age 10 years shows continuous bilateral synchronous and asynchronous epileptiform activity with discrete slowing in the post-temporal and occipital regions (paper segment). Montage: longitudinal bipolar. Trace duration: 10 s. (B, C) The principal findings of continuous bilateral synchronous and asynchronous epileptiform activity with occipital predominance persist from the first recording at 10 years (A) to the recording at 22 years (B) and at 38 years (C). Montage: average reference; 30 mm/s; 12.4 s trace duration; 100 mV/cm; High-pass filter (HF) 70 Hz; low pass filter (LF) 0.50 Hz; notch 50 Hz.

Ictal EEG recordings

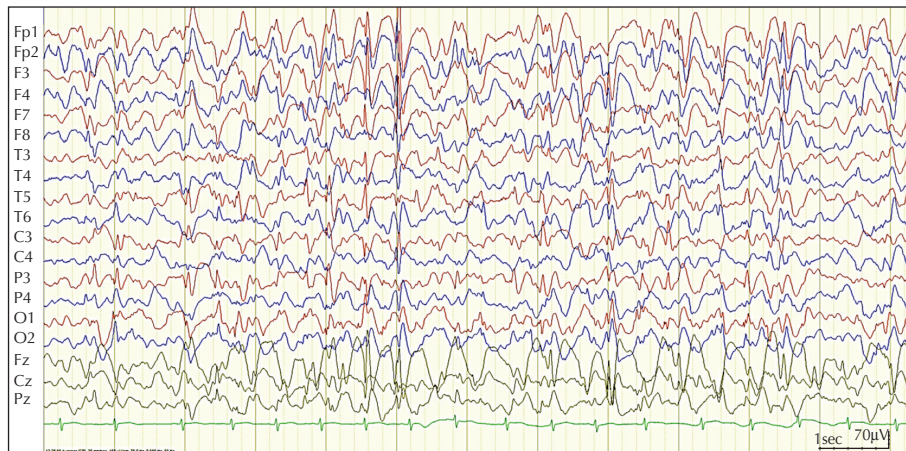
Patient 4: During *epilepsia partialis continua* at age 13-14, the EEG showed focal epileptiform discharges mainly in the left temporal and partly in the occipital areas. During later LTM recordings, runs of generalized fast activity, lasting up to 30 seconds, were not clinically recognized.

Discussion

The topography of EEG abnormalities in ADCK3-related disease is consistent with the reported predilection

for occipital lobe involvement in mitochondrial disorders. The characteristic EEG graphoelements associated with this, and indeed other variants of CoQ10 deficiency, have, however, received little attention [1, 3-6, 11, 13, 20-23]. Interestingly, even prior to the detection of ADCK3 mutations, bi-occipital epileptiform activity was emphasized in encephalomyopathies associated with CoQ10 deficiency, even in the absence of seizures [24, 25].

In the present study, three of our four patients exhibited a peculiar and intense posterior epileptiform pattern with occipital predominance, in one patient even prior to seizure onset. Remarkably, the activity occurred continuously or nearly continuously in prolonged runs. These findings prompted a large



■ **Figure 4.** Patient 4. Interictal EEG at age seven years shows combined multifocal and bilateral synchronous and asynchronous epileptiform discharges with spike focus in the posterior region, mostly on the left side. Montage: average reference; 30 mm/s; 12.4 s trace duration; 150 mV/cm; HF 70 Hz; LF 0.5 Hz; notch 50 Hz.

number of follow-up recordings. The abnormalities were stable over many years, albeit with some progression to occasional multifocal involvement of the frontotemporal areas, with a generalized non-specific abnormality. Three to four years after starting CoQ10 treatment, epileptiform activity was reduced in Patient 2, suggesting potential improvement. Patient 4 also had abundant bilateral temporo-occipital spikes, but less striking due to widespread epileptiform activity (*figure 4*), suggesting a more extensive dysfunction or a propagation to anterior networks.

The characteristic interictal bi-occipital EEG abnormalities in ADCK3-related disease are consistent with focal-onset seizures. The seizure disorder is classifiable as focal epilepsy with a combined genetic, metabolic and conceivably even a secondary structural aetiology [26]. In mitochondrial disorders, such as POLG disease, so-called stroke-like lesions are often transient and thought to be due to neuronal adenosine triphosphate depletion driven by ongoing seizure activity [27, 28]. The common denominator of these disorders is mitochondrial energy failure, although of different genetic aetiologies. The reason for the posterior location has been explained by the fact that the visual cortex is among the most active cerebral regions, thus rendering this part of the brain more vulnerable to energy collapse during ictal activity. Three of the patients had stroke-like lesions; in Patient 2 and 4 particularly in the occipital lobes and in Patient 3 more widespread (*table 1*) [5].

In POLG disease, EEG abnormalities differ from those seen in our patients, being more focal or lateralized and dominated by pronounced slowing and/or periodicity of 0.5-2 Hz with relatively scarce interictal epileptiform elements [16, 28-33]. The present patients showed pronounced runs of spike-waves along with

an abundance of various epileptiform graphoelements, only occasionally accompanied by explicit slowing in the posterior areas (*table 2, figures 1-3*). Moreover, in POLG disease, the EEG pattern varies, often with only initial occipital predilection [28, 30], whereas the unusual pattern seen in the present patients appeared to remain stable over many years.

It has been suggested that rhythmic high-amplitude delta activity with superimposed spikes (RHADS) represents a reliable early pathognomonic EEG marker of severe and early-onset POLG disease (Alpers' disease). These changes may fluctuate over time [16]. Such elements did not occur in our patients. No other characteristic EEG markers have been linked to mitochondrial disorders [3, 17].

Occipital lobe epilepsies have multiple aetiologies and a variable prognosis, and they are relatively uncommon. They include self-limited focal childhood epilepsies of the Gastaut and Panayiotopolous type, SCN8A-related epilepsy, epilepsies due to structural lesions, and mitochondrial disorders. The majority of lesional epilepsies are limited to one hemisphere. The EEG abnormalities in the Panayiotopolous and Gastaut syndromes usually share a morphology with other self-limited childhood epilepsies, with variable negative diphasic slow spikes followed by a slow wave, isolated and in clusters [34]. Although similar in location, they are distinctly different from the nearly continuous pattern reported here. Patients with the developmental and epileptic encephalopathy associated with SCN8A mutations often exhibit early multifocal and bilateral epileptiform abnormalities with temporo-occipital predominance, but the EEG findings also differ in that the epileptiform discharges with high-amplitude sharp waves are infrequent and multifocal with progressive background slowing [35].

The patients we report confirm the broad phenotypic spectrum of ADCK3-related disease [6], even within the same family (Patients 2 and 3), as well as in unrelated subjects with the same genotype (Patients 1 and 4). The phenotypes differed conspicuously and seemed to correlate to age at onset. They ranged from insidious mild to moderate ataxia with little overt cognitive symptoms, satisfactory seizure control and retained vocational abilities in adult age (Patient 1) to early-onset encephalopathy with severe and progressive ataxia with wheelchair dependency and profound intellectual disability (Patient 4). Curiously, the intensity of the characteristic EEG pattern was independent of the severity of the disorder. In fact, the patient with the least severe symptoms showed the most distinct EEG pattern with continuous epileptiform activity that was unchanged for nearly three decades, despite the absence of evident focal cortical MRI lesions (Patient 1) (*figure 1*). The epileptiform activity thus appeared to be independent of MRI abnormalities. In Patients 2 and 3 with mild-to-moderate intellectual disability, the pattern was nearly continuous in parts of each recording (*figures 2 and 3*). In the most severely affected patient (Patient 4), the first EEG prior to seizure onset was unremarkable, but later EEG and MRI both suggested a more widespread cerebral expression (*table 1, figure 4*).

The present patient series suggests that this peculiar and persistent epileptiform pattern in patients with epilepsy and ataxia should raise a suspicion of ADCK3-related disease, although its absence does not rebut the diagnosis. In accordance with previous reports [10-13, 15], patients showed a variable response to CoQ10 supplementation [5]. In Patient 2, the epileptiform changes appeared to decline after treatment and he also experienced improvement in ataxia. Seizures were well controlled for several years, but breakthrough did occur during CoQ10 treatment. In other studies, no definite effect on seizures was demonstrated [14, 36], although a marked improvement of myoclonus was reported in one patient [11]. Patient 1 experienced a halt in the progression of her ataxia and no seizure recurrence within the last four years with unchanged antiepileptic drug treatment. Although anecdotal, this course is promising, as she previously had sporadic FTCs and myoclonic jerks.

The limited number of included patients with this rare disorder is an obvious weakness of the present retrospective survey. Nevertheless, the significance of this characteristic EEG pattern is strengthened by its persistence in numerous available recordings over many years. More studies in a larger number of patients are needed to confirm these findings.

Conclusion

ADCK3-related disease with ataxia and seizures shares many features with the more common POLG-related disease, but the molecular pathogenesis of mitochondrial dysfunction is dissimilar and potential precision treatment is available. The present study suggests that EEG abnormalities in ADCK3-related disease differ sufficiently from those associated with POLG disease to be useful for differential diagnosis. A continuous or nearly continuous bi-occipital epileptiform pattern, which persists over time, should lead to the suspicion of the ADCK3-related form of mitochondrial disorder. Early recognition and treatment to limit tissue damage is crucial, and EEG is a readily available tool which may help to differentiate the phenotype of ADCK3 disease from other mitochondrial disorders. ■

Supplementary data.

Summary didactic slides are available on the www.epilepticdisorders.com website.

Disclosures

None of the authors have any conflict of interest to declare.

References

1. Blumkin L, Leshinsky-Silver E, Zerem A, Yosovich K, Lerman-Sagie T, Lev D. Heterozygous mutations in the ADCK3 gene in siblings with cerebellar atrophy and extreme phenotypic variability. *JIMD Reports* 2014; 12: 103-7.
2. Turunen M, Olsson J, Dallner G. Metabolism and function of coenzyme Q. *Biochim Biophys Acta* 2004; 1660: 171-99.
3. Rahman S, Clarke CF, Hirano M. 176th ENMC international workshop: diagnosis and treatment of coenzyme Q₁₀ deficiency. *Neuromuscul Disord* 2012a; 22: 76-86.
4. Barca E, Musumeci O, Montagnese F, Marino S, Granata F, Nunnari D, et al. Cerebellar ataxia and severe muscle CoQ₁₀ deficiency in a patient with a novel mutation in ADCK3. *Clin Genet* 2016; 90: 156-60.
5. Hikmat O, Tzoulis C, Knappskog PM, Johansson S, Boman H, Sztromwasser P, et al. ADCK3 mutations with epilepsy, stroke-like episodes and ataxia: a POLG mimic? *Eur J Neurol* 2016; 23: 1188-94.
6. Horvath R, Czermin B, Gulati S, Demuth S, Houge G, Pyle A, et al. Adult-onset cerebellar ataxia due to mutations in CABP1/ADCK3. *J Neurol Neurosurg Psychiatry* 2012a; 83: 174-8.
7. Rahman S. Mitochondrial disease and epilepsy. *Dev Med Child Neurol* 2012b; 54: 397-406.
8. Hikmat O, Naess K, Engvall M, Klingenberg C, Rasmussen M, Tallaksen CM, et al. Simplifying the clinical classification of polymerase gamma (POLG) disease based on age of onset; studies using a cohort of 155 cases. *J Inherit Metab Dis* 2020; 43: 726-36.

9. Bindoff LA, Engelsen BA. Mitochondrial diseases and epilepsy. *Epilepsia* 2012; 53: 92-7.
10. Horvath Rb. Update on clinical aspects and treatment of selected vitamin-responsive disorders II (riboflavin and CoQ 10). *J Inherit Metab Dis* 2012b; 35: 679-87.
11. Liu Y-T, Hersheson J, Plagnol V, Fawcett K, Duberley KEC, Preza E, et al. Autosomal-recessive cerebellar ataxia caused by a novel ADCK3 mutation that elongates the protein: clinical, genetic and biochemical characterisation. *J Neurol Neurosurg Psychiatry* 2014; 85: 493-8.
12. Chang A, Ruiz-Lopez M, Slow E, Tarnopolsky M, Lang AE, Munhoz RP. ADCK3-related coenzyme Q₁₀ deficiency: a potentially treatable genetic disease. *Mov Disord Clin Pract* 2018; 5: 635-9.
13. Pineda M, Montero R, Aracil A, O'Callaghan MM, Mas A, Espinos C, et al. Coenzyme Q(10)-responsive ataxia: 2-year-treatment follow-up. *Mov Disord* 2010; 25: 1262-8.
14. Rahman S. Advances in the treatment of mitochondrial epilepsies. *Epilepsy Behav* 2019; 101: 106546.
15. Schirinzi T, Favetta M, Romano A, Sancesario A, Summa S, Minosse S, et al. One-year outcome of coenzyme Q₁₀ supplementation in ADCK3 ataxia (ARCA2). *Cerebellum Ataxias* 2019; 6: 15.
16. van Westrhenen A, Cats EA, van den Munckhof B, van der Salm SMA, Teunissen NW, Ferrier CH, et al. Specific EEG markers in POLG1 Alpers' syndrome. *Clin Neurophysiol* 2018; 129: 2127-31.
17. Chevallier JA, Von Allmen GK, Koenig MK. Seizure semiology and EEG findings in mitochondrial diseases. *Epilepsia* 2014; 55: 707-12.
18. Beniczky S, Aurlien H, Brøgger JC, Hirsch LJ, Schomer DL, Trinka E, et al. Standardized computer-based organized reporting of EEG: SCORE – Second version. *Clin Neurophysiol* 2017; 128: 2334-46.
19. Kane N, Acharya J, Beniczky S, Caboclo L, Finnigan S, Kaplan PW, et al. A revised glossary of terms most commonly used by clinical electroencephalographers and updated proposal for the report format of the EEG findings. Revision 2017. *Clin Neurophysiol Pract* 2017; 2: 170-85.
20. Lagier-Tourenne C, Tazir M, López LC, Quinzii CM, Assoum M, Drouot N, et al. ADCK3, an ancestral kinase, is mutated in a form of recessive ataxia associated with coenzyme Q₁₀ deficiency. *Am J Hum Genet* 2008; 82: 661-72.
21. Mollet J, Delahodde A, Serre V, Chretien D, Schlemmer D, Lombes A, et al. CABC1 gene mutations cause ubiquinone deficiency with cerebellar ataxia and seizures. *Am J Hum Genet* 2008; 82: 623-30.
22. Terracciano A, Renaldo F, Zanni G, D'Amico A, Pastore A, Barresi S, et al. The use of muscle biopsy in the diagnosis of undefined ataxia with cerebellar atrophy in children. *Eur J Paediatr Neurol* 2012; 16: 248-56.
23. Emmanuele V, López LC, Berardo A, Naini A, Tadesse S, Wen B, et al. Heterogeneity of coenzyme Q₁₀ deficiency: patient study and literature review. *Arch Neurol* 2012; 69: 978-83.
24. Ogasahara S, Engel AG, Frens D, Mack D. Muscle coenzyme Q₁₀ deficiency in familial mitochondrial encephalomyopathy. *Proc Natl Acad Sci U S A* 1989; 86: 2379-82.
25. Sobreira C, Hirano M, Shanske S, Keller RK, Haller RG, Davidson E, et al. Mitochondrial encephalomyopathy with coenzyme Q₁₀ deficiency. *Neurology* 1997; 48: 1238-43.
26. Scheffer IE, Berkovic S, Capovilla G, Connolly MB, French J, Guilhoto L, et al. ILAE classification of the epilepsies: position paper of the ILAE commission for classification and terminology. *Epilepsia* 2017; 58: 512-21.
27. Hikmat O, Eichele T, Tzoulis C, Bindoff LA. Understanding the epilepsy in POLG related disease. *Int J Mol Sci* 2017; 18: 1845.
28. Hikmat O, Tzoulis C, Chong WK, Chentouf L, Klingenberg C, Fratter C, et al. The clinical spectrum and natural history of early-onset diseases due to DNA polymerase gamma mutations. *Genet Med* 2017; 19: 1217-25.
29. Anagnostou M-E, Ng YS, Taylor RW, McFarland R. Epilepsy due to mutations in the mitochondrial polymerase gamma (POLG) gene: a clinical and molecular genetic review. *Epilepsia* 2016; 57: 1531-45.
30. Engelsen BA, Tzoulis C, Karlsen B, Lillebø A, Laegreid LM, Aasly J, et al. POLG1 mutations cause a syndromic epilepsy with occipital lobe predilection. *Brain* 2008; 131: 818-28.
31. Martikainen MH, Päivärinta M, Jääskeläinen S, Majamaa K. Successful treatment of POLG-related mitochondrial epilepsy with antiepileptic drugs and low glycaemic index diet. *Epileptic Disord* 2012; 14: 438-41.
32. Roshal D, Glosser D, Zangaladze A. Parieto-occipital lobe epilepsy caused by a POLG1 compound heterozygous A467T/W748S genotype. *Epilepsy Behav* 2011; 21: 206-10.
33. Tzoulis C, Engelsen BA, Telstad W, Aasly J, Zeviani M, Winterthun S, et al. The spectrum of clinical disease caused by the A467T and W748S POLG mutations: a study of 26 cases. *Brain* 2006; 129: 1685-92.
34. Vigeveno F, Specchio N, Fejerman N. Idiopathic focal epilepsies. *Handb Clin Neurol* 2013; 111: 591-604.
35. Gardella E, Marini C, Trivisano M, Fitzgerald MP, Alber M, Howell KB, et al. The phenotype of SCN8A developmental and epileptic encephalopathy. *Neurology* 2018; 91: e1112-e24.
36. Horvath R, Schneiderat P, Schoser BGH, Gempel K, Neuen-Jacob E, Plöger H, et al. Coenzyme Q₁₀ deficiency and isolated myopathy. *Neurology* 2006; 66: 253-5.

TEST YOURSELF

- (1) What is the main differential diagnosis of ADCK3-related disease with ataxia and epilepsy?**
- (2) Why is early recognition of ADCK3-related disease essential?**
- (3) What are the characteristic EEG features of this disorder?**

Note: Reading the manuscript provides an answer to all questions. Correct answers may be accessed on the website, www.epilepticdisorders.com, under the section "The EpiCentre".
