

An embarrassing aura

Laura Lacazette^{1,2}, Olivier Boucher³, Ismail Mohamed⁴,
Alain Bouthillier⁵, Dang Khoa Nguyen¹

¹ Division of Neurology, CHUM, Université de Montréal, Montreal, Canada

² Faculty of Medicine, Université de Bordeaux II, Bordeaux, France

³ Division of Psychology, CHUM, Montreal, Canada

⁴ Division of Neurology, Department of Pediatrics, University of Alabama, Birmingham, USA

⁵ Division of Neurosurgery, CHUM, Université de Montréal, Montreal, Canada

Received August 10, 2018; Accepted March 07, 2019

ABSTRACT – We report the case of a patient with epilepsy who described shame and embarrassment at the beginning of his seizures. Non-invasive and invasive presurgical investigations led to resection of the polar and ventromedial portions of the right frontal lobe. Following the surgery, the patient continued to have seizures, albeit only nocturnal and with no clear aura. Subsequent removal of the right anterior insula at the junction with the frontal operculum and the posterior orbitofrontal cortex led to seizure freedom, but the patient reported a loss of motivation and stamina and was declared unfit for work. The underlying network of negative moral emotions is briefly discussed.

Key words: embarrassment, shame, aura, epilepsy, insula, frontal lobe epilepsy, negative moral emotions, magnetoencephalography

In this report, we present and discuss the case of a patient with epilepsy whose seizures started with a peculiar aura of shame and embarrassment. These feelings are uncommonly encountered in seizures and their cortical localization is not well known.

Case report

A left-handed, 41-year-old man with no significant past medical history started having seizures at age 35 years. Spells were characterized by an aura of shame and embarrassment (as if he had done something wrong in public) coupled with an ill-defined epigastric sensation followed by impaired awareness, facial flushing, and occasional manual

automatisms. These seizures typically lasted for approximately 20 seconds and recurred daily; they rarely evolved into bilateral tonic-clonic seizures. No other autonomic symptoms concomitant with the feeling of embarrassment were present. After failing 10 different antiepileptic drugs, the patient was evaluated for potential epilepsy surgery. MRI failed to disclose an epileptogenic lesion. Video-surface EEG monitoring showed bifrontal spikes with right-sided predominance; seizures were associated with a diffuse attenuation followed by rhythmic activity, maximum over the right hemisphere. [¹⁸F] Fluorodeoxyglucose positron emission tomography revealed mild hypometabolism of the right frontopolar region.

Correspondence:

Dang Khoa Nguyen
CHUM,
1000 Saint-Denis,
Montréal,
Canada, H2X 0C1
<d.nguyen@umontreal.ca>

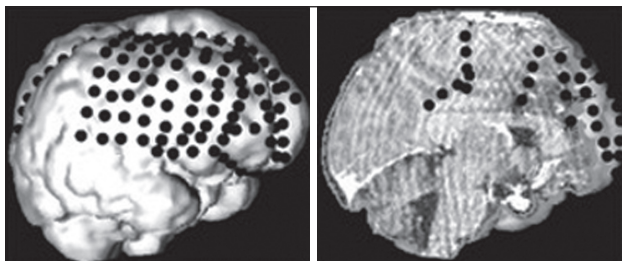


Figure 1. 3-D representation of intracranial EEG electrode contacts: a 4 × 8 subdural grid was positioned over the dorsolateral frontal lobe as well as several (11) subdural strips to sample the ventromedial prefrontal cortex, the cingulate gyrus, the orbitofrontal, and frontopolar regions.

Ictal single photon emission computed tomography disclosed multiple activation sites including the right frontopolar region. On neuropsychological examination, the patient showed a high error rate on a formal visual selective attention task (Ruff 2 & 7 Selective Attention Test; Ruff and Allen, 1996) and impaired cognitive flexibility as indexed by increased errors and slow execution speed on the Switching condition of the Delis-Kaplan Executive Function System - Color-Word Interference Test (Delis *et al.*, 2001). An intracranial EEG study was subsequently performed, mainly targeting the right frontal lobe (orbitofrontal cortex, inferior, middle and superior frontal gyri, medial frontal gyrus, and cingulate gyrus) (*figure 1*). Recorded seizures were associated with low-voltage fast discharges at several contacts located in the right frontopolar region, the anterior medial frontal region, and the inferior frontal gyrus. Guided by these findings, an extensive right anterior frontal cortectomy was performed. Pathological examination of the resected tissue revealed subtle architectural abnormalities (*i.e.* more than the expected number of neurons within the cortical molecular layer and underlying white matter, focal loss of the cortical lamination pattern, malorientation of some cortical pyramidal neurons, and clustering of cortical neurons), suggesting a mild malformation of cortical development (“microdysgenesis”).

Within six months, seizures unfortunately recurred at a frequency of one to four per month. Seizures were now only sleep-related however, and characterized by sudden awakening, hypertonia, and pedalling. A post-operative magnetoencephalographic study (MEG), analysed using the equivalent current dipole (ECD) model, identified a few scattered sources in the right perisylvian area. Right-sided bursts of focal gamma activity were also observed during the study; MEG localization of these high-frequency oscillations using an event-related Beamformer suggested a probable source in the vicinity of the right anterior insula

(*figure 2B*) (Mohamed *et al.*, 2013). Prior to the initial surgery, this patient had undergone a MEG study for research purposes in the department of psychology. This research data was retrieved and analysed again, this time for clinical purposes. Findings showed a cluster of sources over the right fronto-operculo-insular region (*figure 2A*). The patient underwent a second epilepsy surgery with the removal of the right frontal operculum, the anterior insula, and the postero-lateral orbito-frontal cortex (*figure 2C*). He has remained seizure-free since (Engel Class 1A, with a follow-up of five years). No change in subjective emotional experience was reported by the patient following the surgeries, and formal neuropsychological assessment revealed no deterioration (nor improvement) of pre-existing impairments in attention and executive functions. No personality changes were reported on the Iowa Scales of Personality Change (Barrash *et al.*, 1997) according to the spouse, although elevations were noted on items assessing lack of stamina and initiative, vulnerability to pressure, lack of planning, and social inappropriateness both before and after surgery. However, the patient himself reported a loss of motivation and lack of stamina (*e.g.* difficulty initiating or completing projects) and was declared unfit for work in this context.

Discussion

We report on a patient with drug-resistant epilepsy who exhibited a peculiar aura of embarrassment who eventually became seizure-free following the removal of the right frontal-operculum at the junction of the anterior insula and the postero-lateral orbitofrontal cortex.

These findings are consistent with our current understanding of the neural correlates underlying negative moral emotions such as shame, embarrassment, and guilt. While shame is a self-focused feeling related to the way we perceive ourselves and how we believe others see us after a wrong or foolish behaviour, guilt implies empathy toward others and a real concern for the other’s wellbeing with a need to make amends after acting badly. On the other hand, embarrassment is more related to a response in the presence of a real or imagined audience in which the person worries about their social image (Bastin *et al.*, 2016). Functional neuroimaging (MRI or PET) studies have shown both shared and distinct patterns of activation associated with these emotions. Regions that are commonly activated in more than one self-blaming emotion typically include the hippocampus, the dorso-medial prefrontal cortex, the ventrolateral prefrontal cortex, the dorsal anterior cingulate cortex, and the anterior insula (Bastin *et al.*, 2016). Cumulative work

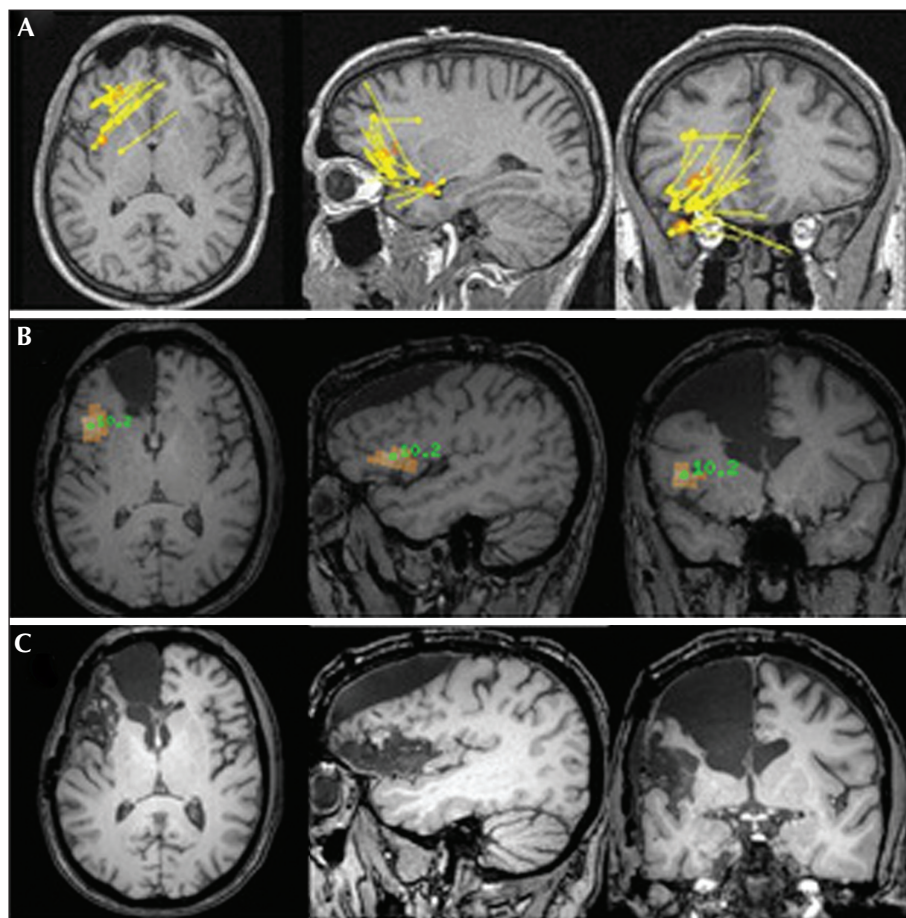


Figure 2. (A) Magnetoencephalography study (acquired prior to first surgery but analysed only after) showing clustered sources using the equivalent current dipole model over the anterior insula, posterior orbitofrontal cortex, and frontal operculum. (B) Magnetoencephalography study (performed after the first surgery) showing probable source of high-frequency gamma oscillations in the anterior insula using the Beamformer model. (C) MRI showing the location and extent of the first surgery over the anterior frontal region (arrow) and the second surgery at the junction of the frontal operculum, anterior insula, and posterior orbitofrontal cortex (triangle).

over recent years has notably shown that the insula plays a particularly important role in interoception and the representation of emotional states, especially in relation to processing subjective feelings, empathy, and uncertainty (Uddin *et al.*, 2017). Moreover, tractography studies have shown strong connections between the anterior insula and all the aforementioned structures from the ventral to the dorsal sectors of the prefrontal cortex (Ghaziri *et al.*, 2017).

To our knowledge, only one similar case has been reported in the literature (Devinsky *et al.*, 1982); a 40-year-old patient with an aura of embarrassment (“as though [he] had made a very foolish remark”), associated with a Grade II astrocytoma in the right anterior medial frontal region. The location of the tumour (and probable seizure onset zone) here is also consistent with our current knowledge of the circuitry of these emotions, although one cannot exclude that the aura

is the result of propagation of ictal activity to other brain regions.

In contrast to the unpleasant nature of the emotional state reported by our patient during his seizures, extremely positive emotions (*i.e.* “ecstatic seizures”) have also been associated with seizures involving the anterior insula in some patients (Gschwind and Picard, 2016). A possible explanation for such contrasting emotional experiences associated with epileptic seizures originating from similar regions is a hemispheric specialization in emotional valence processing. Indeed, stimuli with negative emotional valence have been associated with bilateral insular activation in fMRI studies, whereas positive stimuli more specifically activate the left insula (Duerden *et al.*, 2013). However, ecstatic seizures are not specific to the left hemisphere as they have been located in both hemispheres (Gschwind and Picard, 2016). It also seems unlikely

that such complex emotional states are specifically located in a single brain region. Another possibility is that these different emotional experiences during seizures involve distinct epileptic networks, both involving the insular cortex. Based on the present case study of embarrassing seizures and the few cases of ecstatic seizures previously reported in the literature (Picard and Craig, 2009; Gschwind and Picard, 2016), it can be hypothesized that the former involve, among other regions, the insula and the anterior medial frontal cortex, whereas the latter involve the anterior temporal lobe in addition to the anterior insula.

It is interesting to note the change in seizure semiology following the first epilepsy surgery (transition to sleep-related seizures only and disappearance of the aura of embarrassment). This may be related to a surgical alteration of the fronto-insular network underlying both this negative moral emotion and epileptic condition, or simply the inability to recall the aura during sleep. On the other hand, we cannot exclude the possibility that the auras of embarrassment were the result of seizure propagation to the polar sections of the prefrontal cortex (Moll *et al.*, 2011). It is unlikely that the patient had multifocal epilepsy as the MEG performed before the first surgery (but only analysed after) suggested a focus at the junction of the anterior insula, inferior frontal gyrus, and postero-lateral orbitofrontal cortex, similar to the post-operative MEG. Our case study is limited by the fact that confident and precise delineation of the seizure onset zone within these structures was not possible by intracranial EEG due to inadequate sampling, notably of the insula and the postero-lateral portion of the orbitofrontal cortex. This serves as a reminder that inadequate intracranial electrode coverage may produce a false electrographic picture as the first signal recorded may simply represent propagation if there is no electrode over the actual seizure onset zone. Furthermore, this case is another example of how MEG can be useful in the presurgical evaluation of non-lesional drug-resistant neocortical epilepsies including operculo-insular cases (Mohamed *et al.*, 2013, 2018).

Conclusion

Our case study suggests that ictal embarrassment may be encountered in epileptic patients with a focus at the junction of the frontal operculum, anterior insula, and postero-lateral orbitofrontal cortex. When dealing with such an aura, one should keep in mind known components of the network underlying these negative moral emotions. □

Supplementary data.

Summary didactic slides are available on the www.epilepticdisorders.com website.

Acknowledgements and disclosures.

We thank Tamara Fortin, Manon Robert, Antoine Dionne and Eli Bou Assi for their assistance. I would especially like to thank Professor Nguyen for welcoming me to his laboratory during the summer of 2018, thank you for everything!

None of the authors have any conflict of interest to declare.

References

- Barrash J, Anderson SW, Hathaway-Neple J, *et al.* *The Iowa scales of personality change*. University of Iowa College of Medicine DoN. Iowa City, 1997.
- Bastin C, Harrison BJ, Davey CG, Moll J, Whittle S. Feelings of shame, embarrassment and guilt and their neural correlates: a systematic review. *Neurosci Biobehav Rev* 2016; 71: 455-71.
- Delis DC, Kaplan E, Kramer JH. *Delis-Kaplan Executive Function system: technical manual*. Psychological Corporation, 2001.
- Devinsky O, Hafler DA, Victor J. Embarrassment as the aura of a complex partial seizure. *Neurology* 1982; 32: 1284-5.
- Duerden EG, Arsalidou M, Lee M, Taylor MJ. Lateralization of affective processing in the insula. *Neuroimage* 2013; 78: 159-75.
- Ghaziri J, Tucholka A, Girard G, *et al.* The corticocortical structural connectivity of the human insula. *Cereb Cortex* 2017; 27: 1216-28.
- Gschwind M, Picard F. Ecstatic epileptic seizures: a glimpse into the multiple roles of the insula. *Front Behav Neurosci* 2016; 10: 21.
- Mohamed IS, Otsubo H, Ferrari P, *et al.* Source localization of interictal spike-locked neuromagnetic oscillations in pediatric neocortical epilepsy. *Clin Neurophysiol* 2013; 124: 1517-27.
- Mohamed IS, Bouthillier A, Berube A, *et al.* The clinical impact of integration of magnetoencephalography in the presurgical workup for refractory nonlesional epilepsy. *Epilepsy Behav* 2018; 79: 34-41.
- Moll J, Zahn R, De Oliveira-Souza R, *et al.* Impairment of prosocial sentiments is associated with frontopolar and septal damage in frontotemporal dementia. *Neuroimage* 2011; 54: 1735-42.
- Picard F, Craig AD. Ecstatic epileptic seizures: a potential window on the neural basis for human self-awareness. *Epilepsy Behav* 2009; 16: 539-46.
- Ruff RM, Allen CC. *Ruff 2 & 7 Selective attention test: professional manual*. Psychological Assessment Resources, 1996.
- Uddin LQ, Nomi JS, Hebert-Seropian B, Ghaziri J, Boucher O. Structure and function of the human insula. *J Clin Neurophysiol* 2017; 34: 300-6.

TEST YOURSELF



- (1) What is the difference between guilt, shame and embarrassment?
- (2) What brain regions are commonly involved in embarrassment, shame and guilt?
- (3) What are the limitations of intracranial EEG studies?

Note: Reading the manuscript provides an answer to all questions. Correct answers may be accessed on the website, www.epilepticdisorders.com, under the section "The EpiCentre".