

Epileptiform abnormalities in the disconnected hemisphere are common in seizure-free patients after hemispherectomy

Majed Alzahrany^{1,2}, Rawyah Alnakhli^{1,3}, William Bingaman¹, Elaine Wyllie¹, Ahsan N. Moosa¹

¹ The Charles Shor Epilepsy Center, Neurological Institute, Cleveland Clinic, Cleveland, Ohio, USA

² King Abdulaziz University, Division of Neurology, Department of Medicine, Jeddah, Saudi Arabia

³ Dr. Sulaiman Al Habib Hospital, Division of Neurology, Riyadh, Saudi Arabia

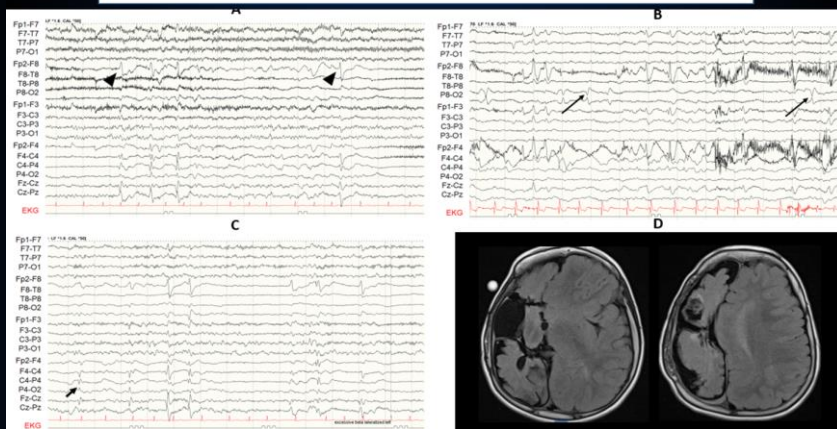
Purpose of the Study

- Hemispherectomy is a common and effective pediatric epilepsy surgery.
- Two-thirds of children become seizure-free after various forms of hemispheric disconnection.
- EEGs are routinely performed on follow-up to decide on weaning off ASM after surgery.
- The spectrum of EEG abnormalities in the disconnected hemisphere in seizure-free patients after hemispherectomy has not been well characterized.
- Using 50 consecutive patients who were seizure-free after various forms of hemispheric disconnection, we describe the EEG findings after hemispheric disconnection.

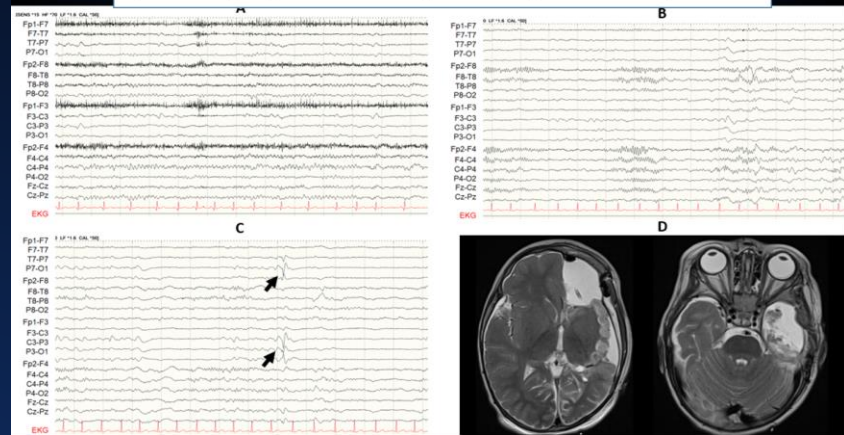
Results: Post-operative EEG findings in 50 Patients

Finding	Frequency of abnormality
Slowing & attenuation of physiological rhythms in the operated hemisphere	100%
Epileptiform discharges in the operated hemisphere -40	80%
No epileptiform discharges on either side -9	18%
Epileptiform discharges exclusively in the un-operated hemisphere - 1	2%
Bilateral independent epileptiform discharges - 6	12%
Lateralized periodic discharges in the operated hemisphere - 3	6%
EEG seizures on the side of surgery without spread to the other hemisphere and without clinical signs- 4	8%

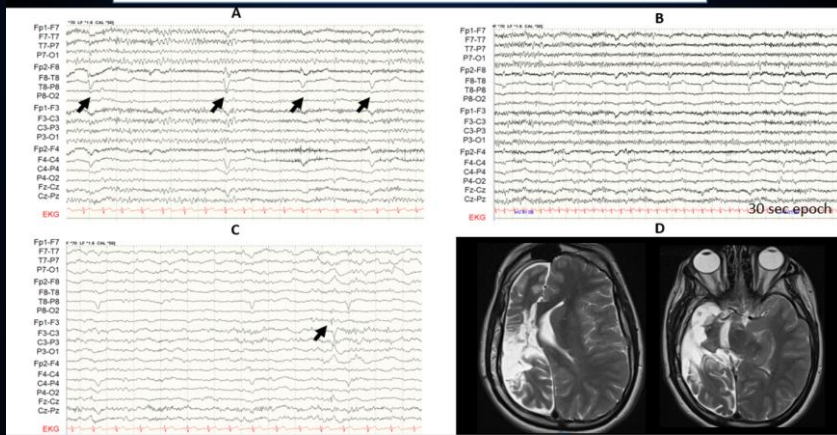
Repetitive Epileptiform discharges in the operated hemisphere



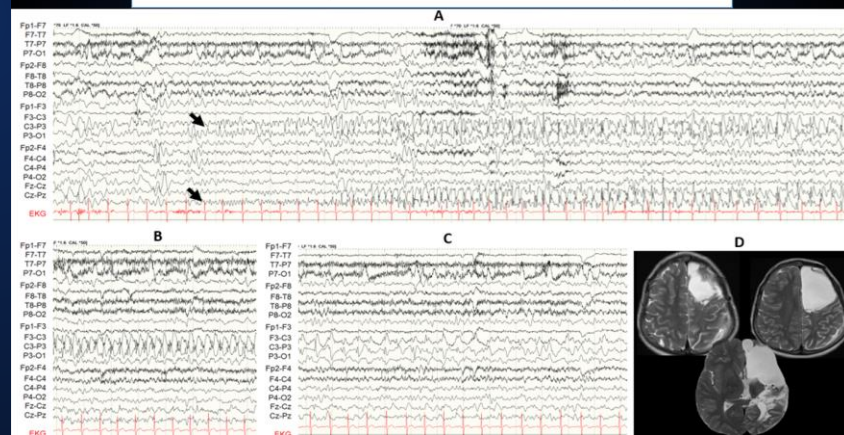
Sporadic Epileptiform discharges in the operated hemisphere



Lateralized periodic discharges in the operated hemisphere



EEG seizures on Operated Side without Clinical Signs



Key Points

- The majority of patients (80%) who are seizure-free after disconnective hemispherectomy continued to show epileptiform discharges in the operated hemisphere.
- EEG seizures in the operated hemisphere were noted in 8% of seizure-free patients, with no clinical signs.
- The disconnected hemisphere may continue to show epileptiform discharges but does not cause clinical seizures after effective hemispheric disconnection.
- Epileptiform abnormalities on EEG on the operated side should not preclude tapering, nor prompt restarting of antiseizure medication in seizure-free patients.