

# Fall related to epileptic seizures in the elderly

Vi-Huong Nguyen-Michel<sup>1</sup>, Anne Bornand<sup>2</sup>,  
Aroquia-Marie-Edith Balathazar<sup>2</sup>, Kiyoka Kinugawa<sup>1,3,4</sup>,  
Xuân-Yên Lâm<sup>5</sup>, François Piette<sup>2,3</sup>, Jean Mariani<sup>1,3,4</sup>,  
Sophie Dupont<sup>3,5</sup>

<sup>1</sup> Functional Exploration Unit for the Elderly, Clinical Neurophysiology Department; Pitié-Salpêtrière-Charles Foix University Hospital, Ivry-sur-Seine

<sup>2</sup> Geriatric Department, Pitié-Salpêtrière-Charles Foix University Hospital, Ivry-sur-Seine

<sup>3</sup> Sorbonne Universities, UPMC University of Paris 6, UMR 8256 B2A, Paris

<sup>4</sup> CNRS, UMR 8256 B2A, F-75005, Paris

<sup>5</sup> Department of Rehabilitation, Pitié-Salpêtrière-Charles Foix University Hospital, Paris, France

Received January 25, 2015; Accepted May 01, 2015

**ABSTRACT** – It is well known that both falls and epileptic seizures are very frequent and harmful in the elderly. Moreover, although seizures may cause falls, their relationship is poorly documented in this population. We report four women (mean age: 84.5 years) who presented falls with: late-onset focal seizures of possible parietal (Case 1) or frontal localisation (Case 2), early onset with late aggravation of juvenile myoclonic epilepsy (Case 3), and generalised situation-related myoclonic seizures (Case 4). Falls were presumably associated with tonic posturing of left (Case 1) or right (Case 2) hemibody, to bilateral and massive myoclonic jerks (Cases 3 and 4) with a loss of consciousness (Case 3). The diagnosis of seizures was difficult and routine EEG was unremarkable in Cases 1 and 2, requiring video-EEG monitoring to capture the clinical events. Adequate treatment offered recovery from seizures and falls in all patients. Other mechanisms of seizure-induced falls in older patients and their management are discussed. In conclusion, falls may be caused by different seizure types and appear to be underestimated due to difficulties in seizure diagnosis in the elderly. Recognizing falls related to seizures is important in geriatric practice, as it facilitates adequate management.

**Key words:** injury, epilepsy, EEG, antiepileptic drug, age

Falls are a major problem in the elderly and a significant source of morbidity (Tinetti *et al.*, 2006). Their aetiologies are often multiple in this population (Huang *et al.*, 2012). Thus, a good understanding of these aetiologies is crucial to plan adequate preventive actions. Although falls and injuries due to epileptic seizures have abundantly

been studied in children and young epileptic patients (Russell-Jones and Shorvon, 1989; Nakken and Lossius, 1993; Buck *et al.*, 1997; Neufeld *et al.*, 1999; Lawn *et al.*, 2004; Nguyen and Téllez Zenteno, 2009), little is known in the older population. A large cohort of epileptic patients indicated an increased risk of hip fracture with age and higher risk

**Correspondence:**

Vi-Huong Nguyen-Michel  
Unité d'Explorations Fonctionnelles  
du Sujet Agé,  
Hôpital Charles Foix,  
7 Avenue de la République,  
94000 Ivry sur Seine, France  
<vhnguyen.michel@gmail.com>

of any fracture among women aged 50 years or over (Souverein *et al.*, 2005). Convulsion/epilepsy is one of the independent predictors of a diagnosis of unintentional fall in the elderly (Guse and Porinsky, 2003). Seizure-related injuries mostly result from falls and are often attributed to generalised tonic-clonic seizures (GTCS) in younger people (Buck *et al.*, 1997, Neufeld *et al.*, 1999) or in the elderly (Lees, 2010). However, epileptic seizures may not be restricted to GTCS (Nakken and Lossius, 1993; Neufeld *et al.*, 1999), particularly in the elderly in whom focal seizures are the most prevalent type of seizure (Stephen and Brodie, 2000). During a one-year period in our EEG laboratory for the elderly, 38 four-hour video-EEG recordings were performed for 35 geriatric patients (mean age: 85.3 years; range: 74-96). Among five patients referred for falls, epileptic seizures were captured in two. We added two other cases with falls in whom epileptic seizures were recorded during standard routine EEG. In total, we report four older women (76, 78, 88 and 96 years) who exhibited falls induced by seizures and discuss their characteristics.

## Case studies

### Case 1

A 96-year-old woman suffered from cardio-vascular disease, depression and cognitive impairment. She took mianserine, furosemide, amiodarone and warfarine daily. She presented repetitive falls and loss of autonomy. Comprehensive medical assessment revealed a cardiac arrhythmia that was corrected but falls persisted. Medical interview was difficult but she finally mentioned some brief and painful sensations of tightness in her left thigh. Neurological examination showed no focal signs. Brain MRI showed a sequela of left frontal ischaemic stroke. Biological tests and routine EEG were unremarkable. Two video-EEG recordings, lasting four hours each, documented 15 paroxysmal, stereotyped attacks, consisting of a sudden flexion of the neck and the left arm, leftward head turn, left hemi-face contraction, and a painful sensation without loss of consciousness, lasting 13 seconds on average. Just before the attack, the patient sometimes violently wiggled her legs for a few seconds. Being interrogated just after the attack, she explained that these movements were due to a violent tingling sensation similar to electrical discharges in the foot spreading up into the legs. Although EEG signals exhibited only movement artifacts, these recorded events strongly suggested a focal epileptic origin from parietal spreading to frontal area. Levetiracetam was introduced progressively up to 1,000 mg/day, resulting in recovery from seizures and falls. The follow-up period was six months.

### Case 2

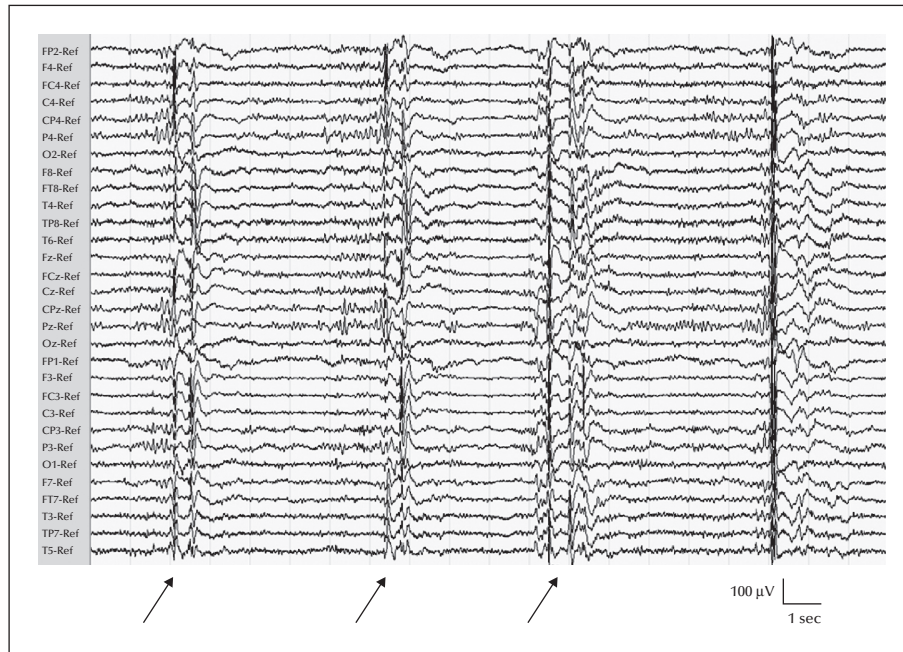
An 88-year-old woman had a history of hypertension, dyslipidaemia, breast cancer treated without relapse, left thalamo-capsular lacuna, and cognitive impairment. She took nicardipine, atorvastatine, acetylsalicylic acid, and omeprazole daily. She developed falls and loss of autonomy. Orthostatic hypotension was corrected by the withdrawal of the anti-hypertension drug. However, falls continued to occur and caused head injuries. Routine EEG and biological tests were unremarkable. Brain MRI showed a sequela of left thalamo-capsular lacuna stroke and leukoaraiosis with no recent lesion. Medical interview was difficult, but she finally complained about a "strange mania" with brief right arm contractions often spreading down into the right leg. Four-hour video-EEG monitoring sessions recorded five stereotyped attacks, lasting three seconds on average, with right arm tonic posturing, right hemiface contraction, followed by a milder contraction of the right leg, without loss of consciousness. Although EEG signals exhibited only movement artifacts, these recorded events strongly suggested a focal seizure with left frontal origin. Levetiracetam was introduced progressively up to 2,000 mg/day which stopped seizures and falls. Control video-EEG monitoring did not detect any seizures. The follow-up period was six months.

### Case 3

A 76-year-old woman suffered from epilepsy since the age of 20 and Parkinson's disease. She took phenobarbital, amantadine, and L-dopa. She experienced a long quiescent period without seizures for years and had a normal life before seizure relapse at the age of 74 and 76. The last relapse was severe, consisting of massive, bilateral, sub-continuous myoclonic jerks, with loss of consciousness and falls. During standard routine EEG, ictal recording showed sub-continuous discharges of rhythmic generalised spikes or polyspikes and waves at around 3 Hz/sec, prominent over the anterior regions, accompanying myoclonic jerks. Interictal EEG showed similar but briefer discharges on a normal background activity without focal abnormalities. Carbamazepine worsened seizures and falls. Lamotrigine exacerbated myoclonias. Finally, levetiracetam stopped seizures and falls. Early onset of juvenile myoclonic epilepsy (JME) with late aggravation was diagnosed. Other details of this case were reported previously (Nguyen-Michel *et al.*, 2009).

### Case 4

A 78-year-old woman was hospitalised due to leg ulceration. She had hypertension treated by losartan



**Figure 1.** Ictal EEG recording of Case 4 showing repetitive bilateral discharges of polyspikes (arrows) accompanying myoclonic jerks and falls (montage with average reference).

and a head trauma two years previously with a left frontal extradural haematoma which she had totally recovered from. During hospitalisation, depression was diagnosed requiring antidepressant drug treatment (citalopram at 20 mg/day). On the fifth day of this treatment, she developed repetitive bilateral massive myoclonic jerks affecting the limbs without loss of consciousness, making it impossible for her to keep any object in her hands and causing her to fall when standing. Neurological examination and cerebral CT were unremarkable. Biological testing showed mild hypokalaemia with normal renal function. Standard routine EEG showed repetitive bilateral discharges of polyspikes accompanying myoclonic jerks, confirming the diagnosis of a generalised myoclonic status (*figure 1*). Citalopram was suspected to be the precipitating factor and was stopped. One dose of 500 mg of levetiracetam was given which stopped myoclonic jerks three hours later. Control routine and 24-hour EEG were normal. The patient could walk normally again. Seizures did not relapse without any further antiepileptic drug (AED) treatment. The follow-up period was six months.

## Discussion

Elderly patients presented falls related to late-onset focal seizures of possible parietal (Case 1) or frontal localisation (Case 2), early onset with late aggrava-

tion of JME (Case 3), and generalised situation-related myoclonic seizures (Case 4). The medical history was difficult to reconstitute in these elderly patients living alone and presenting cognitive impairment. An accurate description of subjective symptoms was obtained from interrogation immediately following attacks. Because of the multiple co-morbidities, other causes of falls may have masked the diagnosis of seizure (Cases 1 and 2) (Ali *et al.*, 2007). The aetiologies of seizures may be variable in these patients: vascular and degenerative disorders (Cases 1 and 2), precipitating factors such as anti-depressant use (Case 4), or idiopathic epilepsy (Case 3). Routine EEG, although with 30 electrodes, was not useful in Cases 1 and 2 that required video-EEG monitoring to capture clinical events. Adequate treatment offered recovery from both seizures and falls in all patients.

As mentioned above, there are very few studies that are devoted to seizure-related falls in older people. Yet, epileptic seizures are most prevalent in later life (Stephen and Brodie, 2000) and falls constitute a leading cause of injuries among the elderly (Huang *et al.*, 2012). Moreover, it is not clear which seizure types may provoke falls and how this occurs in this population. Due to a sudden combination of total loss of consciousness and violent and diffuse tonic-clonic motor symptoms, GTCS will systemically cause fall when the patient is standing. However, other seizure types may also cause falls in the elderly (Ali *et al.*, 2007; Lees, 2010; our present cases). The mechanisms

causing falls in the patients reported here include: presumably tonic posturing of hemibody (focal parietal or frontal seizures; Cases 1 and 2), bilateral and massive myoclonic jerks (generalised myoclonic seizures; Cases 3 and 4), and loss of consciousness (Case 3). These paroxysmal motor symptoms may provoke a sudden shift in the centre of gravity when affecting the upper trunk, a flexion or extension of the legs, and loss of balance and falls ensue. Impairment of consciousness may provoke falls due to a poor interaction of the patient with the environment and a loss of spatial orientation, in particular when the patients are walking in an unsafe place. As both falls and seizures are frequent in the elderly, we may wonder whether they simply co-existed in our patients. However, other possible causes of falls were evaluated, yet the falls stopped only once seizures were successfully controlled, suggesting a causal relationship. Simple focal seizures are often not associated with injuries (Nakken and Lossius, 1993; Neufeld et al., 1999). However, pre-existing impairment of mobility, poor balance, and poor protective reflexes may facilitate falls in the elderly even during simple focal seizures. Of note, our Case 2 presented falls with head injuries although she had only brief and simple focal seizures without GTCS.

Seizures of temporal origin with autonomic symptoms and falls were reported in older individuals (Ghearing et al., 2007). Autonomic symptoms may induce falls due to severe ictal bradycardia or vasoplegia via the mechanism of cerebral hypoperfusion.

When seizures are the cause of falls, adequate treatment of seizures is the most effective prevention of falls. In Cases 1, 2 and 3 with true epilepsy, AEDs were required and led to a clear improvement of seizures and falls (Ali et al., 2007). In some cases, the use of inadequate AEDs may worsen seizures in persistent idiopathic generalized epilepsy, and lamotrigine may aggravate myoclonia (Case 3). Careful history-taking of seizures and the presence of typical generalised EEG abnormalities lead to diagnosis (Nguyen-Michel et al., 2009). In the case of situation-related seizures (Thomas et al., 1992) (Case 4), long-term AEDs are not required, but elimination of the precipitating factor is required to stop seizures and falls.

Side effects of AEDs may potentially cause falls (Huang et al., 2012) and must be strictly supervised. Osteoporosis should be prevented since AED users are exposed to a higher risk of osteoporosis, fall, and fracture (Shiek Ahmad et al., 2012).

In conclusion, not only GTCS but also other seizure types may be responsible for falls in the elderly. Recognizing falls related to seizures is important in geriatric practice, as it facilitates adequate

management. Further studies in large cohorts are needed to better characterize all seizure types that cause falls in the elderly.

#### Supplementary data.

Summary didactic slides are available on the [www.epilepticdisorders.com](http://www.epilepticdisorders.com) website.

#### Acknowledgements and disclosures.

We would like to thank Geraldine Vine for her contribution to the correction of the English language.

None of the authors have any conflict of interest to disclose.

#### References

- Ali A, Christian D, Chung E. Funny turns in an elderly man. *West Indian Med J* 2007;56(4):376-9.
- Buck D, Baker GA, Jacoby A, Smith DF, Chadwick DW. Patients' experiences of injury as a result of epilepsy. *Epilepsia* 1997;38(4):439-44.
- Ghearing GR, Munger TM, Jaffe AS, Benarroch EE, Britton JW. Clinical cues for detecting ictal asystole. *Clin Auton Res* 2007;17(4):221-6.
- Guse CE, Porinsky R. Risk factors associated with hospitalization for unintentional falls: Wisconsin hospital discharge data for patients aged 65 and over. *WMJ* 2003;102(4):37-42.
- Huang AR, Mallet L, Rochefort CM, Egualé T, Buckeridge DL, Tamblyn R. Medication-related falls in the elderly: causative factors and preventive strategies. *Drugs Aging* 2012;29(5):359-76.
- Lawn ND, Bamlet WR, Radhakrishnan K, O'Brien PC, So EL. Injuries due to seizures in persons with epilepsy: a population-based study. *Neurology* 2004;63(9):1565-70.
- Lees A. Retrospective study of seizure-related injuries in older people: a 10-year observation. *Epilepsy Behav* 2010;19(3):441-4.
- Nakken KO, Lossius R. Seizure-related injuries in multihandicapped patients with therapy-resistant epilepsy. *Epilepsia* 1993;34(5):836-40.
- Neufeld MY, Vishne T, Chistik V, Korczyn AD. Life-long history of injuries related to seizures. *Epilepsy Res* 1999;34(2-3):123-7.
- Nguyen R, Téllez Zenteno JF. Injuries in epilepsy: a review of its prevalence, risk factors, type of injuries and prevention. *Neurol Int* 2009;1(1):e20.
- Nguyen-Michel VH, Ourabah Z, Sebban C, Lavallard-Rousseau MC, Adam C. Idiopathic generalised epilepsies in the elderly: the viewpoint of a geriatrician. *Rev Neurol* 2009;165(11):924-32.
- Russell-Jones DL, Shorvon SD. The frequency and consequences of head injury in epileptic seizures. *J Neurol Neurosurg Psychiatry* 1989;52(5):659-62.

Shiek Ahmad B, Hill KD, O'Brien TJ, Gorelik A, Habib N, Wark JD. Falls and fractures in patients chronically treated with antiepileptic drugs. *Neurology* 2012;79(2): 145-51.

Souverein PC, Webb DJ, Petri H, Weil J, Van Staa TP, Egberts T. Incidence of fractures among epilepsy patients: a population-based retrospective cohort study in the General Practice Research Database. *Epilepsia* 2005;46(2): 304-10.

Stephen LJ, Brodie MJ. Epilepsy in elderly people. *Lancet* 2000;355(9213):1441-6.

Thomas P, Beaumanoir A, Genton P, Dolisi C, Chatel M. 'De novo' absence status of late onset: report of 11 cases. *Neurology* 1992;42(1):104-10.

Tinetti ME, Gordon C, Sogolow E, Lapin P, Bradley EH. Fall-risk evaluation and management: challenges in adopting geriatric care practices. *Gerontologist* 2006;46(6):717-25.

## TEST YOURSELF



- (1) How prevalent are falls and epileptic seizures in the elderly?
- (2) Which seizure types can cause falls in the elderly?
- (3) By which mechanisms can epileptic seizures provoke falls?

*Note: Reading the manuscript provides an answer to all questions. Correct answers may be accessed on the website, [www.epilepticdisorders.com](http://www.epilepticdisorders.com), under the section "The EpiCentre".*