

# Focal motor seizure with automatisms in a newborn

Marilena Vecchi<sup>1</sup>, Agnese Suppiej<sup>1</sup>, Massimo Mastrangelo<sup>2</sup>,  
Clementina Boniver<sup>1</sup>

<sup>1</sup> Clinical Neurophysiology, Department of Pediatrics, Padova

<sup>2</sup> Pediatric Neurology, V.Buzzi Hospital, ICP, Milan, Italy

Received November 24, 2006; Accepted February 7, 2007

**ABSTRACT** – Continuous synchronized video-EEG-polygraphic recordings allow us to better define the electroclinical patterns of epileptic events and to study the semiological features of neonatal seizures. Recently, complex behaviours and motor automatisms in newborns have been reported as being epileptic in nature. However, the debate on physiopathology (cortical or brainstem release phenomena) is ongoing. We present the synchronized video-EEG documentation of epileptic complex motor behaviours in a newborn male. Our case contributes to the discussion regarding the semiological classification of the neonatal seizures. *[Published with video sequences]*

**Key words:** newborn, temporal seizure, classification, neonatal seizures, focal seizures

Current classifications of neonatal seizures are based on clinical criteria and their relationship with EEG activity (Volpe 2001, Mizrahi and Watanabe 2005). Clinical manifestations such as complex behaviours and motor automatisms are frequently seen in healthy newborns and in preterm infants and their possible epileptic origin has been proposed (Mastrangelo 2006).

The synchronized video-EEG-polygraphic recordings allow the clinicians to confirm the epileptic origin of the neonatal seizures with important therapeutic and prognostic implications. They also offer the possibility of studying the features of epileptic seizures in newborns and to compare ictal semiology with that of older children. It is generally agreed that clinical manifestations of neonatal seizures are different from those in older children because of brain immaturity (Scher 2006).

We report the synchronized video-EEG documentation of epileptic complex behaviours in a newborn male as a contribution to the semiological classification of neonatal seizures.

## Case report

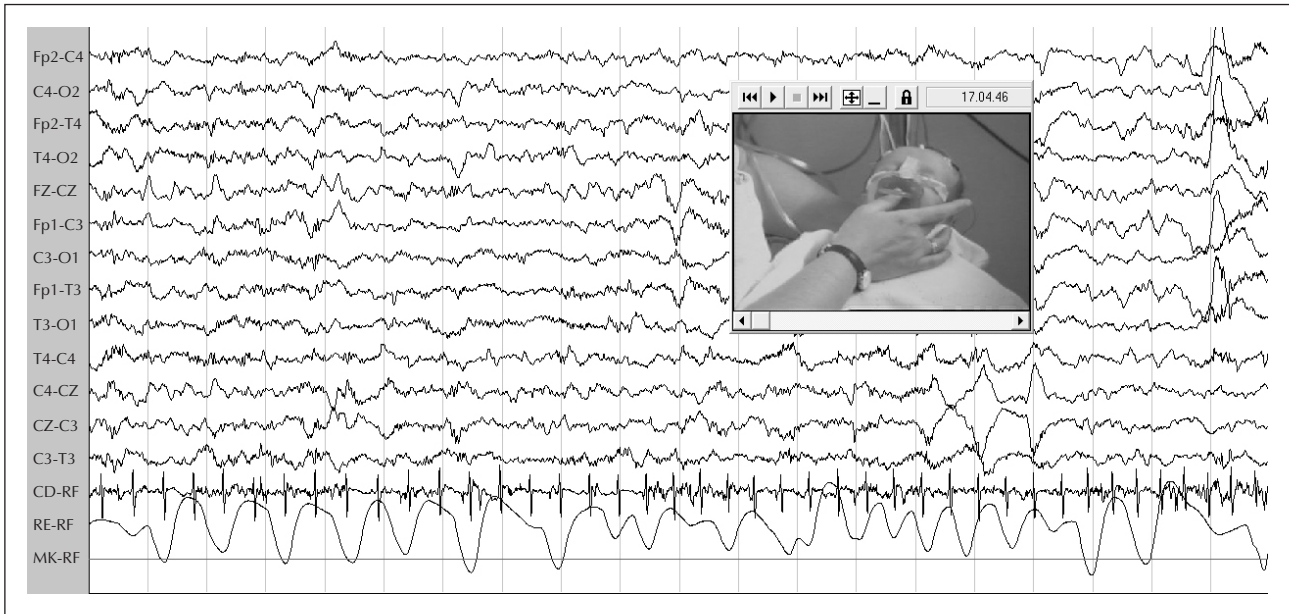M.D. was born by Caesarian section because of gestosis, after 35 weeks gestation and a normal pregnancy. The Apgar score was 9-10-10; weight at birth was 3280 grams (95%); length 50 cm (90-95%); cranial circumference 35 cm (> 95%).

In the first hours of life, polydispnoea and oxygen dependency were encountered. Chest X-rays showed 3<sup>rd</sup> degree jaline disease. He was intubated and surfactant therapy was started. While intubated, an infusion of midazolam (MDZ) (0.01 mg/kg/h) was administered and continued until

## Correspondence:

M. Vecchi  
Clinical Neurophysiology,  
Department of Pediatrics,  
Azienda Ospedaliera Padova,  
Via Giustiniani 2,  
35100 Padova,  
Italy  
Tel.: (+00 39) 049 821 8002  
Fax: (+00 39) 049 821 3502  
<vecchim@libero.it>

doi: 10.1684/epd.2007.0094

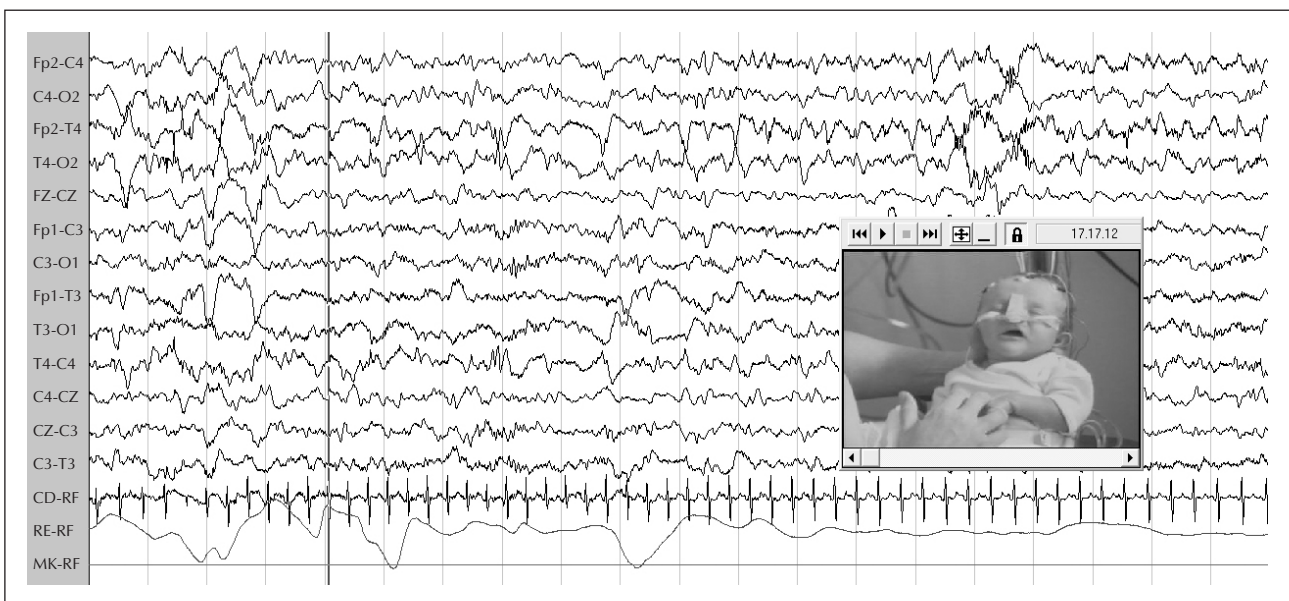


**Figure 1.** Interictal EEG: normal background activity in sleep state.

the 6<sup>th</sup> day. On the 7<sup>th</sup> day feeding difficulties arose and there were episodes of desaturation linked to bradycardia. A cardiological examination (ECG, bidimensional echocardiography) was performed with negative results. Episodes of desaturation persisted.

A synchronized video-EEG-polygraphic recording revealed epileptic seizures characterized by behavioural arrest, staring with probable impairment of consciousness, breathing irregularities followed by apnoea (desaturation

until 42% O<sub>2</sub>), deviation of the head and the eyes to the right, dystonic posture of the left hand and finally bilateral, automatic hand movements. Between one seizure and the next only sporadic slow waves were seen in right temporal region (*figure 1*). The ictal EEG pattern was initially characterized by rapid rhythms of low voltage in the right temporal region followed by theta rhythmic activity and rhythmical sharp and wave complexes in the same lobe (*figure 2*). Lorazepam and phenytoin were administered



**Figure 2.** Ictal EEG: before clinical onset of the seizure, rapid rhythms of low voltage are present in the right temporal region.

without result; however, complete control over the critical episodes was achieved with the introduction of phenobarbital. The metabolic and infectious work-up was negative. The cerebral MRIs performed at 15 days and then at 6 months of life were normal. At the age of six months, the EEG showed normal electrical activity for age; phenobarbital was stopped at four months. At the final follow-up at 12 months, he continued to show normal psychomotor development, and neurological examination was consistently normal.

## Discussion

The clinical manifestations of neonatal seizures are thought to be different from those in older children with relation to brain immaturity. Some authors think that the neonatal seizures should be classified separately from the traditional classification of seizures and epilepsy during infancy and childhood.

The classification proposed by Volpe recognises four types of ictal manifestations: subtle, clonic, tonic and myoclonic seizures. Subtle seizures, characterised by repetitive movements with autonomic signs, are the most frequent category of neonatal seizures (Scher 2002).

In order to define the functional semiological expression of neonatal seizures, the role of synchronized video-EEG-polygraphic recordings was reaffirmed by Mizrahi in 1987 when he studied clinical seizures and their relationship to ictal EEG pattern in 71 infants (Mizrahi and Kellaway, 1987).

In the recent clinical characterization of neonatal seizures, it is affirmed that the presumed pathophysiology of complex purposeless movements and motor automatisms is non-epileptic (Mizrahi and Watanabe 2005). However, the debate on the physiopathology (cortical or brainstem release phenomena) remains ongoing (Zupanc 2004).

In our case, the epileptic origin is suggested by the clinical observation of the ictal manifestations. In particular, the features and the stereotypy of the semiology suggest the anatomo-electro-clinical evolution of the seizures within the temporal lobe. The synchronized video-EEG-polygraphic recordings allow us to confirm the epileptic origin and hypothesis of the ictal starting point of seizures. Furthermore, variability in ictal semiology may also occur in newborns in relation to the cortical areas involved by the electrical discharge, just as in infancy, childhood and adulthood seizures. The ictal clinical signs of our patient seem to correspond to the clinical pattern of seizures arising from temporal lobe structures observed in older patients. They include behavioural arrest, staring, oroalimentary and manual automatisms, and ocular version and tonic or clonic features when the ictal discharge involves the extratemporal regions.

In considering the opportunity to adopt a common terminology to describe and classify neonatal epileptic sei-

### Legends for video sequences

**Video sequence 1.** Before seizure-onset the patient is asleep. At 17.08.39, he opens his eyes and after some seconds he stares; at 17.08.55, his nipple falls and a clear loss of contact is present; at 17.08.59 he presents deviation of the eyes to the right side and some left eye blinking. Following this, he remains in this position and presents some slow buccal-oral-lingual automatisms. The episode ends at 17.10.10 when he falls asleep.

**Video sequence 2.** Before the onset of the seizures he cries. At 17.17.10 he calms down and after that he opens his eyes (17.17.17). He stares, with deviation of the eyes to the right side. His left hand appears in dystonic posture; an irregular breathing pattern is present at this time; at 17.17.34 he begins to present bilateral manual automatisms and some repetitive oral-buccal movements. The episode seems to stop when he closes his eyes (17.18.48).

zures, it seems to be correct to define the ictal events herein reported by the Axis I terminology of the proposed new classification of ILAE 2001 [Glossary of descriptive terminology for ictal semeiology (Blume *et al.* 2001)]. Moreover, regarding the seizure type, i.e. Axis II (Engel 2001), the events described in our case should be classified as focal motor seizures with typical automatisms (temporal lobe).

Clinicians must be aware of the possible epileptic origin of complex motor behaviours of newborns. The case presented supports the view that the synchronized video-EEG-polygraphic recordings are an essential requirement in defining the semiological features of epileptic seizures in newborns and in guiding the MRI evaluation. In some cases, neonatal stereotyped seizures may point to a focal cortical dysplasia that may be found even later in the child's life (Lortie *et al.* 2002).

As recently proposed by Scher, a new multi-axis approach for newborns should be adopted for a better definition of the neonatal seizures, with therapeutic and prognostic implications (Scher 2006).

The accuracy of diagnosis, based obviously on the semiological recognition and definition of ictal events, is only the first step of a multi-dimensional approach (with respect to brain localization, maturational context and etiology) for the management of neonatal seizures.

For the definition of ictal events, we are of the opinion that, in the neonatal period also, the ictal epileptic events should be described adopting the Axis I and II terminology (Mastrangelo *et al.* 2005).

To our knowledge this is the first reported case with video documentation of epileptic complex behaviour in a newborn with characteristics found in older ages. □

## References

- Blume WT, Lüders HO, Mizrahi E, et al. Glossary of Descriptive Terminology for Ictal Semiology: Report of the ILAE Task Force on Classification and Terminology. *Epilepsia* 2001; 42: 1212-8.
- Engel J. A proposed Diagnostic Scheme for People with Epileptic Seizures and with Epilepsy: Report of the ILAE Task Force on Classification and Terminology. *Epilepsia* 2001; 42: 796-803.
- Lortie A, Plouin P, Chiron C, et al. Characteristics of epilepsy in focal cortical dysplasia in infancy. *Epilepsy Res* 2002; 51: 133-45.
- Mastrangelo M, Van Lierde A, Bray M, et al. Epileptic seizures, epilepsy and epileptic syndromes in newborns: A nosological approach to 94 new cases by the 2001 proposed diagnostic scheme for people with epileptic seizures and with epilepsy. *Seizure* 2005; 14: 304-11.
- Mastrangelo M. For the Italian League Against Epilepsy Study Group on Neonatal Seizures. In the neonatal period, focal motor seizures with typical automatisms and with hyperkinetic automatisms are epileptic events. *Epilepsia* 2006; 47(S3): 27.
- Mizrahi EM, Kellaway P. Characterization and classification of neonatal seizures. *Neurology* 1987; 37: 1837-44.
- Mizrahi EM, Watanabe K. Symptomatic neonatal seizures. In: Roger J, Bureau M, Dravet C, eds. *Epileptic syndromes in Infancy, Childhood and Adolescence (4th edn)*. John Libbey Eurotext, 2005: 17-38.
- Scher MS. Neonatal seizures classification: a fetal perspective concerning childhood epilepsy. *Epilepsy Res* 2006; 70S: S41-S57.
- Scher MS. Controversies regarding neonatal seizure recognition. *Epileptic Disord* 2002; 4: 138-58.
- Volpe JJ. Neonatal seizures. In: Volpe JJ, ed. *Neurology of the newborn*. Philadelphia, PA: WB Saunders, 2001: 175-216.
- Zupanc ML. Neonatal seizures. *Pediatr Clin N Am* 2004; 51: 961-78.