

Generalized periodic discharges with triphasic morphology: to treat or not to treat?

Fábio A. Nascimento, Patrick M. Chen, Joseph Cohen, Brandon M. Westover

Department of Neurology, Massachusetts General Hospital, Harvard Medical School, Boston, MA, USA

Received March 3, 2021; Accepted March 30, 2021

Key words: generalized periodic discharges; generalized periodic discharges with triphasic morphology; GPD; non-convulsive status epilepticus

We report an 82-year-old woman with recurring episodes of confusion, a left posterior fossa meningioma, and chronic hyponatremia due to syndrome of inappropriate antidiuretic hormone secretion (SIADH). She presented with a habitual episode of confusion. Basic laboratory workup was unremarkable except for hyponatremia (132 mEq/L sodium); head imaging was unrevealing. Continuous EEG showed 2-Hz generalized periodic discharges (GPDs) with triphasic morphology, or “triphasic waves” (figure 1A). Her EEG and mental status improved following 1 mg of lorazepam suggesting non-convulsive status epilepticus (NCSE).

Although traditionally associated with toxic metabolic infectious encephalopathies, GPDs with triphasic morphology may be associated with NCSE. Select patients should therefore undergo a trial with antiseizure medication to assess for electroclinical improvement [1, 2]. Importantly, electrographic improvement alone does not imply a diagnosis of NCSE [3]. ■

Supplementary data.

Summary didactic slides are available on the www.epilepticdisorders.com website.

Disclosures.

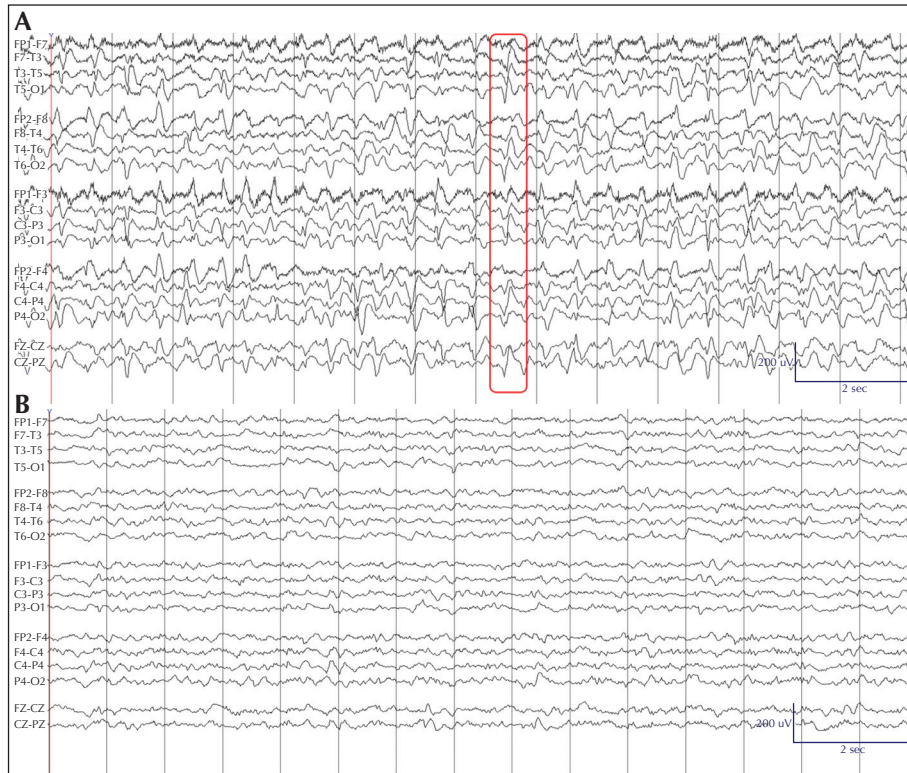
F. Nascimento is a member of the Epileptic Disorders Editorial Board. P. Chen, J. Cohen, and B. Westover report no disclosures relevant to the manuscript.

References

1. Sully KE, Husain AH. Generalized periodic discharges: a topic review. *J Clin Neurophysiol* 2018; 35(3): 199-207.
2. O'Rourke D, Chen PM, Gaspard N, Foreman B, McClain L, Karakis I. Response rates to anticonvulsant trials in patients with triphasic-wave EEG patterns of uncertain significance. *Neurocrit Care* 2016; 24(2): 233-9.
3. Fountain NB, Waldman WA. Effects of benzodiazepines on triphasic waves: implications for nonconvulsive status epilepticus. *J Clin Neurophysiol* 2001; 18(4): 345-52.

Correspondence:

Fábio Augusto Nascimento e Silva
55 Fruit St., Wang 7th floor,
Boston, MA, USA. 02114
<nascimento.fabio.a@gmail.com>
<fnascimento@mgh.harvard.edu>



■ **Figure 1.** EEG: pre-lorazepam trial (A), and 10 minutes following the lorazepam trial (B). Sensitivity: 10 mV/mm; LF: 1 Hz; HF: 70 Hz; notch: 60 Hz; timebase: 15 mm/second. (A) Bipolar montage showing 100 mV 2 Hz generalized periodic discharges with triphasic morphology. (B) Bipolar montage showing diffuse irregular 50 mV delta slowing of the background, excessive beta frequency activity, and resolution of generalized periodic discharges.

TEST YOURSELF

- (1) Can generalized periodic discharges (GPDs) with triphasic morphology, or “triphasic waves”, be associated with non-convulsive status epilepticus.
 - A. True
 - B. False

- (2) You elect to proceed with a benzodiazepine trial in a patient with generalized periodic discharges (GPDs) with triphasic morphology, or “triphasic waves”. These discharges are abolished, but the patient shows no clinical improvement. Is this scenario consistent with non-convulsive status epilepticus?
 - A. Yes
 - B. No

Note: Reading the manuscript provides an answer to all questions. Correct answers may be accessed on the website, www.epilepticdisorders.com, under the section “The EpiCentre”.