

Ictal vocalizations are relatively common in myoclonic-atonic seizures associated with Doose syndrome: an audio-video-polygraphic analysis

Hirokazu Oguni^{1,2}, Yoshiko Hirano³, Susumu Ito¹, Aiko Nishikawa¹, Yui Otani¹, Satoru Nagata¹

¹ Department of Pediatrics, Tokyo Women's Medical University, Tokyo 162, Japan

² Epilepsy Center, TMG Asaka Medical Center, 1340-1 Mizonuma, Asaka-city, Saitama 351-0023, Japan

³ Yotsugi Medical Center for the Severely Disabled, 4-44-1-101 Higashiyotsugi, Katsushika-Ku, Tokyo 124-0024, Japan

Received October 22, 2020;

Accepted March 18, 2021

ABSTRACT

Objective. The aim of this study was to investigate ictal vocalizations associated with myoclonic (MS) and myoclonic-atonic seizures (MAS) in patients with myoclonic epilepsy in infants (MEI) and epilepsy with myoclonic-atonic seizures (EMAS, Doose syndrome), respectively.

Methods. Subjects were retrospectively recruited among patients with MEI and EMAS for whom ictal video-polygraphs were recorded between 1990 and 2019. We reviewed all MS and MAS in order to estimate how often they were associated with vocalizations, and analyze the temporal relationship between vocalizations and spike-wave complexes (SWCs) and myoclonic EMG potentials based on simultaneous examination of the polygraphs and sound signals.

Results. Ictal video-polygraphs from 15 patients with MEI (2-34 MS per patient) and 26 with EMAS (2-26 MAS per patient) were examined. Ictal vocalizations were audible in two patients with MEI (11%; 3-18 MS per patient) and nine with EMAS (35%; 2-11 MAS per patient). Sounds were always non-speech and were immediately followed by head or body dropping in the case of MAS. Detailed analysis based on simultaneous and synchronous examination of video-polygraphs and sound signals in one patient with MEI and five patients with EMAS demonstrated that the onset of the ictal vocalizations corresponded to that of the myoclonic EMG potentials and negative spike components of SWC. Comparison of the length of myoclonic EMG potentials as well as the strength of drop seizures between MAS with and without vocalizations revealed that MAS with vocalizations were associated with longer myoclonic EMG potentials and stronger drop seizures than MAS without vocalizations ($p < 0.05$), suggesting that the vocalizations result from strong contraction of axial muscles.

Significance. Ictal vocalizations due to massive motor seizure activity are a relatively common finding in MAS in Doose syndrome, which may help in the differential diagnosis of epileptic drop attacks.

• **Correspondence:**
Hirokazu Oguni
Department of Pediatrics,
Tokyo Women's Medical
University,
8-1 Kawada-cho, Shinjuku-ku,
Tokyo 162-8666, Japan
<oguni.hirokazu@twmu.ac.jp>

Key words: myoclonic-atonic seizures, ictal vocalizations, Doose syndrome, epilepsy with myoclonic-atonic seizures, myoclonic epilepsy in infants

The term “epileptic drop attacks (EDAs)” has recently been used more loosely for all seizures that result in patients who drop, but was originally synonymous with atonic seizures [1]. These are markedly brief and dramatic, not only due to the seizure itself, but also gravity, making diagnosis based on witness description difficult. Recent advances in electrophysiological devices have demonstrated that myoclonic-flexor seizures, myoclonic-atonic seizures (MAS), atonic seizures and epileptic (flexor) spasms are the main seizure types that cause EDAs [2]. Precise differentiation between these seizure types is based only on analysis of electroclinical details of drop attacks using video-polygraphic data [3]. On the other hand, ictal vocalizations have been reported to occur in patients with focal epilepsy or generalized epilepsy, the latter of which were mostly associated with generalized tonic-clonic seizures (GTCS) in the form of an initial cry [4, 5]. However, this phenomenon is rarely described in myoclonic seizures or atonic seizures [6-8]. We noted that patients with EMAS often had MAS associated with initial vocalizations during a detailed video-polygraphic study. As these semiological characteristics of MAS may help to differentiate EDA seizure types based on history-taking or even home video, we report the detailed audio-video-polygraphic analysis of MS and MAS with vocalizations, and discuss the possible underlying mechanism.

Subjects and methods

Subjects were retrospectively recruited from patients with MS and MAS who had had ictal video-polygraphs and who were diagnosed with MEI or EMAS. We reviewed all MS and MAS recorded by the video-polygraphs to identify those with vocalizations. In this study, we tentatively subclassified MAS into myoclonic-atonic drop seizures and myoclonic-flexor drop seizures based on the details of polygraphic examinations [8]. The video-polygraphs were recorded either using simultaneous split-screen video recording, Ceegraph SE (Bio-logic Systems Co, USA) or the Nihon-Cohden digital video-EEG monitoring system. EEGs were recorded using silver-silver chloride electrodes according to the international 10-20 electrode system. In the case of the Nihon-Cohden system, EEGs were sampled and stored at 512 samples/s/channel, and reformatted to the monopolar montage using the linked ears reference. The surface EMG electrodes were placed on the muscle bellies of the sternocleidomastoid, deltoid, biceps, abdominal muscles and paraspinal muscles mainly on the right side of the body.

We reviewed the medical charts of each patient for whether ictal vocalizations had been noticed in the

clinical history because the number of recorded ictal seizures were limited in most patients. We analyzed the following items:

- We estimated how often the patients with MEI and EMAS had MS and MAS associated with vocalizations, respectively, based on the medical charts and video-polygraphic examinations. In addition, we calculated the positive predictive value (PPV) of ictal vocalizations for EMAS diagnosis.
- We compared the length of myoclonic EMG potentials between MS or MAS with and without vocalizations using the FOCUS program (Nihon-Cohden) to investigate the correlation between the intensity of myoclonic attacks and the occurrence of vocalizations. The intensity of myoclonic attacks was estimated from the duration of myoclonic EMG potentials and the strength of drop seizures on the video (head drop only vs. body drop).
- We reviewed the ictal video-polygraphs of those with vocalizations using a specialized software application (Audio Studio, SONY Ltd.), in which the video-polygraph and sound signal was simultaneously displayed, in order to investigate the duration of vocalizations and temporal relationship of the vocalizations relative to the polygraphs.

Statistics

Student’s t-tests for non-paired data and the Chi-square test were used for statistical analysis; $p < 0.05$ was considered significant.

This study was conducted following approval by the Clinical Research Review Committee of the Tokyo Women’s Medical University Ethics Committee (approval number: 5229).

Results

Based on our video-EEG library, we identified ictal video-polygraphs in 15 patients with MEI and 26 with EMAS between 1990 and 2019. MS and MAS were recorded in each patient ranging from 2 to 34 (median: 6) and from 2 to 26 seizures (median: 8) per patient, respectively. Based on the medical charts, descriptions of ictal vocalizations were documented for one of the 18 patients with MEI (6%) and nine of the 26 patients with EMAS (35%). Based on the video-polygraphs, we identified ictal vocalizations in two of the 18 patients with MEI (11%; 3-18 MS per patient) and nine of the 26 patients with EMAS (35%; 2-11 MAS per patient; median: 4) (table 1). The ictal vocalizations were audible in 25 to 100% of all seizures in these patients. In two of the nine patients with EMAS associated with ictal vocalizations, the ictal vocalizations were not

▼ **Table 1.** Ictal vocalizations based on medical charts and video-polygraphs.

	<i>n</i>	Descriptions of ictal vocalizations in medical charts	Ictal vocalizations confirmed on video-polygraphs	No. of MS/MAS recorded on video-polygraphs per patient	Type of ictal vocalization
MEI	18	1 (6%)	2 (11%)	2 - 35 (median: 6)	Non-speech sounds
EMAS	26	9 (35%)	9 (35%)	2 - 26 (median: 8)	Non-speech sounds

MEI: myoclonic epilepsy in infants; EMAS: epilepsy with myoclonic-atonic seizures; MS: myoclonic seizures; MAS: myoclonic-atonic seizures.

documented in the medical charts. On the other hand, for two of the nine patients whose ictal vocalizations were described in the medical charts, these were not audible on the ictal video-polygraphs. The ictal vocalizations were always non-speech sounds and ranged from strong expiratory sounds like “Ue” to a short cry in the nine patients with EMAS, and a small inspiratory sound like “Hhu” in one of the two patients with MEI.

The PPV of ictal vocalizations for EMAS diagnosis reached 82% in this study when we only included our 41 cases in the PPV evaluation.

A comparison of the length of myoclonic EMG potentials based on the video-polygraphs of MS or MAS with vocalizations was possible in only one of the two patients with MEI and five of the nine patients with EMAS, because the FOCUS program only permitted meaningful analysis for these six patients undergoing

long-term video-polygraphic recordings with the Nihone-Cohden digital EEG machine. One patient with MEI had MS with or without vocalizations exclusively during sleep. Three of five patients with EMAS had myoclonic-atonic drop seizures and the remainder two had myoclonic-flexor drop seizures. In these six patients, 25 to 73% of the seizures were associated with ictal vocalizations of varying intensity (table 2). A comparison of the length of myoclonic EMG potentials (intensity of MS component) with that of vocalizations revealed that the former were significantly longer than the latter in five of the six patients ($p < 0.05$) (table 3), i.e., the ictal vocalizations were caused by a stronger MS component. In addition, the drop seizures were significantly stronger in MAS with ictal vocalizations than in those without vocalizations in the five patients with EMAS, i.e., 23/29 (79%) MAS with initial vocalizations, in contrast to 6/25 (24%) MAS

▼ **Table 2.** Details of six patients undergoing audio-polygraphic analysis using the FOCUS program.

Patient No	Epileptic syndrome	Age at onset of MS or MAS (months)	Age at onset of study (months)	No. of MS or MAS recorded on video-polygraphs	MS or MAS with initial vocalization	Detailed seizure type of MAS	Ictal EEG pattern
1	MEI	46	61	12	3 (25%)	Myoclonic (sleep)	GSW
1	EMAS	36	35	10	5 (50%)	Myoclonic- atonic	GSW
2	EMAS	36	30	7	3 (43%)	Myoclonic- flexor	GSW
3	EMAS	42	73	12	7 (58%)	Myoclonic- atonic	GSW
4	EMAS	50	51	15	11 (73%)	Myoclonic- flexor	GSW
5	EMAS	54	54	10	3 (30%)	Myoclonic- atonic	GSW

MAS: myoclonic- atonic seizures; GSW: generalized spike-wave.

▼ **Table 3.** Duration of vocalizations and comparison of duration of myoclonic EMG potentials between MAS (MS) with and without vocalizations.

Patient No	Epileptic syndrome	Duration of vocalizations based on the sound signal (msec.)	Duration of myoclonic EMG potentials during MS or MAS with vocalizations (msec.)	Duration of myoclonic EMG potentials during MS or MAS without vocalizations (msec.)	<i>p</i> value
1	MEI	132±56 (n=3)	208±26 (n=3)	105±49 (n=9)	0.0033
1	EMAS	291±77 (n=5)	379±61 (n=5) (3)*	196±51 (n=5) (0)*	0.0005
2	EMAS	495±76 (n=3)	100±16 (n=3) (3)	52±6 (n=4) (0)	0.0141
3	EMAS	151±53 (n=7)	111±54 (n=7) (7)	84±12 (n=5) (3)	0.1092
4	EMAS	260±98 (n=11)	210±40 (n=11) (7)	103±18 (n=4) (0)	0.000
5	EMAS	225±77 (n=3)	133±20 (n=3) (3)	60±14 (n=7) (3)	0.0063

Significance was not reached for Patient 3. *number of MAS causing body drops.

without initial vocalizations, led to body dropping ($p<0.05$) (table 3).

The duration of vocalizations ranged from 63 to 562 mseconds and was slightly longer than that of myoclonic EMG potentials in cases of myoclonic-atonic drop seizures (Case 2, 3 and 5) (table 3). The temporal relationship between the onset of vocalizations and that of other polygraphic elements with simultaneous sound signals demonstrated that the onset of vocalizations corresponded to that of myoclonic EMG potentials, including deltoid, paraspinal and abdominal muscles. The onset of vocalizations also corresponded to the negative spike component of the spike-wave complex (figures 1, 2). The end of the vocalizations varied, sometimes exceeding that of the myoclonic EMG potentials in cases of myoclonic-atonic drop seizures.

Regarding MS with vocalization in MEI, the length of vocalization was shorter than that of MAS in EMAS (table 3).

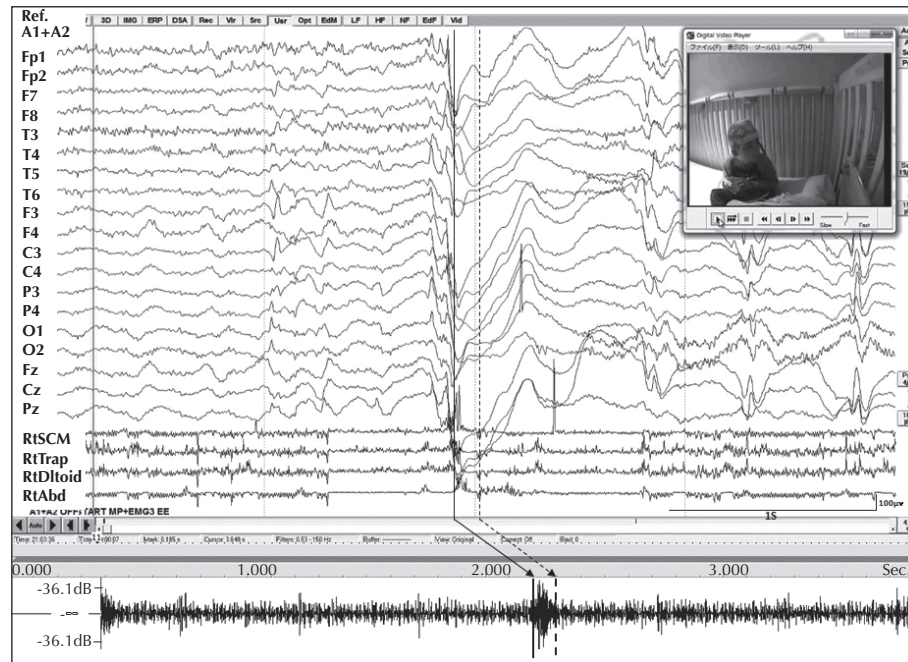
Discussion

In this study, 35% of EMAS and 11% of MEI patients had ictal vocalizations associated with MAS and MS, respectively, although these figures may have been higher with more careful evaluation. The ictal vocalizations were all non-speech sounds and associated with 25-100% of all seizures. The simultaneous display of the video-polygraph and sound signals demonstrated that the onset of the initial vocalizations largely corresponded to that of myoclonic EMG potentials and to the negative spike component of the spike-wave complex. Patients with EMAS produced initial non-

speech vocalizations which sounded like a short cry, immediately followed by dropping of the body, either due to positive (myoclonic-flexor drop seizures) or negative (myoclonic-atonic drop seizures) myoclonic EMG potentials.

Ictal vocalizations have been reported frequently in focal epilepsy syndromes, occurring in up to 40% of patients with frontal lobe seizures and in up to 48% of patients with temporal lobe epilepsy [9]. Based on the audio-video analysis of different seizures, Janszky *et al.* [4] classified ictal audible sounds (due to motor and vegetative seizure activity) into five categories, among which either pure ictal vocalizations (PIV) or sounds accompanying apnoea, clonic seizures or GTCS corresponded to the ictal vocalizations associated with MS and MAS. The simultaneous audio-polygraphic analysis of MS or MAS in this study suggested that the ictal vocalizations in these seizures were a result of sudden and strong contractions of thoracic and abdominal muscles (reflected by the myoclonic EMG potentials of the deltoid, paraspinal and abdominal muscles), after which pulmonary contractions ensue and expiratory air passes through the vocal cord, generating a vocalization. The same mechanism was previously described for an initial cry preceding GTCS [1]. Therefore, the ictal vocalizations associated with MS and MAS should be better classified as sounds due to massive motor seizure activity rather than PIV.

The duration of ictal vocalizations varied in length and was generally longer than that of myoclonic EMG potentials in cases of myoclonic-atonic drop seizures. One explanation is that the sound waves (ictal vocalizations) may more sensitively reflect the myoclonic contractions of respiratory muscles than their surface EMG activity. Alternatively, squatting due to



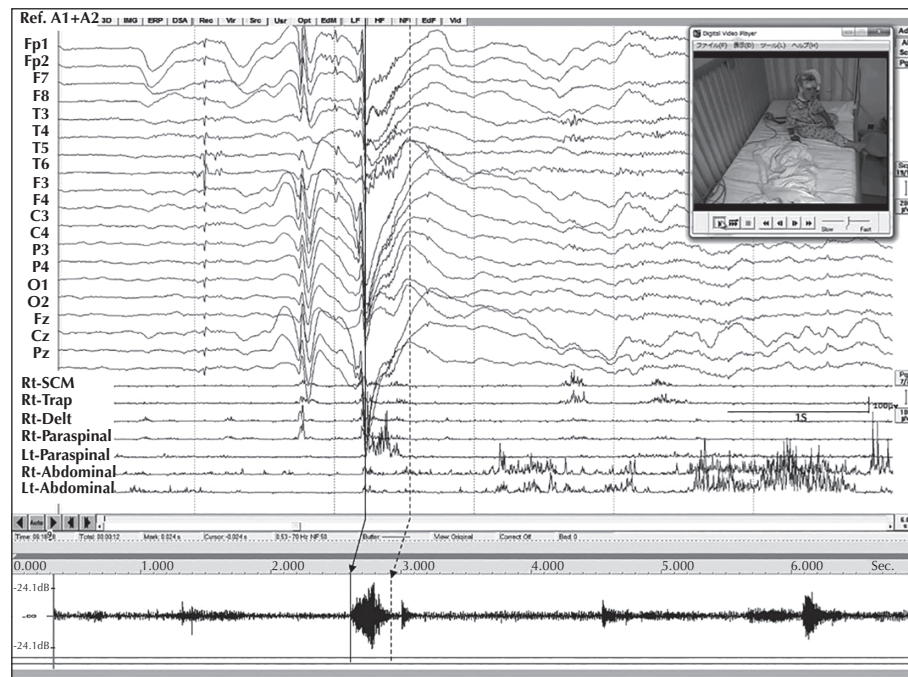
■ **Figure 1.** The simultaneous and synchronous presentation of the video-polygraph and sound signal of a myoclonic-atic seizure associated with an initial vocalization (Case 3). The onset of the sound signal representing the ictal vocalization corresponded to that of myoclonic EMG potentials, which were immediately followed by an interruption of EMG activity associated with atonic falling. The onset of the sound signal also corresponded to the negative component of the spike-wave complex. The duration of the ictal vocalization was much longer than that of myoclonic EMG potentials. The video-polygraphic and sound-track windows were time-locked with a different time scale. Vertical bars (representing onset [solid line] and end [dashed line] of vocalization) in both video-polygraph and sound-track were time-locked.

the dropping of the trunk may have further compressed the chest and abdomen, leading to the longer duration of vocalization. MAS with initial vocalizations were found to cause stronger drop seizures than those without initial vocalizations. On the other hand, MS with ictal vocalizations may be rare and weak because MS in MEI may not affect axial muscles as strongly as MAS in EMAS.

We previously evaluated MS in different epileptic syndromes, and demonstrated that MAS in EMAS involved axial and proximal muscles, causing postural change and astatic falling [10]. These findings led us to consider that MAS are relatively commonly associated with initial vocalizations because they preferentially involve deltoid, paraspinal and abdominal muscles relative to MS in MEI. As the PPV of ictal vocalizations for EMAS diagnosis reached 82% in this study, ictal vocalizations may aid in excluding MEI as a diagnosis. However, the medical charts did not always document ictal vocalizations, which were later recognized during the long-term video-polygraphic examinations. In MAS, the sudden falling may have attracted more

attention than the vocalizations. In addition, antiseizure medications may have reduced the intensity of MAS and attenuated the vocalizations during the clinical course.

The major limitation of our study was the retrospective methodology used to identify the video-polygraphs of MS and MAS which biased the selection of cases and possibly prevented reliable quantitative evaluation. The number of MS or MAS available for detailed audio-video-polygraphic analysis was small because most of these seizures in patients with MEI and EMAS were recorded on an analogue video-EEG machine and could not be utilized for precise analysis. In conclusion, EDAs associated with initial vocalizations were found to be relatively common presentations of myoclonic-atic and myoclonic flexor drop seizures in Doose syndrome. The initial myoclonic components of MAS momentarily and strongly affect the axial muscles (respiratory muscles), thereby generating brief vocalization followed by head or body dropping. These associations should be considered in the differential diagnosis of EDAs in



■ **Figure 2.** The simultaneous and synchronous presentation of the video-polygraph and sound signal of a myoclonic-flexor seizure associated with an initial vocalization (Case 4). The onset of the sound signal representing the ictal vocalization corresponded to that of myoclonic EMG potentials, whereas the end of the sound signal was slightly longer than that of the myoclonic EMG potentials. The onset of the sound signal also corresponded to the negative component of the spike-wave complex. Other details are the same as in figure 1.

childhood epilepsy and attention should be paid to accidental falls. ■

Disclosures.

None of the authors have any conflict of interest to declare.

References

1. Gastaut H, Broughton RJ. *Epileptic seizures: clinical and electrographic features, diagnosis and treatment*. Springfield IL: Charles C. Thomas; 1972.
2. Oguni H. Epileptic drop attacks. In: Panayiotopoulos CP, ed. *Atlas of epilepsies*. London: Springer-Verlag.
3. Oguni H, Fukuyama Y, Imaizumi Y, Uehara T. Video-EEG analysis of drop seizures in myoclonic atstatic epilepsy of early childhood (Doose syndrome). *Epilepsia* 1992; 33(5): 805-13.
4. Janszky J, Fogarasi A, Jokeit H, Ebner A. Are ictal vocalisations related to the lateralisation of frontal lobe epilepsy? *J Neurol Neurosurg Psychiatry* 2000; 69(2): 244-7.
5. Elzawahry H, Do CS, Lin K, Benbadis SR. The diagnostic utility of the ictal cry. *Epilepsy Behav* 2010; 18(3): 306-7.
6. Doose H. Myoclonic atstatic epilepsy of early childhood. In: Roger J, Bureau M, Dravet C, Dreifuss FE, Perret A, Wolf P, (eds). *Epileptic syndromes in infancy, childhood and adolescence*. 2nd edition, London: John Libbey.
7. Lin Y, Itomi K, Takada H, Kuboda T, Okumura A, Aso K, et al. Benign myoclonic epilepsy in infants: video-EEG features and long-term follow-up. *Neuropediatrics* 1998; 29 (5): 268-71.
8. Oguni H, Hayashi K, Imai K, Funatsuka M, Sakauchi M, Shirakawa S, et al. Idiopathic myoclonic-astatic epilepsy of early childhood—nosology based on electrophysiologic and long-term follow-up study of patients. *Adv Neurol* 2005; 95: 157-74.
9. Hartl E, Knoche T, Choupina HMP, Remi J, Vollmar C, Cunha JPS, et al. Quantitative and qualitative analysis of ictal vocalization in focal epilepsy syndromes. *Seizure* 2018; 60: 178-83.
10. Hirano Y, Oguni H, Funatsuka M, Imai K, Osawa M. Differentiation of myoclonic seizures in epileptic syndromes: a video-polygraphic study of 26 patients. *Epilepsia* 2009; 50(6): 1525-35.

TEST YOURSELF

- (1) What are the representative seizure types in Doose syndrome and myoclonic epilepsy in infants (MEI)?
- (2) How are ictal vocalizations classified and what are the causes?

Note: Reading the manuscript provides an answer to all questions. Correct answers may be accessed on the website, www.epilepticdisorders.com.
