

Clinical commentary

---

*Epileptic Disord* 2017; 19 (2): 212-16

# Intractable ictal vomiting: a new form of reflex epilepsy?

Sachin Sureshbabu<sup>1</sup>, Dinesh Nayak<sup>2</sup>, Vikash Aggarwal<sup>2</sup>,  
Sudhir Peter<sup>3</sup>, Laxmi Khanna<sup>1</sup>, Gaurav Mittal<sup>1</sup>

<sup>1</sup> St Stephen's Hospital, Tis Hazari, New Delhi - Neurology, Delhi

<sup>2</sup> Fortis Malar Hospital - Neurology, Chennai, Tamil Nadu

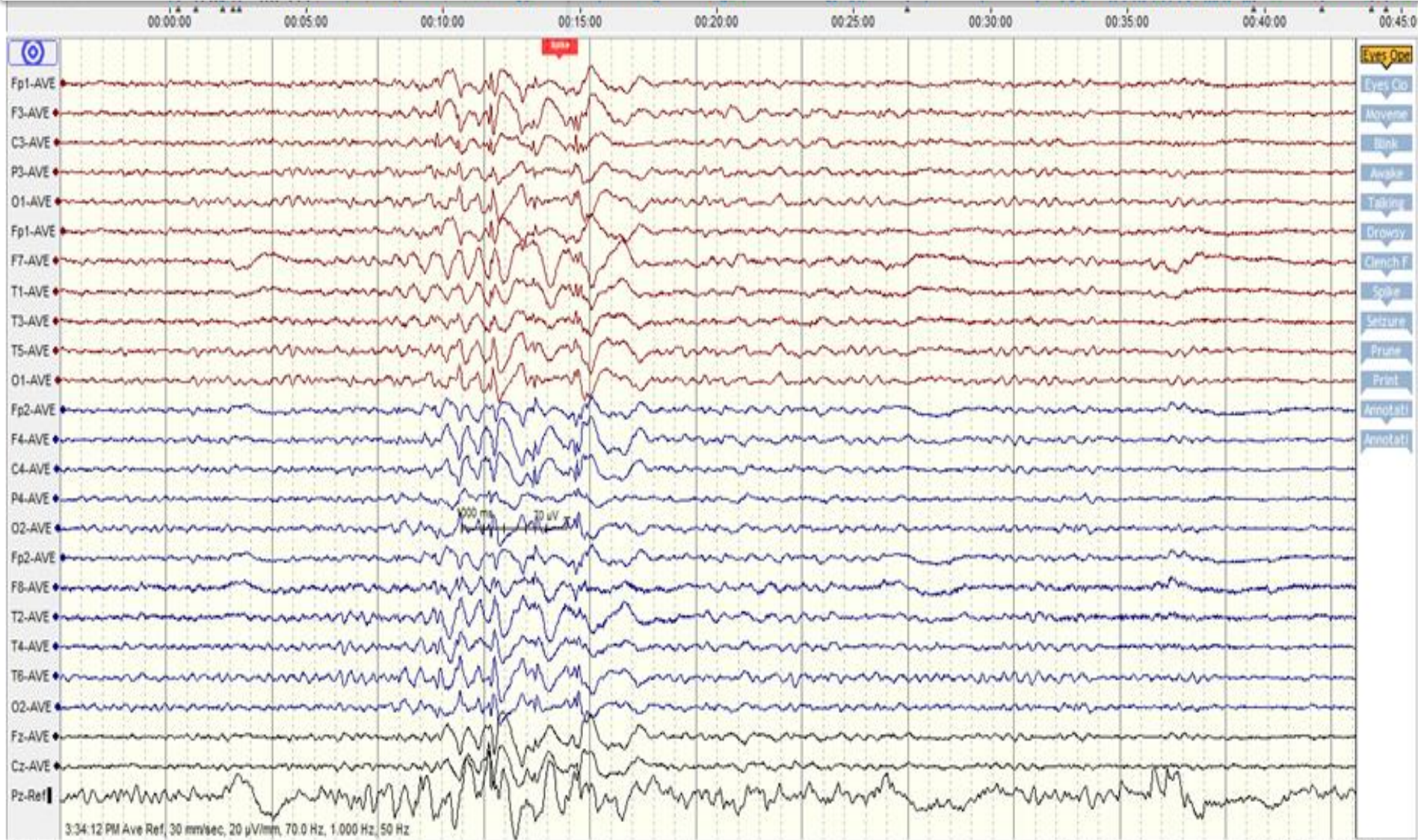
<sup>3</sup> Metropolis Labs, Kochi, Kerala - Lab Medicine, Kochi, India

Received March 22, 2016; Accepted April 17, 2017

# Case summary

- **A 21 yr old young college student presented with severe vomiting episodes after taking food**
- **No h/o epgastric aura /salivation/choking/experiential phenomena**
- **She also reported loss of consciousness following a few bouts –lasting few seconds to minutes with occasional posturing and jerking of upper limb**
- **Interictal EEG showed left frontocentral epileptiform discharges**
- **Patient has no more episodes after starting sodium valproate**

# INTERICTAL EEG



# POSSIBILITIES?

- **Focal epilepsy with ictal vomiting<sup>1</sup>**
  - Non-dominant temporal lobe
  - Insula/ Frontal opercular
- **Benign partial epilepsy –Panayiotopoulos like disorder<sup>2</sup>**
- **Reflex epilepsy-Eating epilepsy/new entity?<sup>3</sup>**

1. Pietrafusa N, de Palma L, De Benedictis A, Trivisano M, Marras CE, Vigevano F et al. Ictal vomiting as a sign of temporal lobe epilepsy confirmed by stereo-EEG and surgical outcome. *Epilepsy Behav.* 2015 ;53:112-6.
2. Panayiotopoulos C.P.: Vomiting as an ictal manifestation of epileptic seizures and syndromes. *J Neurol Neurosurg Psychiatry* 1988; 51: pp. 1448-1451
3. Senanayake N. Reflex epilepsies: experience in Sri Lanka. *Ceylon Med J.* 1994 ;39(2):67-74.