

# Pharmacoresistant epileptic eyelid twitching in a child with a mutation in *SYNGAP1*

Tetsuya Okazaki<sup>1,2</sup>, Yoshiaki Saito<sup>1</sup>, Rika Hiraiwa<sup>3</sup>, Shinji Saitoh<sup>4</sup>, Masachika Kai<sup>5</sup>, Kaori Adachi<sup>6</sup>, Yoko Nishimura<sup>1</sup>, Eiji Nanba<sup>2,6</sup>, Yoshihiro Maegaki<sup>1</sup>

<sup>1</sup> Division of Child Neurology, Department of Brain and Neurosciences, Faculty of Medicine, Tottori University, Yonago

<sup>2</sup> Division of Clinical Genetics, Tottori University Hospital, Yonago

<sup>3</sup> Department of Pediatrics, Eastern Shimane Rehabilitation Hospital, Matsue

<sup>4</sup> Department of Pediatrics and Neonatology, Nagoya City University Graduate School of Medical Sciences, Nagoya

<sup>5</sup> Division of Technical Department, Tottori University, Yonago

<sup>6</sup> Division of Functional Genomics, Research Center for Bioscience and Technology, Tottori University, Yonago, Japan

Received February 28, 2017; Accepted April 20, 2017

**ABSTRACT** – *SYNGAP1* gene mutation has been associated with epilepsy which is often drug resistant, with seizure types including eyelid myoclonia. However, detailed descriptions, including ictal video-EEG, have not been reported. We report the case of a 4-year-old boy who developed recurrent epileptic eyelid twitching at 1 year and 5 months of age. Seizures gradually increased in frequency to more than 50 times per day and manifested with upward eye deviation, motion arrest, loss of consciousness, and eyelid twitching lasting for five seconds. Ictal EEG showed rhythmic, generalized slow or spike-and-wave complex activity with posterior predominance. Moderate psychomotor developmental delay and unsteady gait were also noted. Neuroimaging results were normal. Seizures were refractory to carbamazepine and levetiracetam but were reduced in frequency by ethosuximide and lamotrigine administration. Genetic analysis identified a c.3583-6 G>A mutation in the *SYNGAP1* gene. *SYNGAP1* gene analysis should be considered for intellectually disabled patients with early-onset drug resistant eyelid twitching and photosensitivity. Further clinical research on *SYNGAP1* function may be necessary to treat epilepsy of this aetiology. [Published with video sequence on [www.epilepticdisorders.com](http://www.epilepticdisorders.com)]

**Key words:** eyelid twitching, *SYNGAP1*, intellectual disability, eyelid myoclonia



VIDEO ONLINE

**Correspondence:**

Tetsuya Okazaki  
Division of Child Neurology,  
Department of Brain and Neurosciences,  
Faculty of Medicine,  
Tottori University,  
36-1 Nishi-cho,  
Yonago 683-8504,  
Tottori, Japan  
<t-okazaki@med.tottori-u.ac.jp>

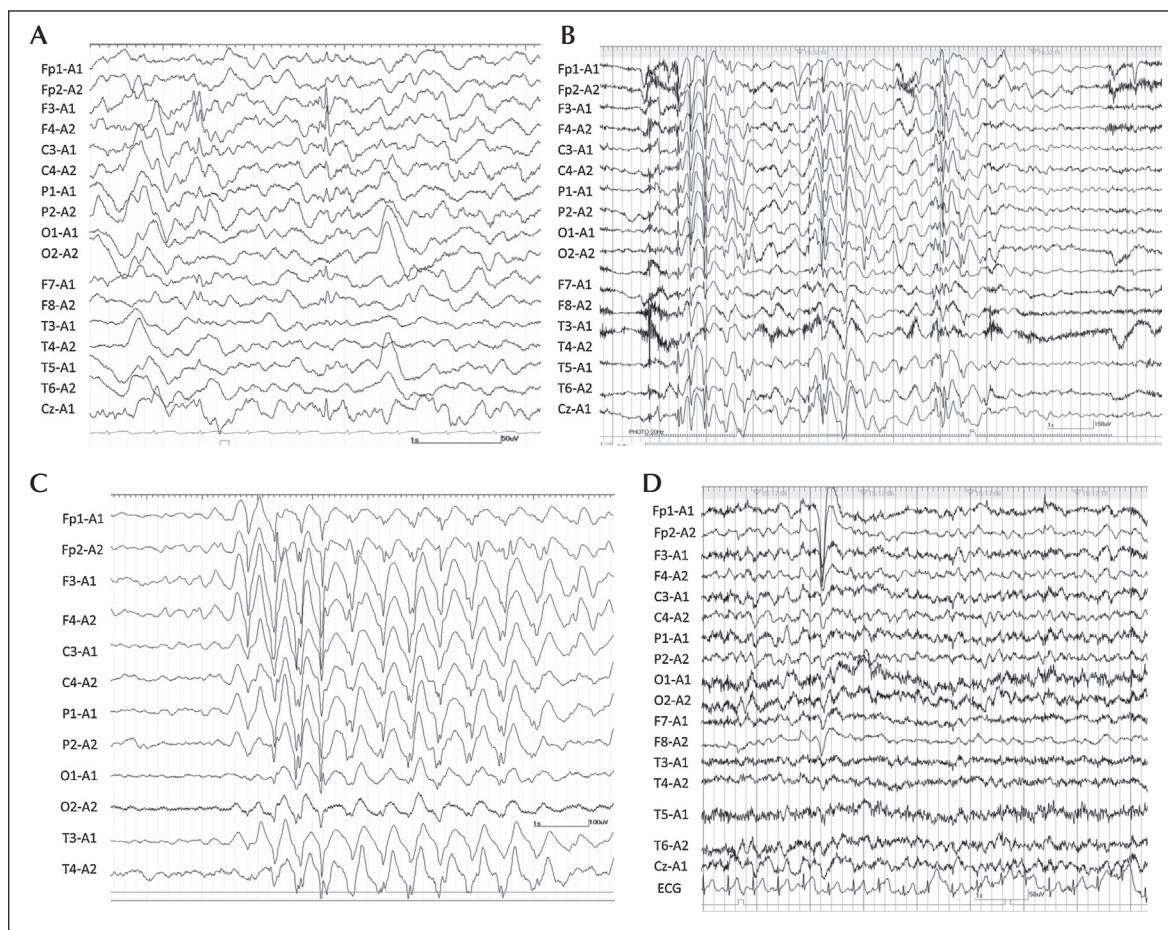
The *SYNGAP1* gene on chromosome 6p21.32 encodes a synaptic RAS-GTPase-activating protein. *SYNGAP1* haploinsufficiency disrupts the excitatory/inhibitory balance in the developing hippocampus and cortex and results in accelerated glutamatergic synapse maturation. This alters the synaptic plasticity necessary for refining connections that ultimately shape cognitive and behavioural modalities (Mignot *et al.*, 2016). Recently, a *SYNGAP1* gene mutation emerged as one of the most relevant intellectual disability-causing genes, with mutations potentially accounting for 0.7 to 1% of intellectual disabilities (Mignot *et al.*, 2016). Furthermore, *SYNGAP1* gene mutations have been associated with generalized epilepsy and variable seizure types, including absence, tonic-clonic, and myoclonic seizures and eyelid myoclonia (Berryer *et al.*, 2013; Mignot *et al.*, 2016). Photosensitivity has been reported in patients with eyelid myoclonia (Parker *et al.*, 2015; Mignot *et al.*, 2016). Mignot *et al.* described

three patients with eyelid myoclonia among 16 with *SYNGAP1* gene mutations (Mignot *et al.*, 2016).

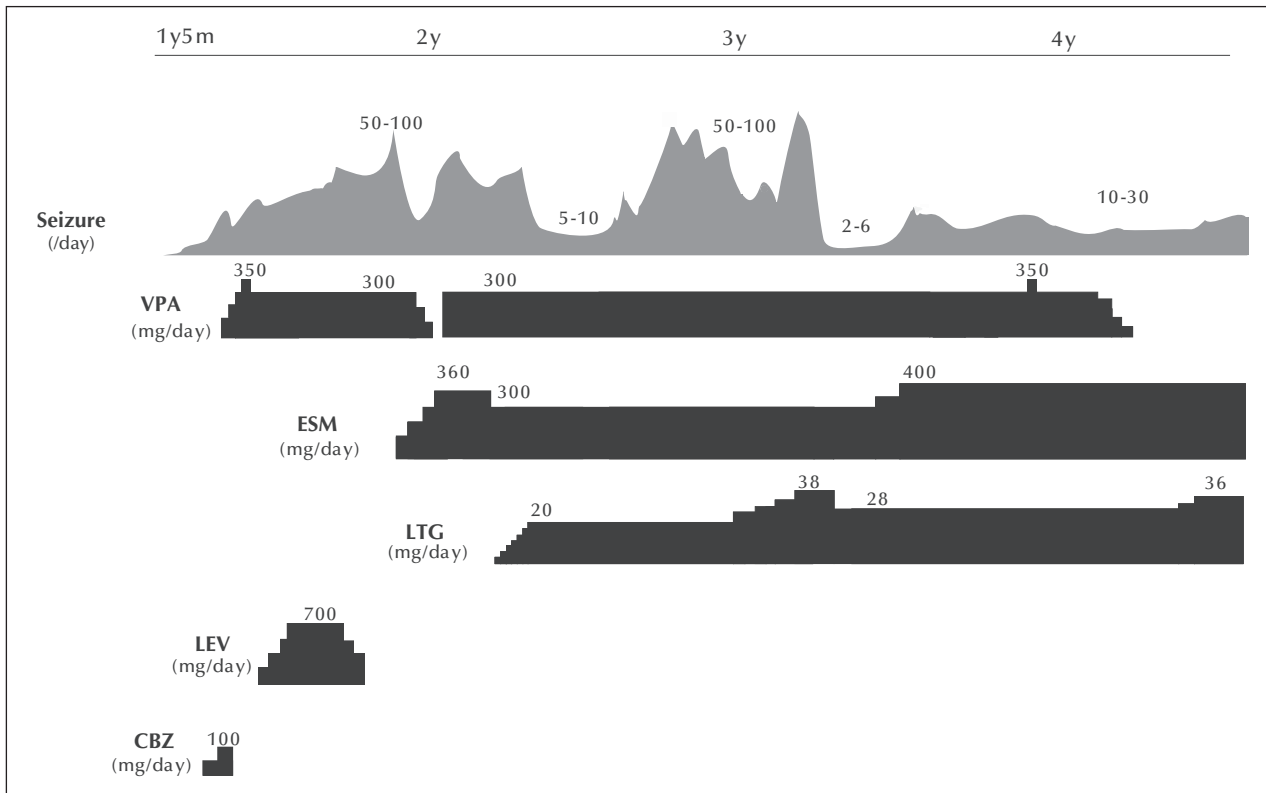
Detailed descriptions of ictal EEG and the clinical course of eyelid phenomena with a *SYNGAP1* gene mutation have not been reported. Herein, we describe the epileptic phenotype of eyelid twitching in a patient with a *SYNGAP1* mutation, which could provide useful information for making an early diagnosis in such patients.

## Case study

A 4-year-old boy was born to non-consanguineous parents at 40 weeks, with a birth weight of 3,510 g (SD: +1.3), body length of 49.4 cm (SD: +0.2), and head circumference of 35.5 cm (SD: +1.6). No family history of intellectual disability or epilepsy was reported. He did not incur birth asphyxia. He gained the ability to smile



**Figure 1.** Ictal and interictal EEG. (A) Interictal EEG during sleep at 1 year and 7 months of age revealed bilateral frontal spikes. (B) Ictal EEG during photic stimulation at a frequency of 20 Hz at 2 years and 3 months of age revealed diffuse spike-and-wave activity, simultaneous with motion arrest, unresponsiveness, upward eye deviation, and intermittent eyelid twitching lasting for several seconds. (C) EEG during sleep at 2 years and 3 months of age revealed rhythmic 2-3-Hz delta activity without visible seizures. (D) Interictal EEG at 1 year and 9 months of age during wakefulness showed normal background activity.



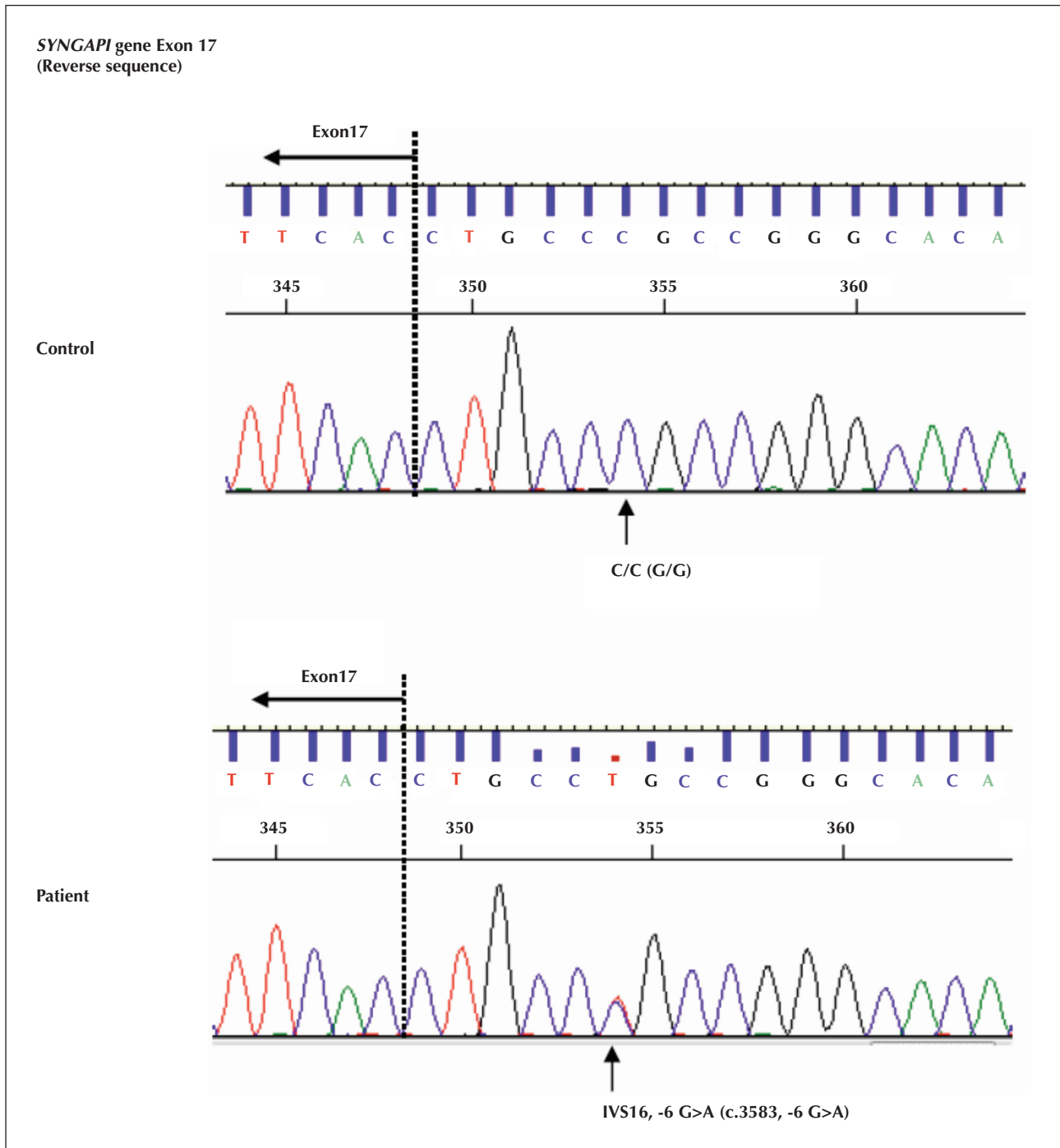
**Figure 2.** Clinical course. Seizures presenting as eyelid twitching were initially noticed at 1 year and 5 months of age. Seizures were refractory to carbamazepine (CBZ) and levetiracetam (LEV). At 2 years of age, seizure frequency increased when the dosage of valproate (VPA) was decreased, but at 4 years of age, the frequency did not change even when discontinued. At 2 years of age, frequent seizure episodes were reduced by ethosuximide (ESM). Seizures were aggravated after decreasing the ESM dosage at 3 years of age, but were alleviated by an increased dosage of lamotrigine (LTG) and ESM.

socially at 3 months, control his head at 5 months, sit unsupported at 11 months, stand with support at 19 months, and walk at 25 months.

He experienced his first seizure at 1 year and 5 months. Episodes gradually increased in frequency to more than 50 times per day and manifested with upward eye deviation, motion arrest, loss of consciousness, and eyelid twitching at 2-3 Hz, lasting for five seconds. Interictal EEG at 1 year and 7 months showed bilateral frontal spikes (*figure 1A*). Seizures were refractory to carbamazepine. Therefore, valproate and levetiracetam were initiated. However, seizures were again aggravated. Levetiracetam was terminated and ethosuximide was initiated at 1 year and 11 months. At 2 years, seizure frequency increased upon decreasing valproate dosage, but at 4 years, the frequency did not change even when valproate was discontinued. Between 2 and 3 years, seizure aggravation was alleviated with ethosuximide and lamotrigine (*figure 2*). Seizures appeared more often in the morning or when he was drowsy, and the frequency also temporarily increased during intercurrent diseases (infection with or without fever).

Ictal EEG at 2 years and 3 months revealed diffuse slow or spike-and-wave activity with occipital to central predominance (*figure 1B*). Seizures spontaneously emerged (*see video sequence*) and were provoked by making the child cry and providing photic stimulations of 6-30 Hz. EEG changes induced by eye closure and fixation-off could not be evaluated because he was unable to follow our instructions. Sleep EEG at 2 years and 3 months revealed rhythmic, generalized 2-3-Hz delta activity, lasting for seven seconds without visible seizures (*figure 1C*). Interictal EEG at 1 year and 9 months during wakefulness showed normal background activity (*figure 1D*). Other seizure types did not occur. No abnormality was noted on brain MRI at 2 years and 2 months.

A physical examination at 4 years revealed generalized hypotonia, but his muscle strength and deep tendon reflexes were normal. He could not utter meaningful words. Open mouth and hypersalivation were observed. Cerebellar signs were not seen. His gait was clumsy, and he occasionally fell to the floor. His developmental quotient at 3 years and 11 months was



**Figure 3.** Results of *SYNGAP1* gene analysis. A heterozygous mutation, c.3583-6 G>A, was identified.

found to be 35.3 according to the Enjoji Developmental Scale (Tokyo, Japan, 1976).

Glucose concentration in the cerebrospinal fluid (CSF) and CSF-to-blood glucose ratio were normal. G-band chromosomal analysis revealed a normal male karyotype of 46; XY. Genetic analysis for Angelman syndrome was unremarkable. *SYNGAP1* gene mutation was confirmed by exhaustive genetic

analysis using next-generation sequencing. An Illumina TruSight One sequencing panel using a MiSeq platform (Illumina, San Diego, CA, USA) was used, and a heterozygous single nucleotide variant in *SYNGAP1* (c.3583-6 G>A; p.Val1195Alafs\*27) was found, which was validated by Sanger sequencing (figure 3). This variant has been previously described by Redin et al. (2014) in a child with intellectual disability, however,

the presence or absence of epilepsy was not described. This variant creates a novel splicing acceptor site causing a frameshift mutation, leading to a premature stop codon (Redin *et al.*, 2014). The boy's parents did not agree to undergo genetic analysis of their *SYNGAP1* genes. Neither parent displayed *SYNGAP1* phenotypic features.

## Discussion

To our knowledge, this is the first report of *SYNGAP1*-related epilepsy which includes a detailed clinical course and demonstration of ictal video-EEG findings. In a previous report, epileptic seizures were provoked by photic stimulation in five of 16 patients with *SYNGAP1* gene mutations, including two out of three with a seizure type corresponding to eyelid myoclonia (Mignot *et al.*, 2016). This was also observed in the present patient and could be regarded as a characteristic of this entity. In the present patient, eyelid twitching was rhythmic and correlated with a 2-3-Hz generalized spike-and-wave complex. The semiology in this case is reminiscent of that for eyelid myoclonia with absences (EMA; Jeavons syndrome) and childhood absence epilepsy (CAE) (Camfield *et al.*, 2004; Caraballo *et al.*, 2009). However, eyelid myoclonia in EMA is usually more rapid, ranging from 3-6 Hz (Caraballo *et al.*, 2009), and photic provocation is not typical in CAE. Frontal predominance in ictal spike-wave activity is also characteristic in these generalized epileptic syndromes, in contrast to the posterior predominance in the present and other cases of *SYNGAP1*-related genetic epileptic syndrome (Hamdan *et al.*, 2009). Patients diagnosed with EMA and intellectual disabilities have been previously reported (Fournier-Goodnight *et al.*, 2015; Ogura *et al.*, 2005), and it is possible that these patients and the present case share the same aetiology.

Decrease in *SYNGAP1* expression in GABAergic cells impairs inhibitory synapse connectivity and synaptic inhibition in mouse models (Berryer *et al.*, 2013). However, GABA agonists, namely lamotrigine and benzodiazepines, have not always been successful as treatment for *SYNGAP1*-related epilepsy (Mignot *et al.*, 2016); lamotrigine was partially effective in the present patient. Additionally, drugs acting on AMPA receptors (e.g. topiramate or perampanel) might be promising, given that neuronal cultures from mutant *SYNGAP1* mice had more synaptic AMPA receptors (Kim *et al.*, 2003; von Stülpnagel *et al.*, 2015). Topiramate was ineffective in two patients in a previous report (Mignot *et al.*, 2016), and the efficacy of these agents needs to be further explored.

Epilepsy in patients with mutations in exons 4-5 appears more pharmacosensitive than in those with mutations in exons 8-15, possibly resulting from the

residual action of an isoform lacking exons 4-5 (Mignot *et al.*, 2016). In accordance with this, the c.3583-6 G>A mutation in our patient was located in intron 16, which may further expand the pharmacoresistant locus at the 3' end. The response to treatment in cases with *SYNGAP1* mutation might depend on the site of the mutation more than the extent of dysregulation of the aforementioned GABA and AMPA receptors. Effective treatment for pharmacoresistant epilepsy in patients with *SYNGAP1* mutation has yet to be explored. □

### Supplementary data.

Summary didactic slides are available on the [www.epilepticdisorders.com](http://www.epilepticdisorders.com) website.

### Disclosures.

The authors have no conflict of interest to disclose.

### Legend for video sequence

Ictal recording of video-EEG at 2 years and 3 months of age. Eyelid twitching spontaneously appeared and lasted for five seconds. Note that upward eye deviation, motion arrest, loss of consciousness, and eyelid twitching at 2-3 Hz are accompanied by generalized high-amplitude slow activity with spikes or sharp waves. Myoclonus of the body, synchronized with eyelid twitching, is also noted in this recording.

### Key words for video research on [www.epilepticdisorders.com](http://www.epilepticdisorders.com)

*Phenomenology:* epilepsy

*Localisation:* generalized

*Syndrome:* not applicable

*Aetiology:* *SYNGAP1* gene mutation

## References

- Berryer MH, Hamdan FF, Klitten LL, *et al.* Mutations in *SYNGAP1* cause intellectual disability, autism, and a specific form of epilepsy by inducing haploinsufficiency. *Hum Mutat* 2013; 34: 385-94.
- Camfield CS, Camfield PR, Sadler M, *et al.* Paroxysmal eyelid movements: a confusing feature of generalized photosensitive epilepsy. *Neurology* 2004; 63: 40-2.
- Caraballo RH, Fontana E, Darra F, *et al.* A study of 63 cases with eyelid myoclonia with or without absences: type of seizure or an epileptic syndrome? *Seizure* 2009; 18: 440-5.
- Fournier-Goodnight AS, Gabriel M, Perry MS. Preliminary neurocognitive outcomes in Jeavons syndrome. *Epilepsy Behav* 2015; 52: 260-3.
- Hamdan FF, Gauthier J, Spiegelman D, *et al.* Mutations in *SYNGAP1* in autosomal nonsyndromic mental retardation. *N Engl J Med* 2009; 360: 599-605.

Kim JH, Lee HK, Takamiya K, Huganir RL. The role of synaptic GTPase-activating protein in neuronal development and synaptic plasticity. *J Neurosci* 2003;23: 1119-24.

Mignot C, von Stülpnagel C, Nava C, et al. Genetic and neurodevelopmental spectrum of SYNGAP1-associated intellectual disability and epilepsy. *J Med Genet* 2016;53: 511-22.

Ogura K, Maegaki Y, Koeda T. EEG evaluation of fixation-off sensitivity in eyelid myoclonia with absences. *Pediatr Neurol* 2005;33: 142-5.

Parker MJ, Fryer AE, Shears DJ, et al. De novo, heterozygous, loss-of-function mutations in SYNGAP1 cause a syndromic form of intellectual disability. *Am J Med Genet A* 2015;167A: 2231-7.

Redin C, Gérard B, Lauer J, et al. Efficient strategy for the molecular diagnosis of intellectual disability using targeted high-throughput sequencing. *J Med Genet* 2014;51: 724-36.

von Stülpnagel C, Funke C, Haberl C, et al. SYNGAP1 mutation in focal and generalized epilepsy: a literature overview and a case report with special aspects of the EEG. *Neuropediatrics* 2015;46: 28-91.

## TEST YOURSELF



- (1) What is the common seizure phenotype in patients with SYNGAP1 mutation: generalized or localization-related epilepsy?
- (2) Is photosensitivity an unusual symptom in SYNGAP1-related epileptic eyelid twitching?
- (3) What is the cardinal point in the differential diagnosis of SYNGAP1-related epilepsy in relation to childhood epilepsy (CAE) and eyelid myoclonia with absences (EMA)?

*Note: Reading the manuscript provides an answer to all questions. Correct answers may be accessed on the website, [www.epilepticdisorders.com](http://www.epilepticdisorders.com), under the section "The EpiCentre".*