

# Surgical treatment of extra-hypothalamic epilepsies presenting with gelastic seizures

Holger Joswig<sup>1</sup>, Patricia Rejas-Pinelo<sup>1,2</sup>, Ana Suller<sup>1</sup>,  
Richard S. McLachlan<sup>1</sup>, David A. Steven<sup>1</sup>

<sup>1</sup> Epilepsy Program, Department of Clinical Neurological Sciences, London Health  
Sciences Centre, University Hospital, London, ON, Canada

<sup>2</sup> School of Medicine, Research and Innovation Centre of the Faculty of Health Sciences,  
Universidad Peruana de Ciencias Aplicadas, Lima, Peru

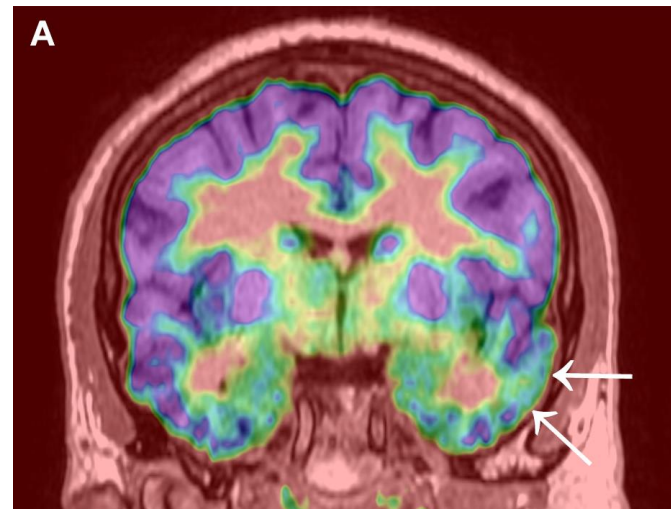
Received August 15, 2018; Accepted April 27, 2019

# Surgical Treatment of Extra-hypothalamic Epilepsies Presenting With Gelastic Seizures

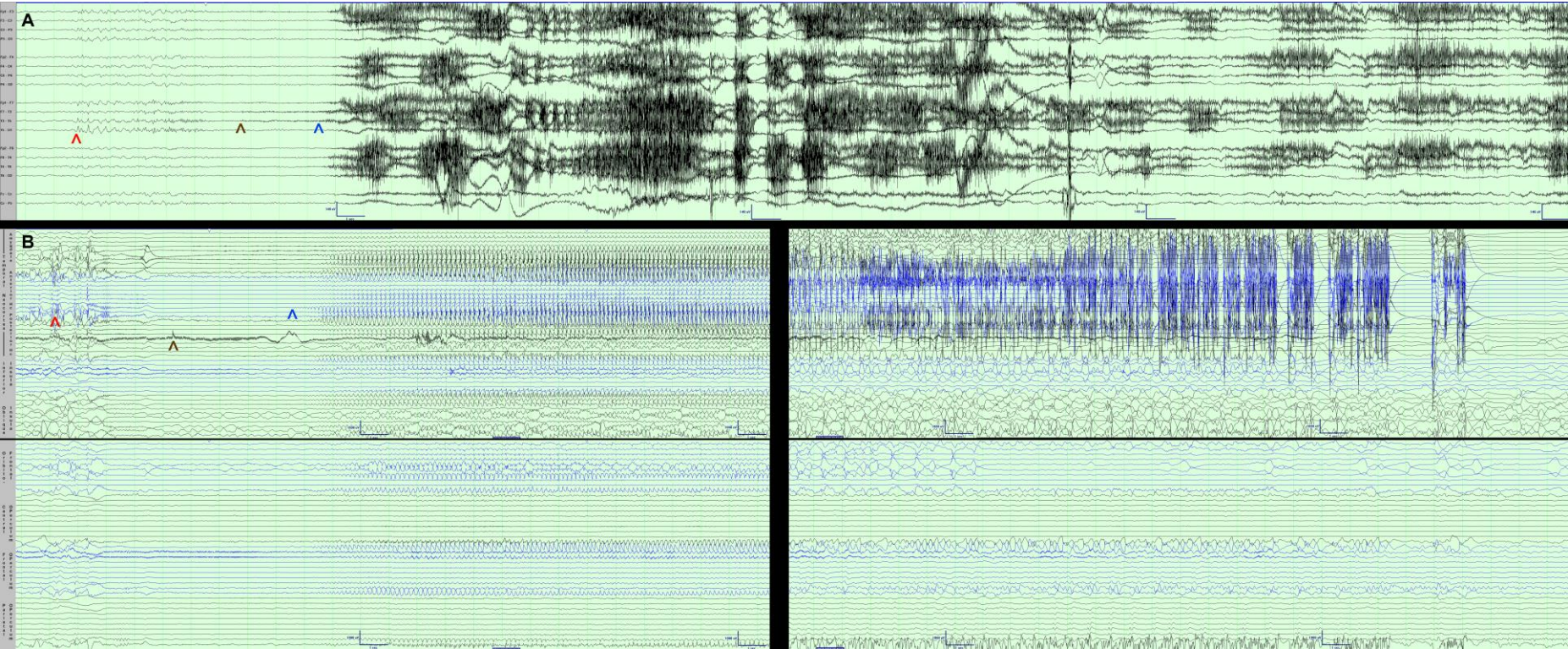
41-year-old male with drug-refractory mirthful laughing seizures

**MRI and SPECT:** non-lesional

**$^{18}\text{F}$ -FDG PET:** left temporal hypometabolism



# Scalp and stereoelectroencephalographic EEG



# Follow-up

Temporal seizure-onset zone determined

Seizure freedom one year after left anterior temporal lobectomy while awake

