

Clinical commentary

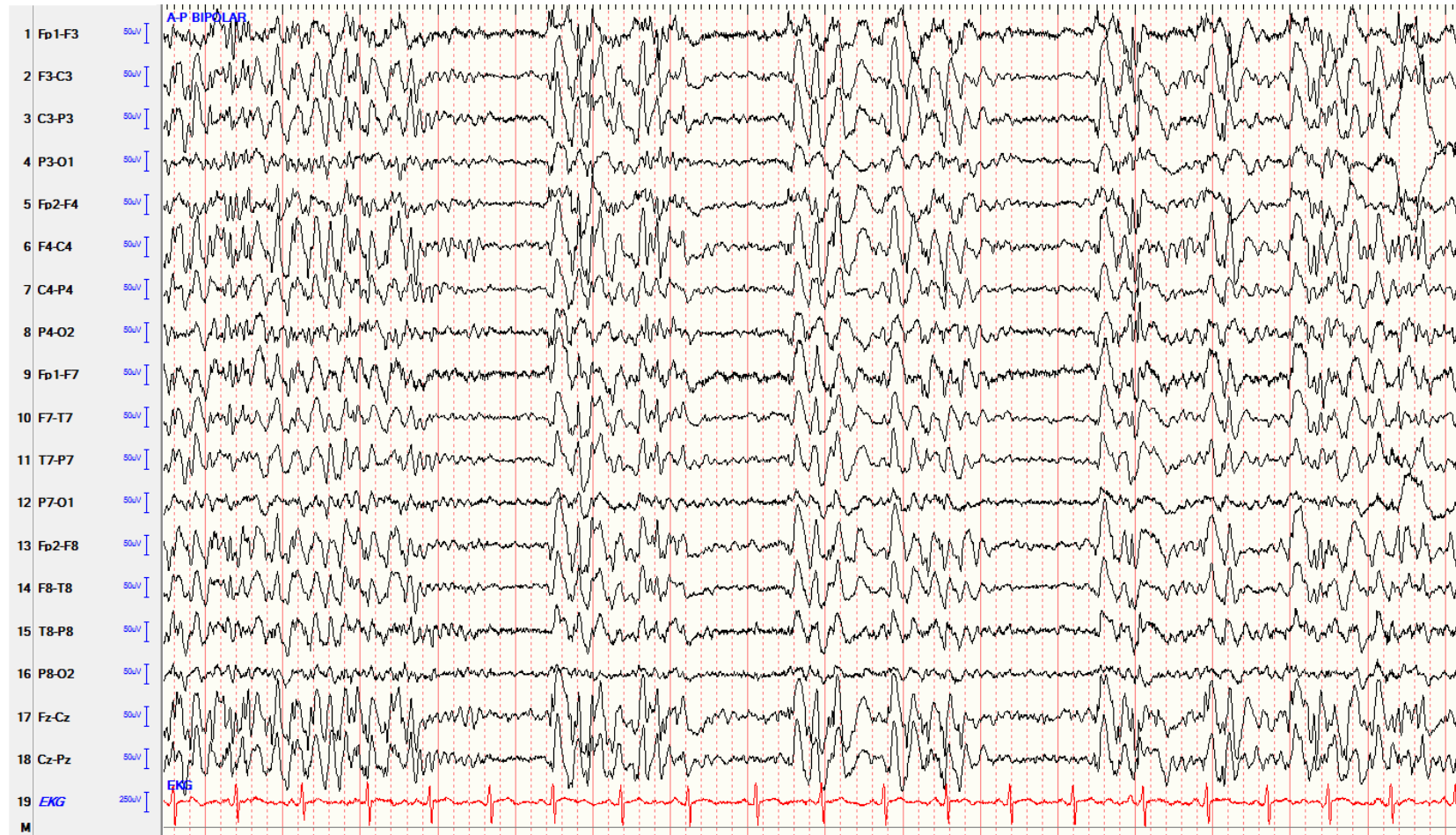Epileptic Disord 2019; 21 (1): 97-101

Absence status induced by lacosamide adjunctive therapy

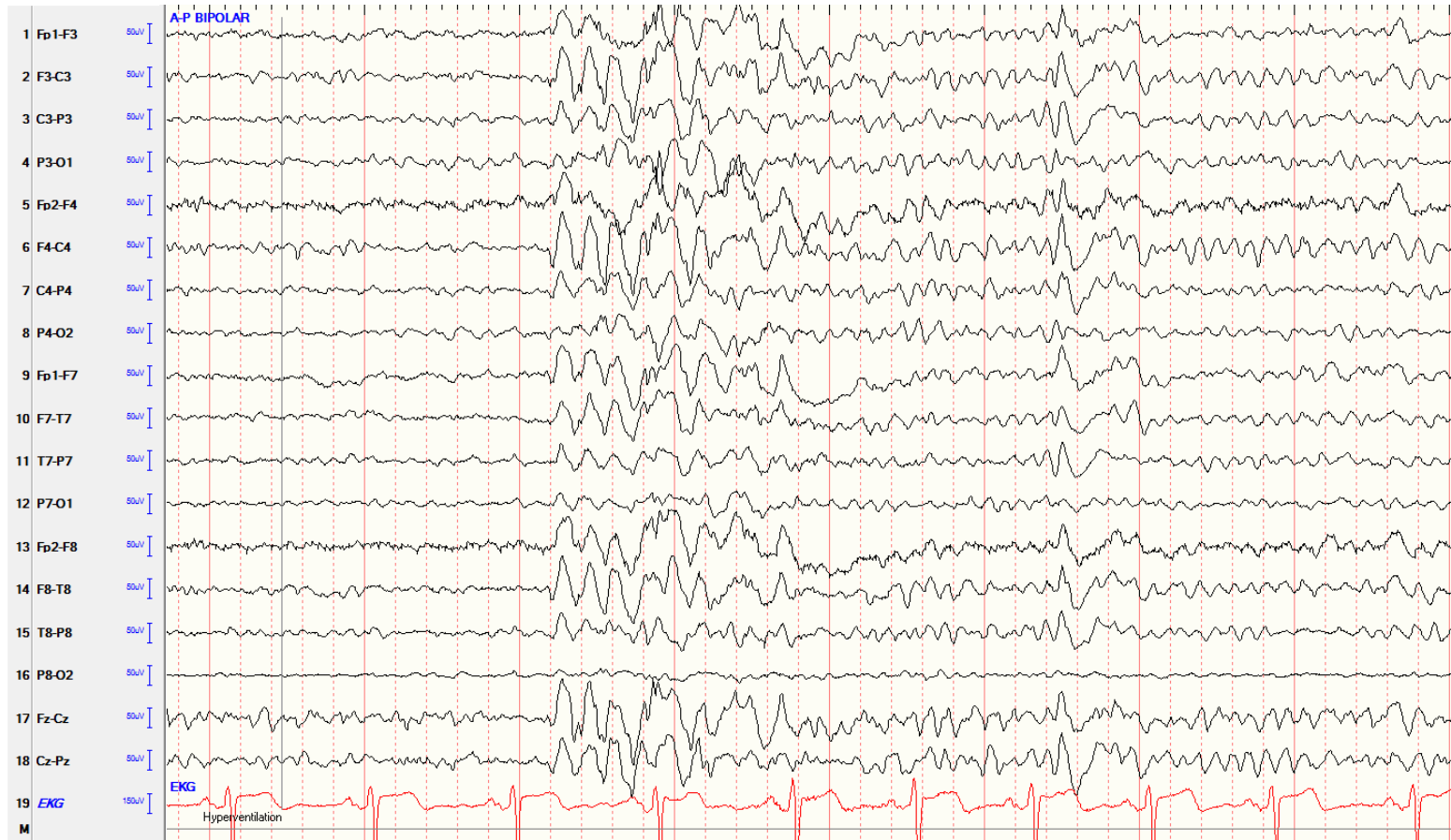
Charles Ákos Szabó, Lola C. Morgan, Suzanne Sonnenberg,
Kameel M. Karkar

Department of Neurology and South Texas Comprehensive Epilepsy Center, UT Health
San Antonio, San Antonio, Texas

Received August 16, 2018; Accepted November 01, 2018



Absence status. Paroxysms of 3-5-Hz generalized spike- and polyspike-and-wave discharges are demonstrated on this 20-second EEG sample recorded using an anterior-posterior bipolar montage. Note the brief return of the patient's normal background activity between the paroxysms.



Interictal epileptic discharges triggered by hyperventilation. A 3-5-Hz generalized spike-and-wave discharge is triggered by hyperventilation after resolution of the absence status on this 10-second EEG sample, recorded using an anterior-posterior bipolar montage.