

Dyskinesia as a new adverse effect of hormonal treatment in West syndrome

Biayna G. Sukhudyán^{1,2}, Petia S. Dimova³,
Alessandro Capuano⁴, Federico Vigevano⁴

¹ "Arabkir" Medical Complex and Institute for Child and Adolescent Health

² Chair of Pediatrics #1, Yerevan State Medical University, Yerevan, Armenia

³ Clinic of Child Neurology, St Naum University Hospital of Neurology and Psychiatry, Sofia, Bulgaria

⁴ Neurology Unit, Bambino Gesù Children's Hospital, IRCSS, Rome, Italy

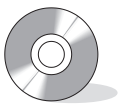Received August 9, 2013; Accepted November 13, 2014

ABSTRACT – West syndrome is an age-dependent epileptic encephalopathy. Despite potential side effects, hormonal therapy remains the main treatment for West syndrome. Here, we report on 10 patients receiving steroid treatment who presented with unusual, mostly hyperkinetic, movements. Facial grimacing, repetitive mouth opening, adduction and abduction of upper and lower extremities, and periodical strabismus in different combinations were observed in all patients, independent of formulation, dose, duration, and efficacy of treatment. Symptoms disappeared in sleep and reappeared immediately on arousal. Dyskinesias stopped gradually after a month of discontinuation of treatment. Repeated EEGs did not show corresponding epileptiform activity. We conclude that these abnormal movements can be attributed to side effects of hormonal treatment. [Published with video sequences]

Key words: steroids, ACTH, infantile spasms, West syndrome, dyskinesia, children

West syndrome is an epileptic encephalopathy of infancy, characterised by infantile spasms, hypsarrhythmia on EEG, and variable regression of development. In most cases, causal underlying pathologies can be identified. The existence of idiopathic West syndrome is, however, controversial and genetic, structural-metabolic, and "unknown" causes represent modified concepts to replace idiopathic, symptomatic, and cryptogenic classification of most electroclinical syndromes (Berg *et al.*, 2010).

Some cases of West syndrome, with variable aetiology, rarely feature a movement disorder, however, the nature and significance of this remain unclear. The use of the term "cerebral palsy" as a putative "predisposing cause" may obscure recognition of a movement disorder as a specific feature associated with West syndrome (Paciorkowski *et al.*, 2011). Movement disorders may accompany spasms in both structural and metabolic cases. Additionally, dyskinetic movements may be frequently observed with different



Correspondence:

Biayna Sukhudyán, 30 Mamikonyants Str.,
Yerevan, Armenia
<biayna_sukh@yahoo.com>

genetic aetiologies of West syndrome (Stromme *et al.*, 2002). Movement disorders are rarely reported in association with pharmacotherapy of West syndrome (Dill *et al.*, 2013).

To our knowledge, the occurrence of transient movement disorder has never been reported in patients with hormonal therapy. Here, we report 10 patients with West syndrome who developed unusual movements on steroid treatment.

Methods

In this retrospective observational study, we investigated patients who had developed unusual movements during steroid therapy for West syndrome. Inclusion criteria were infants with spasms, hypsarrhythmia on EEG, and occurrence of hyperkinetic movements on hormonal therapy. Patients were collected from three institutions: the “Arabkir” Medical Complex and Institute for Child and Adolescent Health, Yerevan, Armenia; the Clinic of Child Neurology, St. Naum University Hospital of Neurology and Psychiatry, Sofia, Bulgaria; and the Bambino Gesù Children’s Hospital, Rome, Italy.

Since adrenocorticotrophic hormone (ACTH) is not consistently used in all institutions, all patients from Armenia with clinically and electrographically-confirmed West syndrome received methylprednisolone as a first drug of choice. Children who clearly fulfilled clinical criteria for tuberous sclerosis complex received vigabatrin. If additional investigations revealed tuberous sclerosis, hormonal treatment was changed to vigabatrin when feasible. Thus, some patients with tuberous sclerosis received hormonal treatment.

Armenian subjects received the following scheme of hormonal therapy from 2008-2011. Methylprednisolone was given orally (8 mg four times a day for two weeks, and increased to 16 mg three times a day after two weeks if spasms continued). After two weeks of treatment, children received a tapering dose of methylprednisolone with a reduction of 8 mg every five days or, if on the higher dose of treatment, 32 mg daily, then 16 mg, and then 8 mg for five-day periods.

All patients from Bulgaria received ACTH IM at a dose of 0.25 mg/day for 10-14 days, with a subsequently increased interval (once every other day, up to once a week). The total duration of the ACTH course amounted to five to eight weeks, depending mainly on the occurrence of side effects that prompted, in some patients, an earlier increase of the drug-free intervals and withdrawal. Two patients from Italy received ACTH depot IM at 0.1 mg every day for two weeks with further decrease to 0.1 mg on every third day for 15 days, with eventual discontinuation of the drug.

Detailed aetiological classification was not always possible, due to limited access to laboratory investigations for Armenian subjects.

Results

Clinical characteristics of our patients are summarised in *table 1*. A specific cause of West syndrome was identified in only 4 patients. Genetic testing in one and medical history (severe birth asphyxia) and clinical data (microcephaly and spastic tetraparesis) in another helped to establish genetic and structural causes of West syndrome, respectively. A structural origin of West syndrome was confirmed by brain MRI investigation in 2 patients with multiple focal dysplasias and severe brain atrophy of unknown origin, respectively.

Overall, neuroimaging (MRI performed five times and CT once) was performed in 6 of 10 patients; four investigations (MRI performed three times and CT once) were reported to be normal. Absence of global delay before spasms, excellent response to therapy, absence of any other seizure types, and normal development during follow-up led to classification of a patient with normal CT as “idiopathic.” The most frequent side effect of hormonal therapy was cushingoid appearance of the face. Other side effects are illustrated in *table 2*. Purposeless, repetitive mouth opening, facial grimacing, adduction and abduction of upper and lower extremities, and periodic strabismus in different combinations were observed in patients independently of dose, duration, or efficacy of therapy. Facial dyskinesias were observed in all patients. They interfered with feeding and emotional smiling; involuntary eye muscle movements made an impression of absent visual fixation. Tube feeding was, however, never required. Hyperkinesia in extremities interfered with voluntary movements. They disappeared in sleep and reappeared immediately on arousal. The earliest appearance of dyskinesias was at two weeks of steroid treatment. In all children, they lasted approximately a month after discontinuation of therapy and never reoccurred again. Since involuntary movements clinically resembled spasms, EEGs were performed repeatedly and did not show corresponding epileptiform activity. In three patients, besides dyskinetic movements, we observed sustained retro- and torticollis. In all cases, we registered disappearance of hypsarrhythmia, although control of spasms was not always satisfactory.

Three of our 10 patients died; 2 of them in hospital about a month after steroid treatment. One patient died from pneumonia which he developed whilst receiving treatment and the second patient died a month after withdrawal of steroids. A third patient died

Table 1. Clinical and laboratory data.

Patient	1	2	3	4	5	6	7	8	9	10
Perinatal history	normal	complicated	complicated	complicated	normal	normal	complicated	complicated	normal	normal
Age at onset of spasms (months)	6	4	2	3	5	5	4	7	6	
Other seizure types	-	PS	-	PS, M	GS	PS	PS, TS	PS, TS	-	-
GDD	+	+	+	+	+	+	+	+	-	+
EEG before treatment	HA	HA	HA	HA	HA	HA	HA	HA	HA	HA
EEG on treatment	focal	normal	normal	normal	generalised	multi-focal/focal	multi-focal	normal	multi-focal	multi-focal
Treatment	MP	MP	MP	MP	MP	ACTH	ACTH	ACTH	ACTH	ACTH
Efficacy	-	+	-	+	-	-	+	+	+	+
Neuroimaging	nd	MRI normal	nd	nd	MRI normal	MRI multiple FCD	MRI Severe brain atrophy	nd	CT normal	MRI normal
Genetic tests	-	dup (15/q11.2)	-	-	-	-	-	-	-	-
Death (months)	-	-	18	6	7	-	-	-	-	-

Clinical data of 10 patients with West syndrome who developed dyskinesia with hormonal treatment. In six of ten patients, treatment was effective. A specific cause of West syndrome was known in only four patients. Three patients died. Only one patient showed no other seizure types and normal development during follow-up.

Patients 1-5: Armenia; Patients 6-8: Bulgaria, Patients 9-10: Italy.

Abbreviations: GDD: global developmental delay; HA: hypsarrhythmia; MP: methylprednisolone; ACTH: adrenocorticotrophic hormone; PS: partial seizure; M: myoclonia; GS: generalised seizure; TS: tonic seizure; FCD: focal cortical dysplasia; nd: not done.

suddenly at home, five months after discharge. No warning signs were reported by parents in the previous days.

Case studies

Patient 2

A female was delivered by urgent Caesarean section at 36 gestational weeks. Asphyxia was reported at birth. She started having infantile spasms in clusters manifesting as brief flexion of the body and adduction of extremities at the age of 4 months. Her spasms were associated with partial seizures. EEG showed hypsarrhythmia. The patient received methylprednisolone at 32 mg for two weeks with subsequent increase to 48 mg for one week, and showed disappearance of spasms and hypsarrhythmia. At the beginning of the third week, she appeared to be cushingoid. Dyskinesias of facial muscles (mouth opening and closure, and grimacing), eye move-

ments in the form of periodic strabismus, and left hand abduction-adduction movements appeared. EEG showed normalisation of background activity, with no EEG correlate for excessive movements. Global delay in development was reported before onset of epilepsy. Brain MRI was interpreted as normal. Cytogenetic examination revealed a supernumerary chromosome. Further detailed examination by FISH and array-CGH showed dup(15/q11.2). During follow-up, the girl did not have peculiar dysmorphic features and appeared hypotonic, ataxic, and autistic with severe motor and speech delay. Seizures were never observed after cessation of spasms.

Patient 6

A female was born from uneventful pregnancy and delivery. Seizures started at the age of 50 days and were described as asymmetric tonic with versive features to the right. They were multiple per day (up to 50) and remained unchanged under treatment with valproic acid and later, phenobarbitone. Pancytopenia,

Table 2. Adverse effects of hormonal treatment.

Patient	1	2	3	4	5	6	7	8	9	10
Daily dose of steroids	MP 32 mg p.o.	MP 48 mg p.o.	MP 32 mg p.o.	MP 32 mg p.o.	MP 4 mg p.o.	ACTH 0.25 mg IM every second day	ACTH 0.25 mg IM every day	ACTH 0.25 mg IM every second day	ACTH 0.1 mg IM every day	ACTH 0.1 mg IM every day
Cushingoid appearance	+	+	+	-	-	+	+	+	-	-
Hypertension	-	-	+	-	-	-	-	-	-	-
Electrolyte disturbances	-	-	+	-	-	-	-	-	-	+
Hyperglycaemia	-	-	+	-	-	-	-	-	-	-
Infection	-	-	+	+	-	-	-	+	-	-
Hyperkinesias										
Face	+	+	+	+	+	+	+	+	+	+
Extremities	-	+	+	-	-	+	+	-	+	-
Retro-/torticollis	-	-	-	+	-	-	+	+	-	-

All patients had adverse effects of hormonal treatment. The most frequent side effect was cushingoid appearance of the face. Infection was reported in three patients. Facial dyskinesias were observed in all patients. In addition to dyskinetic movements, sustained retro- and torticollis was observed in three patients.

MP: methylprednisolone; ACTH: adrenocorticotrophic hormone.

with marked thrombocytopenia and other haematological side effects, led to withdrawal of valproate and replacement by oxcarbazepine. At the age of 3 months, while experiencing a transient reduction in seizure frequency, the child underwent brain MRI investigation, which revealed global cortical atrophy and bilateral focal cortical dysplasias that were extensive in the right frontal and temporo-occipital regions, and evident also on CT. At that time, spasms with asymmetric features (eyes and head deviation to the right, sometimes with a more prominent tonic component in the left limbs) appeared in series. Frequently, a focal seizure of the type described above introduced or followed the spasm series, and EEG showed hypsarrhythmia, more prominent on the right. Subsequent add-on clonazepam did not change the condition and ACTH therapy was started. During the third week of this treatment, during which time she improved (the spasms manifested as isolated events up to 4-5/day and were usually associated with a focal seizure, as described above) and gained weight only with cushingoid appearance, the child manifested stereotyped hyperkinesias. These were almost constant in the awake state and presented mainly as brief truncal dystonia and rarely as facial dyskinesias (forced eye closure and mouth opening) and extension and abduction of the limbs (most often the legs). No EEG ictal correlation was found and ACTH was tapered during the

next two weeks leading to gradual disappearance of the hyperkinesias. Vigabatrin suppressed the spasms, but focal seizures persisted and remained unchanged during multiple subsequent trials of all locally available anticonvulsants. Neurodevelopmental delay coincided with the epilepsy onset and became progressively worse. Multiple EEGs after hypsarrhythmia disappearance showed almost continuous epileptiform activity in the right temporo-parieto-occipital region of the right hemisphere, with intermittent and brief asynchronous focal activity on the right frontal area. Ictal video-EEG performed on several occasions confirmed seizure generation in the posterior right-sided focus and a surgical temporo-parieto-occipital disconnection was performed. After three months of seizure-freedom, a new seizure type appeared (tonic-clonic in the left hemibody) and a second operation, consisting of a right frontal lobectomy (sparing the motor cortex) and anterior corpus callosotomy, was performed. The child has been seizure-free with two drugs for more than one year and at present continues to be seizure-free and shows improved neuropsychological development.

Patient 10

A male was born after uneventful pregnancy and Caesarean section. The Apgar score was nine at the first

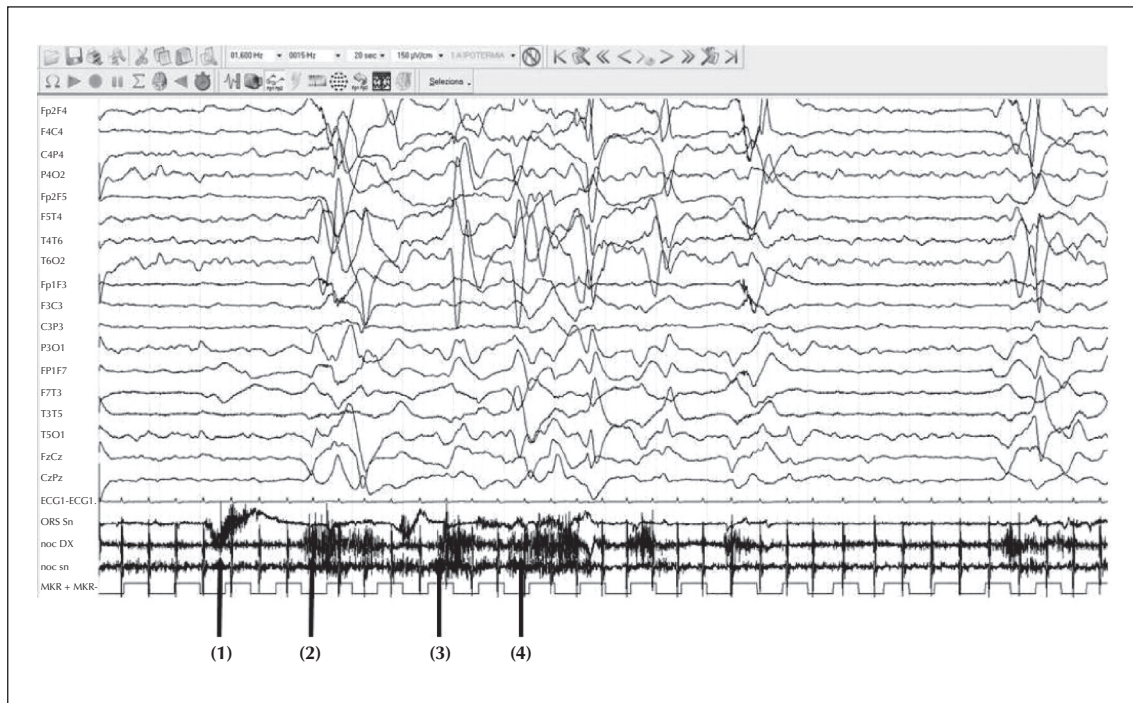


Figure 1. Scalp EEG recording of Patient 10 during dyskinetic movements of the face and mouth (see table 1 and video sequence 3). Arrows indicate clinical events (dyskinesias) registered by superficial muscle electrodes: left *orbicularis oculi* muscle (1) and right nuchal muscles (2, 3 and 4). At (1), no changes in EEG trace were recorded; at (2), (3) and (4), each contraction was followed by artefact without any epileptic discharge.

and fifth minute. The neonatal period was normal. Seizures started at the age of 4 months with isolated and clustered epileptic spasms, described as flexion of the body and adduction of extremities. The EEG recording showed a typical pattern of suppression-burst. General blood investigations, as well as metabolic examinations of blood, urine, and CSF, did not reveal any abnormality. MRI was interpreted as normal. The patient showed motor and cognitive delay. Administration of ACTH depot IM was started at 0.1 mg every day for two weeks with cessation of epileptic spasms and appearance of brief and isolated tonic generalised or focal (left) seizures, with multifocal epileptic discharges on EEG. However, ACTH therapy was suspended due to the onset of diarrhoea and electrolyte disturbances. Phenobarbital, and subsequently levetiracetam, were ineffective in controlling seizures. Carbamazepine was partially effective, with persisting rare tonic seizures and a multifocal pattern of epileptic discharges on EEG. After one month, the patient presented with clustered epileptic spasms and EEG showed again hypsarrhythmia. A new treatment cycle with ACTH depot was started. After the third administration of ACTH, the spasms ceased and EEG did not reveal epileptic abnormalities, however, the child manifested stereotyped hyperkinesias, in particular, of the facial region (oral-buccal) and head. The video-EEG recording did not show any ictal correlation (figure 1).

Abnormal movements were interpreted as dyskinesias and ACTH treatment was continued during the subsequent month as scheduled. Dyskinesias persisted for one month, after which they became less frequent and then disappeared. The neurodevelopmental delay increased with worsening of epilepsy and EEG findings, however, at a follow-up visit at the age of 10 months, the child presented with a significant delay of motor milestones, as well as cognitive impairment.

Discussion

In this retrospective analysis, we describe 10 patients who developed stereotyped dyskinesias with hormonal treatment for West syndrome. Two patients also had sustained contraction of neck extensors and one had torticollis.

Despite their serious side effects, steroids remain a highly effective treatment for children with West syndrome of different aetiologies, other than tuberous sclerosis complex (Chiron *et al.*, 1997). With regards to dosage and duration of hormonal therapy, there is no general consensus (Haga *et al.*, 1992; Hrachovy *et al.*, 1994). Although Baram *et al.* (1996) emphasizes the use of high doses of ACTH versus prednisolone, this drug is not available for most countries with limited resources (Azam *et al.*, 2005).

The public internet database, Pubmed, was searched using the four MeSH terms, steroids, ACTH, adverse effects, and movement disorders, with no results. All patients of our series received different doses and formulations of steroids, independent of the aetiology of West syndrome.

Hyperkinetic movements may often be due to improper modulation of the basal ganglia by the subthalamic nucleus. In many cases, the excitatory output of the subthalamic nucleus is reduced, leading to a reduced inhibitory outflow of the basal ganglia. Without the normal restraining influence of the basal ganglia, upper motor neurons of the circuit tend to become more readily activated by inappropriate signals, resulting in the characteristic abnormal movements (Holtbernd and Eidelberg, 2012). Hyperkinesia usually occurs when dopamine receptors, and norepinephrine receptors to a lesser extent, within the cortex and the brainstem, are more sensitive to dopamine, or when the dopaminergic receptors/neurons are hyperactive. In addition, for some specific dyskinesias (L-DOPA-induced dyskinesia), growing evidence suggests that, following dopamine cell loss, serotonin neurons acting as surrogates for dopaminergic synapses take up L-DOPA, convert it to dopamine, and release it in an unregulated fashion, thus precipitating dyskinesia (Bishop *et al.*, 2012).

The precise mode of action of steroids in infantile spasms is not well understood. ACTH may reduce neuronal excitability in infantile spasms by two mechanisms: 1) induction of steroid release; and 2) direct, steroid-independent action on melanocortin receptors. Additionally, suppression of corticotropin-releasing hormone (CRH), an excitatory neuropeptide, by ACTH/steroids, has been proposed as another mechanism of action for ACTH treatment of infantile spasms (Baram, 1993). None of these mechanisms, however, appears to be implemented in the development of hyperkinetic behaviour observed in our patients.

Increasing evidence suggests a genetic origin for many epilepsy and dyskinesia syndromes (Blumkin *et al.*, 2012). An association between spasms and abnormal movements is well known in genetic encephalopathies caused by mutations of different genes, e.g. in the gene encoding syntaxin binding protein 1 (*STXBPT*) or the Aristaless-related homeobox (*ARX*) gene. The coexistence of spasms and abnormal movements may suggest involvement of similar mechanisms. The basal ganglia are rich in GABAergic interneurons, the developmental fate of which is known to be influenced by *ARX* (Stromme *et al.*, 2002). In this situation, one can imagine that steroids may target “weak” points in neuronal circuitry.

From a purely clinical point of view, it should be underlined that caregivers often misinterpret dyskinesias as epileptic spasms. Dyskinesias are recognisable and distinguishable due to the fact that they are continuous movements and do not cluster, as well as the absence of EEG correlates. However, the pathophysiology of steroid-induced dyskinesia in our patients with infantile spasms remains unknown.

Limitations in aetiological investigation limit the speculation about possible “triggering” factors which may account for the occurrence of dyskinesias. Nevertheless, it appears that a putative dyskinetic effect of steroids may stem from the electroclinical syndrome rather than from the underlying aetiology. Thus, we speculate that epileptic spasms appearing within a critical time window in infancy, correlating to marked epileptic activity represented by hypsarrhythmia and most probably originating from an epileptogenic network with the basal ganglia and brainstem, play a leading, even triggering, role in the development of dyskinesias. Our hypothesis is indirectly confirmed by a recent study by Fong *et al.* (2013). Indeed, in a case review, the authors concluded that it is more plausible that an electroclinical syndrome sustaining infantile spasms may generate dyskinesias, despite treatment with vigabatrin. Furthermore, it should be noted that in the same series of cases, 7 of 8 patients with dyskinesias received hormonal therapy. In support of this speculation, motor side effects of steroids have not been reported in other neurological and immune-mediated diseases. It is possible that diverse aetiologies of West syndrome activate similar neuronal circuits, facilitating/uncovering this effect of steroids. The involvement of brain stem structures and putamen in the origin of infantile spasms has been suggested in animal and human studies, including fMRI and PET analysis. It is also not known whether this effect of steroids is age-dependent.

Hyperkinesia can be caused by a large number of different conditions, including iatrogenic pathophysiologicals. Most information regarding drug-induced hyperkinetic disorders is derived from case reports and anecdotes, rather than controlled clinical trials. Among drug-induced dyskinesias, the following groups of drugs are most commonly listed: antipsychotics, dopaminergics, antiepileptics, antiemetics, antidepressants, chemotherapeutic agents, stimulants, and opioids. There are some specific characteristic patterns of drug-induced dyskinesias; for example, limb dyskinesia following methylphenidate administration is a commonly reported side effect (Yilmaz *et al.*, 2013). Although clinical manifestations of neuroleptic-induced motor side effects can be diverse, they usually affect the head and neck (Kitamura *et al.*, 2002). In our patients, we observed more frequent involvement

of facial musculature, while limb hyperkinesias were less constant. Continuous contractions of lateral and medial pterygoid muscles and temporalis and masseter muscles resulted in repetitive opening and closure of the mouth, whereas periodic contractions in ocular muscles led to occurrence of squint. A distinctive pattern of movements in some neurological diseases may be useful for diagnosis and prompt appropriate treatment. Abnormal movements with predilection of the mouth and face are described in many cases of ovarian teratoma-associated encephalitis (OTE) (Kleinig, 2008). Our cases share some similarities with OTE-associated abnormal movements as they also showed prominent facial involvement. The limited number of our observations, however, does not allow us to consider this clinical appearance to be distinctive for steroid-induced dyskinesias. Further research with larger numbers of subjects are needed to verify these findings. Involuntary movements can also appear before and after initiation of vitamin B12 treatment; in the latter case, mainly as a combination of tremor and myoclonus (Zanus, 2012). Potential confusion may occur in characterising movements which occur after treatment of epileptic status (e.g. oro-facial dyskinesias during sedative medication withdrawal). Typically, these manifestations occur within 24 hours of drug discontinuation and include visual and auditory hallucinations, language impairments, inappropriate laughter, and facial grimacing. More complex choreo-athetotic and dyskinetic movements, including repetitive tongue thrusting, chewing movements, and stereotyped movements of the extremities have also been reported, and have been documented following childhood cardiac surgery (Epstein, 2007; Gherpelli, 1998).

We observed discontinuation of hypersarhythmia in all patients. Based on this, we cannot exclude that drug-induced "forced normalisation" of epileptiform activity may activate different pathological pathways in the brain, leading to other abnormal clinical patterns, analogous to the development of psychosis after abrupt drug-induced discontinuation of seizures. Several limitations should be kept in mind when interpreting our results, including the retrospective design, the small number of patients, as well as the lack of defined aetiology of West syndrome in some patients. Although the pathophysiological basis of infantile spasms has remained elusive, this novel observation provides new clues that may support the development of an animal model and more targeted therapy for this severe epileptic encephalopathy. □

Acknowledgements and disclosures.

The authors would like to thank all patients, families, and colleagues who contributed to our study.

The authors have no conflict of interests to declare.

Legends for video sequences

Movement disorders observed in patients receiving ACTH therapy.

Video sequence 1

Home video sequence of Patient 9 (see table 1 for clinical details) presenting with involuntary movements of the arms and legs with a prevalence on the left side.

Video sequence 2

Patient 10 (see table 1 for clinical details) presenting with subcontinuous dyskinesias involving both arms (shoulders) and the oro-facial region.

Video sequence 3

Continuous facial dyskinesias, in particular of the mouth with tongue protrusion, of Patient 10. Dyskinesias did not cease with head immobilisation.

Key words for video research on www.epilepticdisorders.com

Syndrome: West syndrome

Etiology: AED aggravation

Phenomenology: non epileptic paroxysmal event; dyskinesias (non epileptic)

Localization: not applicable

References

- Azam M, Bhatti N, Krishin J. Use of ACTH and prednisolone in infantile spasms: experience from a developing country. *Seizure* 2005; 14: 552-6.
- Baram TZ. Pathophysiology of massive infantile spasms: perspective on the putative role of the brain adrenal axis. *Ann Neurology* 1993; 33: 231-6.
- Baram TZ, Mitchell WG, Tournay A, et al. High-dose corticotropin (acth) versus prednisone for infantile spasms: a prospective, randomized, blinded study. *Pediatrics* 1996; 97: 375-9.
- Berg AT, Berkovic SF, Brodie MJ, et al. Revised terminology and concepts for organization of seizures and epilepsies: report of the ILAE Commission on Classification and Terminology, 2005-2009. *Epilepsia* 2010; 51: 676-85.
- Bishop C, George JA, Buchta W, et al. Serotonin transporter inhibition attenuates I-DOPA-induced dyskinesia without compromising I-DOPA efficacy in hemi-parkinsonian rats. *Eur J Neurosci* 2012; 36: 2839-48.
- Blumkin L, Suls A, Deconinck T, et al. Neonatal seizures associated with a severe neonatal myoclonus like dyskinesia due to a familial KCNQ2 gene mutation. *Eur J Paediatr Neurol* 2012; 16: 356-60.
- Chiron C, Dumas C, Jambaquè I, Mumford J, Dulac O. Randomized trial comparing vigabatrin and hydrocortisone

in infantile spasms due to tuberous sclerosis. *Epilepsy Res* 1997; 26: 389-95.

Dill P, Datta AN, Weber P, Schneider J. Are vigabatrin-induced T2 hyperintensities in cranial MRI associated with acute encephalopathy and extrapyramidal symptoms? *Eur J Paediatr Neurol* 2013; 17: 311-5.

Epstein D. Orofacial automatisms induced by acute withdrawal from high-dose midazolam mimicking nonconvulsive status epilepticus in a child. *Mov Disord* 2007; 22: 712-5.

Fong CY, Osborne JP, Edwards SW, et al. An investigation into the relationship between vigabatrin, movement disorders, and brain magnetic resonance imaging abnormalities in children with infantile spasms. *Dev Med Child Neurol* 2013; 55: 862-7.

Gherpelli JL. Choreoathetosis after cardiac surgery with hypothermia and extracorporeal circulation. *Pediatr Neurol* 1998; 19: 113-8.

Haga Y, Watanabe K, Negoro T, et al. Optimal ACTH dosage for treating West syndrome. *Jpn J Psychiatry Neurol* 1992; 46: 432-4.

Holtbernd F, Eidelberg D. Functional brain networks in movement disorders: recent advances. *Curr Opin Neurol* 2012; 25: 392-401.

Hrachovy RA, Frost Jr. JD, Glaze DG. High-dose, long-duration versus low-dose, short-duration corticotropin therapy for infantile spasms. *J Pediatr* 1994; 124: 803-6.

Kitamura K, Yanazawa M, Sugiyama N, et al. Mutation of ARX causes abnormal development of forebrain and testes in mice and X-linked lissencephaly with abnormal genitalia in humans. *Nat Genet* 2002; 32: 359-69.

Kleinig TJ. The distinctive movement disorder in ovarian teratoma-associated encephalitis. *Mov Disord* 2008; 23: 1256-61.

Paciorkowski AR, Thio LL, Dobyss WB. A genetic and biologic classification of infantile spasms. *Pediatr Neurol* 2011; 45: 355-67.

Stromme P, Mangelsdorf ME, Scheffer IE, Gecz J. Infantile spasms, dystonia, and other X-linked phenotypes caused by mutations in Aristaless related homeobox gene, ARX. *Brain Dev* 2002; 24: 266-8.

Yilmaz AE, Donmez A, Orun E, et al. Methylphenidate-induced acute orofacial and extremity dyskinesia. *J Child Neurol* 2013; 28: 781-3.

Zanus C. Involuntary movements after correction of vitamin B12 deficiency: a video-case report. *Epileptic Disord* 2012; 14: 174-80. doi: 10.1684/epd.2012.0507.