

High-level visual manifestations of epileptic seizures originating from the medial parietal cortex

Shrita Pendekanti, Sori Baek, Yagmur Basak Kilinc, Josef Parvizi

Stanford University - Neurology, Stanford, California, USA

Received November 21, 2017; Accepted April 17, 2018

ABSTRACT – We describe the case of a patient with well-localized focal seizures originating from the medial parietal cortex. Seizures originated from area 7m, and findings revealed clear visuospatial semiological signs that may be used clinically to help diagnose similar cases of seizures in non-lesional patients.

Key words: visual manifestation, medial parietal cortex, non-lesional, precuneus, visuo-spatial processing

The posteromedial cortex (PMC) is a heterogenous structure comprised of the posterior cingulate gyrus (Brodmann Areas 23a, b, and c), medial parietal cortex (BA 7), retrosplenial cortex (BA 29, 30), and transitional cortical area (BA 31). New information about PMC seizures is crucial because the anatomical location of the PMC within the medial wall of the brain makes it difficult to study. For instance, the deep interhemispheric position of the PMC makes scalp EEG an insufficient recording tool for detecting focal ictal manifestations (Alkawadri *et al.*, 2013; Enatsu *et al.*, 2014; Doležalova *et al.*, 2017). Further complicating the diagnostic process, the numerous connections of the PMC can produce seizures that pathologically and electrocorticographically resemble epilepsy from other regions,

leading to clinical phenomena such as pseudo-temporal or pseudo-frontal epilepsy (Alkawadri *et al.*, 2013; Enatsu *et al.*, 2014; Doležalova *et al.*, 2017).

Bartolomei *et al.* (2011) specifically evidences BA7 as an area of maximal “epileptogenicity”, highlighting the uniquely extensive connectivity of this region. Still, amongst the varying semiologies of parietal epilepsy resulting from this extensive connection, the authors identified vestibular symptoms as the most common seizure aura, supporting the findings from our case. Literature on PMC epilepsy has clarified certain features of the general area. For instance, Doležalova *et al.* (2017) described motor semiology of posterior cingulate (PCC) epilepsy, recording bilateral tonic seizures and hypermotor seizures

Correspondence:

Josef Parvizi
MD PhD
Department of Neurology and
Neurological Sciences,
Stanford University,
Stanford 94305, USA
<parvizi@stanford.edu>

in four of seven PCC epilepsy patients. Umeoka *et al.* (2007) reported a patient with a left precuneate lesion that manifested with a bilateral symmetric tonic posture, resulting from propagation from the lesion to the supplementary motor area. Alkawadri *et al.* (2013) reported auras of falling in PCC patients, indicating PCC involvement in the motor network. Harroud *et al.* (2017) reported that seizures in the PMC produce symptoms of visual distortion and body displacement, in line with the findings of our case, as well as other symptoms, including falling, dizziness, general automatisms, and eye deviation, supporting the literature linking the precuneal region with vestibular functions (Dieterich *et al.*, 2003). Mailo and Tang-Wai (2015) reported a patient with precuneal seizures with an urge to turn left or distorted vision during seizure episodes. While earlier reports of PMC seizures have offered insight into the semiology of seizures originating from this region of the brain, several of these reports have used the terms precuneus and PMC interchangeably, while others have altogether reported precuneal seizures under the broader lens of parietal cortex epilepsy (Salanova *et al.*, 1995; Kim *et al.*, 2004; Ristic *et al.*, 2012; Ye *et al.*, 2012).

The problem with precuneal studies is that, till now, anatomical ambiguity has limited our understanding of specific subregions within the PMC and the exact semiology related to each different area, especially given that the precuneus is highly integrated and allows for seizure propagation (Umeoka *et al.*, 2007). Here, we present the case of a patient with an identifiable lesion in the right medial parietal region, most likely area 7m. The descriptions of the patient's seizures may shed light on the clinical signs and symptoms that can be used as a guide to help diagnose similar cases of seizures in non-lesional patients. The patient's symptoms ended after removal of the lesion, and she has remained seizure-free without medication to date.

Case study

The reported patient was a 55-year-old, right-handed woman with high intellectual function (with a PhD in Economics) at the time of her seizure workup. Her prowess in articulating her seizure experience helped greatly in characterizing the experiential phenomena that she experienced during her seizures. Per report, the patient first began experiencing symptoms in April 2006 in the form of severe migraines. While an MRI scan revealed a malformation in the right side of the brain, her migraine specialist claimed no association between the lesion and her migraines. Nine years later, she experienced her first seizure episode. In November 2015, she experienced a series of seizures characterized by an inconsistency between what she

was seeing and what she was experiencing subjectively in the left side of the space around her, and came to the emergency room three days later. In regards to first noticing her morbidity, she described suddenly perceiving a void on her left where she knew the corner of the kitchen counter to be, and realizing that she was having trouble locating her position in space.

When asked to describe her episodes, the patient reported her impairment as being able to know "intellectually and visually" when a person or object is near, but sensing otherwise. She said this created a tension between her sensation and cognition. She further detailed a gap in her left visual field that was "constantly opening up", forcing her to rationalize her position in space rather than rely on sensory input. Although uncertain for a while, the patient grew assured in the fact that this was not a visual issue because even with her eyes closed, she would struggle to locate her place in a room. She used an analogy of a mathematical grid to describe her predicament: "*Take it from (a) mathematical (sense), you know. You have the room here, you would have an axis here where I was... and there would be almost like a rotation on the left, where the space, suddenly instead of being just this room, was expanded on my left*". The patient explained the demand for greater attention to her left side due to this impairment. She described this sensation of shifted visual attention to the left as feeling the "physical particles" of a being or object situated on her right side as deceptively coming from the left. The patient reported a need to use nearby objects on her right side to help her navigate through space during seizure episodes. She emphasized that her right side became her "safe space, because the left could not be".

Employing the patient's analogy of a mathematical grid, we report that the patient's visual field shifted not only to the left across the x-plane but could also shift back along the y-axis during the seizures. For example, she recounted experiencing a seizure in the car while her husband was driving. Although she knew intellectually that he was seated to her left, she felt his presence coming from behind. The patient shared that these episodes progressively occurred in increasing frequency over the course of the weekend. However, as a testament to her high-functioning cognitive state, the patient stated that her sense-of-self had in no way been distorted.

While the patient did not have a neuropsychological evaluation, routine neurological evaluation did not reveal any visual field defect. The patient was alert, and oriented to place, date, and person. Attention was intact. Language flow, content, repetition, prosody, and comprehension were normal. The patient could remember current events. There was no apraxia and visual fields were full. Diplopia was not present.

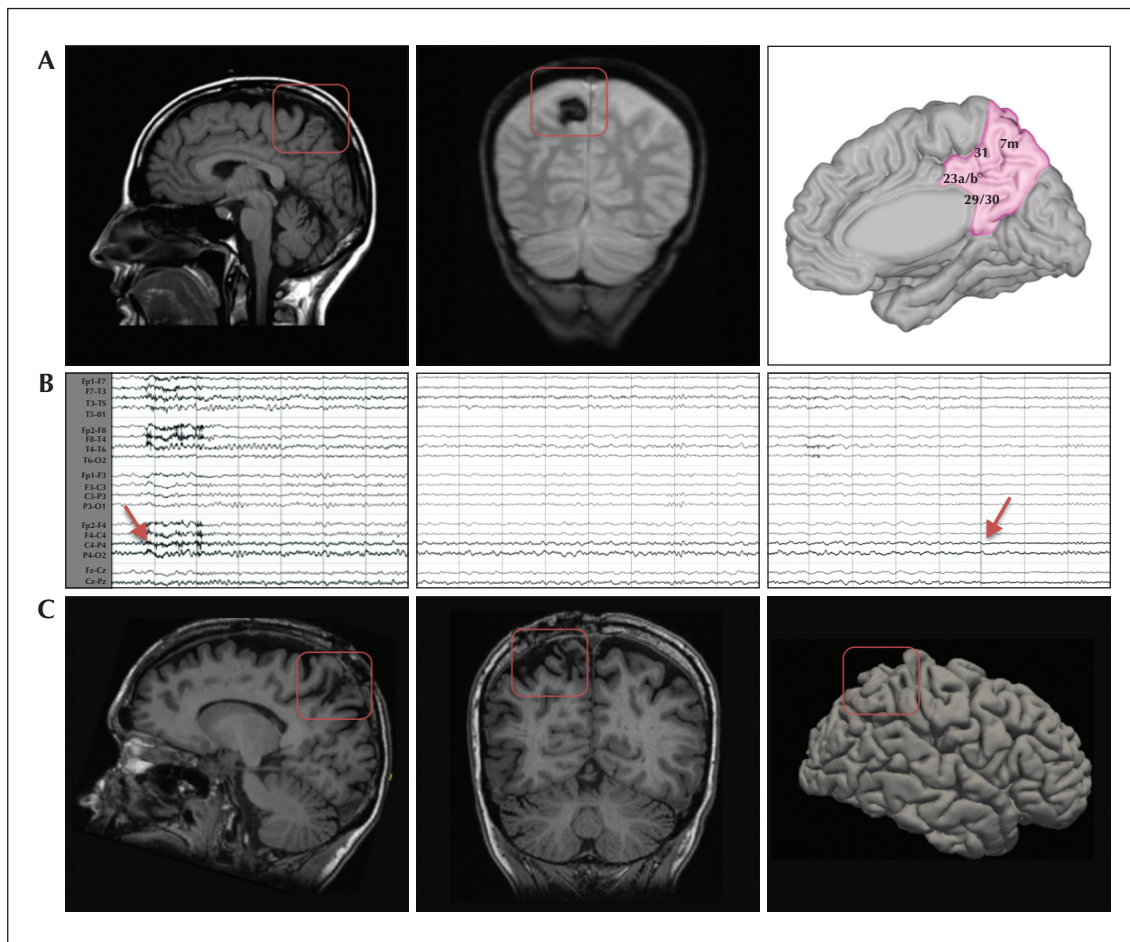


Figure 1. (A) Sagittal view of the T1-weighted MRI scan (left) and coronal view of the gradient-echo MRI scan (centre) showing the cavernous malformation in the right precuneus region. The sagittal view of the MNI space is shown with the PMC region, highlighted in pink (right). (B) EEG graph showing the onset (left), progression (centre), and end (right) of seizure activity in the precuneus region recorded under a sensitivity of 7 μ V, time constant of 0.1 seconds, and high filter of 15 Hz, over a time period of 7-8 seconds. The time at onset (red arrow on the left) and offset (red arrow on the right) is denoted on the precuneal channels (bold lines). (C) Sagittal (left) and coronal (centre) view of the T1-weighted MRI scan showing the patient's brain after resection. The lateral view of the reconstructed 3D rendering of the MR scan in 2018 is also shown on the right.

Gaze was midline at rest. Gait was normal for pace, base, swing, posture, and balance. After the weekend, a stat EEG revealed multiple on-going focal seizures originating from the right posterior quadrant where she had a known lesion. EEG during wakefulness and sleep captured six brief (less than 30 seconds) focal right parieto-occipital seizures, frequent right posterior quadrant slowing, and right parieto-occipital epileptiform sharp waves.

The patient underwent video-EEG monitoring using the standard international system with 10-20 electrode placement. The recording showed continuous, symmetric, variable and reactive background activity with overall normal voltage. Frequent polymorphic delta-theta slowing was seen over the right posterior

quadrant. This, at times, became semi-rhythmic with occasional right posterior quadrant sharps. The patient had 10 push-button events for subjective visual symptoms. There was no clear associated motor change, but sometimes the patient appeared to pause what she was doing briefly. She was always responsive to questions and fluent with speech before and after the episodes. Electrographically, these episodes were associated with right posterior quadrant rhythmic slowing, as seen in *figure 1*.

During sleep, the patient had four brief (15-45-second) episodes, consistent with right parieto-occipital focal seizures. Electrographically, there was a build-up of rhythmic, sharply contoured, theta-delta slowing that started in the right posterior quadrant and seemed

to evolve in frequency and space to other parts of the right hemisphere before subtly subsiding. Clinically, there was no clear correlate as the patient was sleeping. The patient received antiepileptic medication and underwent surgical resection of her lesion in January 2016. Upon surgical treatment, her symptoms disappeared entirely even with tapering of anticonvulsants. She was taken off levetiracetam in August, 2016. Her repeat EEG did not reveal any epileptiform abnormalities.

Discussion

This study reports the visuospatial manifestations of a seizure arising from medial parietal area 7m. While the association of the precuneus and spatial perception is well-reported, no other study has yet localized a PMC seizure to an area as specific as 7m. To be precise, we understand that the seizures themselves do not originate within the vascular lesion, but rather the cortical tissue surrounding the lesion which is contained in area 7m.

Our findings highlight area 7m as intimately related to visuospatial processing, but we acknowledge that our conclusion is based on observations in a single subject. Another limitation of our study is that the subject's auras were recorded only verbally, without precisely timed push-button events, as EEG was conducted using a portable machine.

In keeping with our findings is data from direct cortical electrical stimulation of the medial parietal region. Some stimulations in this area have been associated with visual impairments and vertigo, further emphasizing the role of the precuneus in integrating visual information and balance (Balestrini *et al.*, 2015). Additionally, findings from the greater parietal lobe area verify associations between this region and visual disturbances, induced urges to move, and vestibular sensations (Selimbeyoglu and Parvizi, 2010).

Due to the deep anatomical location of the precuneus, it is often difficult to precisely describe precuneal seizures. However, the non-invasive EEG recordings and clinical success of the lesionectomy performed in this study prove especially beneficial for the continued research of the PMC area. □

Disclosures.

None of the authors have any conflict of interest to declare.

References

- Alkawadri R, So NK, Van Ness PC, Alexopoulos AV. Cingulate epilepsy: report of 3 electroclinical subtypes with surgical outcomes. *Jama Neuro* 2013;70:995-1002.
- Balestrini S, Francione S, Mai R, *et al.* Multimodal responses induced by cortical stimulation of the parietal lobe: a stereo-electroencephalography study. *Brain* 2015;138:2596-607.
- Bartolomei F, Gavaret M, Hewett R, *et al.* Neural networks underlying parietal lobe seizures: a quantified study from intracerebral recordings. *Epilepsy Res* 2011;93:164-76.
- Dieterich M, Bense S, Lutz S, *et al.* Dominance for vestibular cortical function in the non-dominant hemisphere. *Cereb Cortex* 2003;13:994-1007.
- Doležalova I, Brázdil M, Kahane P. Temporal lobe epilepsy? Things are not always what they seem. *Epileptic Disord* 2017;19:59-66.
- Enatsu R, Bulacio J, Nair DR, Bingaman W, Najm I, Gonzalez-Martinez J. Posterior cingulate epilepsy: clinical and neurophysiological analysis. *J Neurol Neurosurg Psychiatry* 2014;85:44-50.
- Harroud A, Boucher O, Tran TPY, *et al.* Precuneal epilepsy: clinical features and surgical outcome. *Epilepsy & Behav* 2017;73:77-82.
- Kim DW, Lee SK, Yun CH, *et al.* Parietal lobe epilepsy: the semiology, yield of diagnostic workup, and surgical outcome. *Epilepsia* 2004;45:641-49.
- Mailo J, Tang-Wai R. Insight into the precuneus: a novel seizure semiology in a child with epilepsy arising from the right posterior precuneus. *Epileptic Disord* 2015;17:321-7.
- Ristic AJ, Alexopoulos AV, So N, Wong C, Najm IM. Parietal lobe epilepsy: the great imitator among focal epilepsies. *Epileptic Disord* 2012;14:22-31.
- Salanova V, Andermann F, Rasmussen T, Olivier A, Quesney LF. Parietal lobe epilepsy. Clinical manifestations and outcome in 82 patients treated surgically between 1929 and 1988. *Brain* 1995;118:607-27.
- Selimbeyoglu A, Parvizi J. Electrical stimulation of the human brain: perceptual and behavioral phenomena reported in the old and new literature. *Front Hum Neuroscience* 2010;31:46.
- Umeoka S, Baba K, Terada K, *et al.* Bilateral symmetric tonic posturing suggesting propagation to the supplementary motor area in a patient with precuneate cortical dysplasia. *Epileptic Disord* 2007;9:443-8.
- Ye BS, Cho Y-J, Jang SH, Lee MK, Lee BI, Heo K. The localizing and lateralizing value of auras in lesional partial epilepsy patients. *Yonsei Med J* 2012;53:477-85.