

# Ipsilateral head deviation related to orbito-frontal and fronto-polar seizures

Sylvain Rheims<sup>1</sup>, Geneviève Demarquay<sup>1</sup>, Marc Guénot<sup>2</sup>, Marc Sindou<sup>2</sup>, François Mauguière<sup>1</sup>, Philippe Ryvlin<sup>1</sup>

<sup>1</sup> Department of Functional Neurology and Epileptology,

<sup>2</sup> Department of Neurosurgery, Neurological Hospital Pierre Wertheimer, Lyon, France

Received December 3, 2004; Accepted March 15, 2005

**ABSTRACT** – The localizing and lateralizing values of eye and head ictal deviations during frontal lobe seizures are still matters of debate. In particular, no specific data regarding the origin of ipsilateral head turning in frontal lobe seizures are available. We report a patient with frontal lobe seizures associated with reproducible, early, ipsilateral head deviation, where imaging and video-stereo-electroencephalography data, as well as surgical outcome, demonstrated the fronto-polar and orbito-frontal origin of the epileptic discharge. We conclude that early ipsilateral head deviation, in the context of frontal lobe epilepsy, raises the possibility of fronto-polar or orbito-frontal seizure onset.

*[Published with video sequences]*

**Key words:** epilepsy, version, orbito-frontal, fronto-polar, head deviation

The lateralizing value of eye and head ictal deviation has been a matter of great debate, in as much as those contralateral and ipsilateral to seizure onset might reflect the involvement of various neural networks (Jayakar *et al.* 1992, Quesney *et al.* 1992). In addition, whether ictal head deviation is ipsilateral or contralateral to the epileptogenic zone can be difficult to assess in frontal lobe epilepsy (FLE), without clear-cut lateralizing EEG or neuroimaging abnormality. The typical tonic version observed in FLE is usually contralateral to seizure onset, and appears to reflect the involvement of the frontal eye field (FEF), in particular when associated with a clonic component (McLachlan 1987, Wyllie *et al.* 1986). Ipsilateral head turning is more often observed within the course of temporal lobe seizures, but can also occur during frontal lobe seizures (Jobst *et al.* 2000, Kotagal and Arun-

kumar 1998, Ochs *et al.* 1984, Quesney *et al.* 1992). However, the localisation of frontal lobe discharges associated with ipsilateral head deviation (IHD) remains largely unknown. We report a patient with frontal lobe seizures characterised by early and reproducible IHD, where imaging and video-stereo-electroencephalography (SEEG) data, as well as surgical outcome, demonstrated the fronto-polar and orbito-frontal origin of the epileptic discharge.

## Case report

A 21-year-old, right-handed, white female had complex partial seizures since the age of 9. Her mother also suffered from partial epilepsy, symptomatic of tuberous sclerosis (TS). The patient had no extra-neurological sign of TS, and presented with normal de-



### Correspondence:

P. Ryvlin  
Department of Functional Neurology and Epileptology,  
Neurological Hospital Pierre Wertheimer,  
59, Bd Pinel,  
69003 Lyon,  
France  
Tel: (+00 33) 4 72 35 78 10  
<ryvlin@cermep.fr>

velopment. The CT scan was normal, whereas magnetic resonance imaging (MRI) displayed a circumscribed, dysplastic lesion in the left fronto-polar cortex, suggesting a minor form of TS (*figure 1*). The patient was amnesic of her seizures. Witnesses reported that she complained of a left temporo-parietal cephalgia at seizure-onset, followed by a shout and loss of awareness associated with a facial expression of fear, while the arms were crossed on the chest, and the trunk bent forward. Despite several antiepileptic drug trials, the patient suffered from weekly, complex partial seizures, with monthly secondary generalisation.

Neuropsychological and Wada tests showed an isolated attention deficit and a left hemispheric dominance for language. 18F-FDG positron emission tomography (PET) and [11C]flumazenil PET showed a focal abnormality that corresponded to the site of the MRI lesion (*figure 1*). Interictal EEG consistently demonstrated left frontal spikes and slow waves.

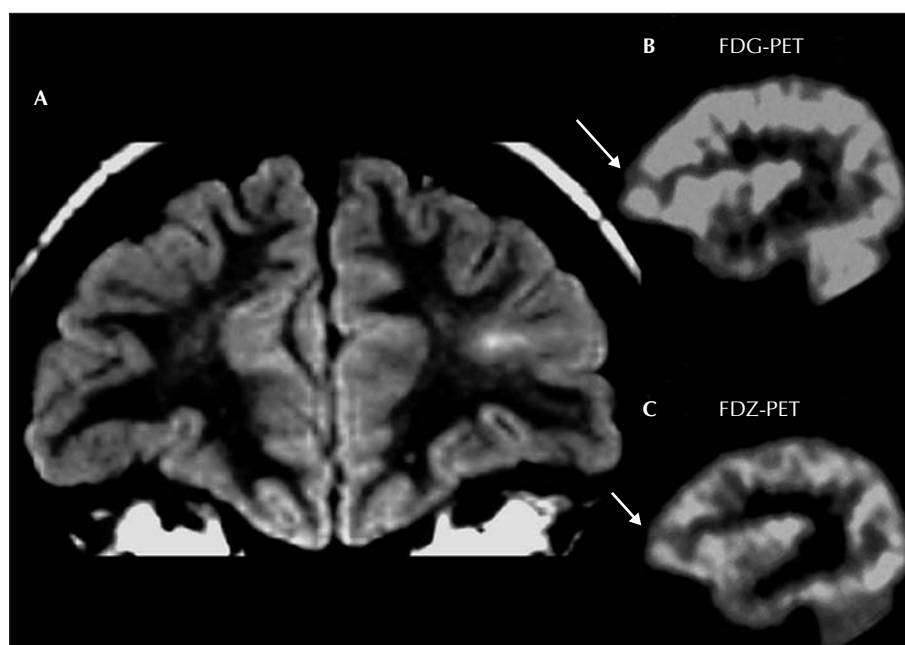
A total of twenty-seven seizures (*see video 1*) were recorded during video-EEG and video-stereoelectroencephalography (SEEG) monitoring (*figures 2, 3, 4 and 5*).

They were stereotyped and started with a sudden arrest reaction followed by a deviation of the head and eyes, oblique to the left, and downward. This was followed by facial grimacing, characterized by a lowering of the corners of the mouth, vocalisation and hypermotor activity of the legs and pelvis, associated with rocking movements of the trunk. These manifestations occurred in brief, repeti-

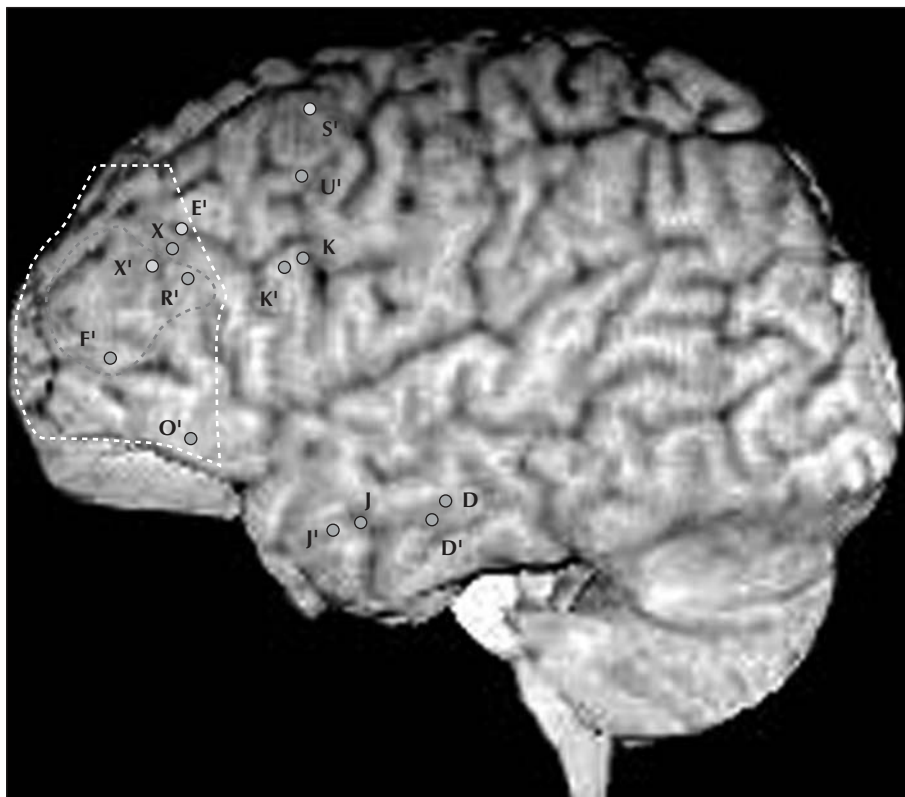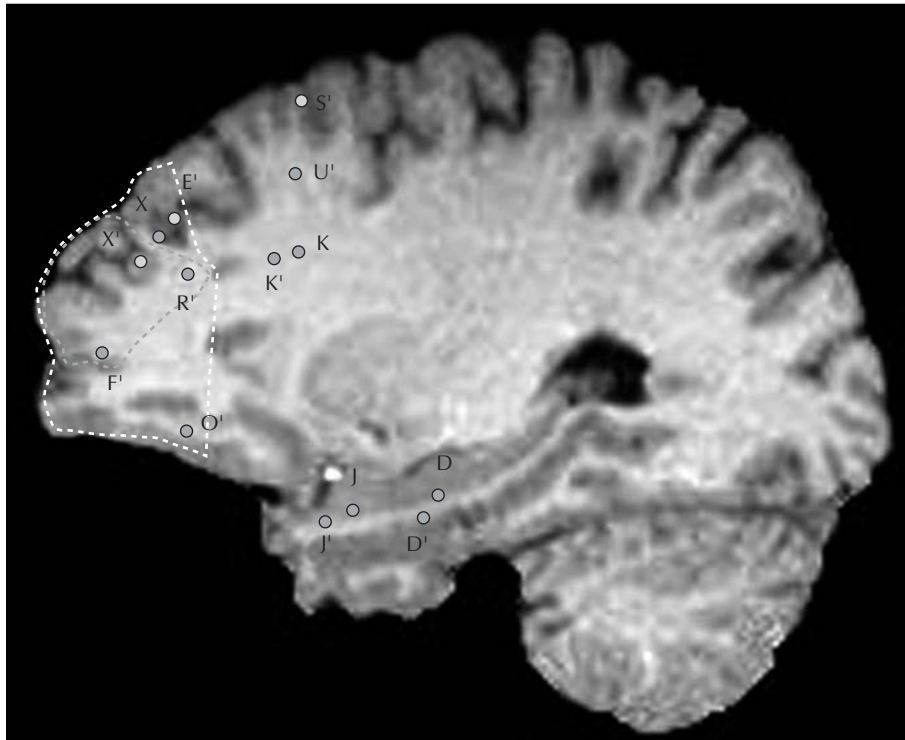
tive clusters, whereas the entire seizure lasted 30 to 40 seconds. Postictally, the patient was immediately responsive and well-orientated, but amnesic of her seizure. Ictal scalp EEG showed a left frontal, low voltage fast activity followed by a bifrontal, spike-waves discharge. Interictal SEEG recordings demonstrated a very active spike focus located in the left fronto-polar region near the MRI lesion (electrode F'). Two types of ictal discharges were recorded. The first type was characterized by a well-localized ictal SEEG onset within the left fronto-polar region (electrode F'), which then spread to the left orbito-frontal region (electrode O') (*figure 4*). Clinical signs, including IHD, appeared when the left orbito-frontal region was infused by the ictal discharge. The second type of seizure originated and predominated within the left orbito-frontal cortex, whereas a less intense ictal discharge was transiently observed over the ipsilateral fronto-polar and dorsolateral frontal regions (*figure 5*). IHD occurred during the first second of ictal onset, and continued while the SEEG discharge became restricted to the orbito-frontal region, until seizure termination. Some ictal discharges secondarily spread to the right frontal electrodes, without giving rise to additional clinical sign.

The surgical removal of the epileptogenic zone, as defined by SEEG data, included the left fronto-polar and orbito-frontal region (*figures 2 and 3*). Pathology examination confirmed the presence of a cortical dysplasia typical of those encountered in TS.

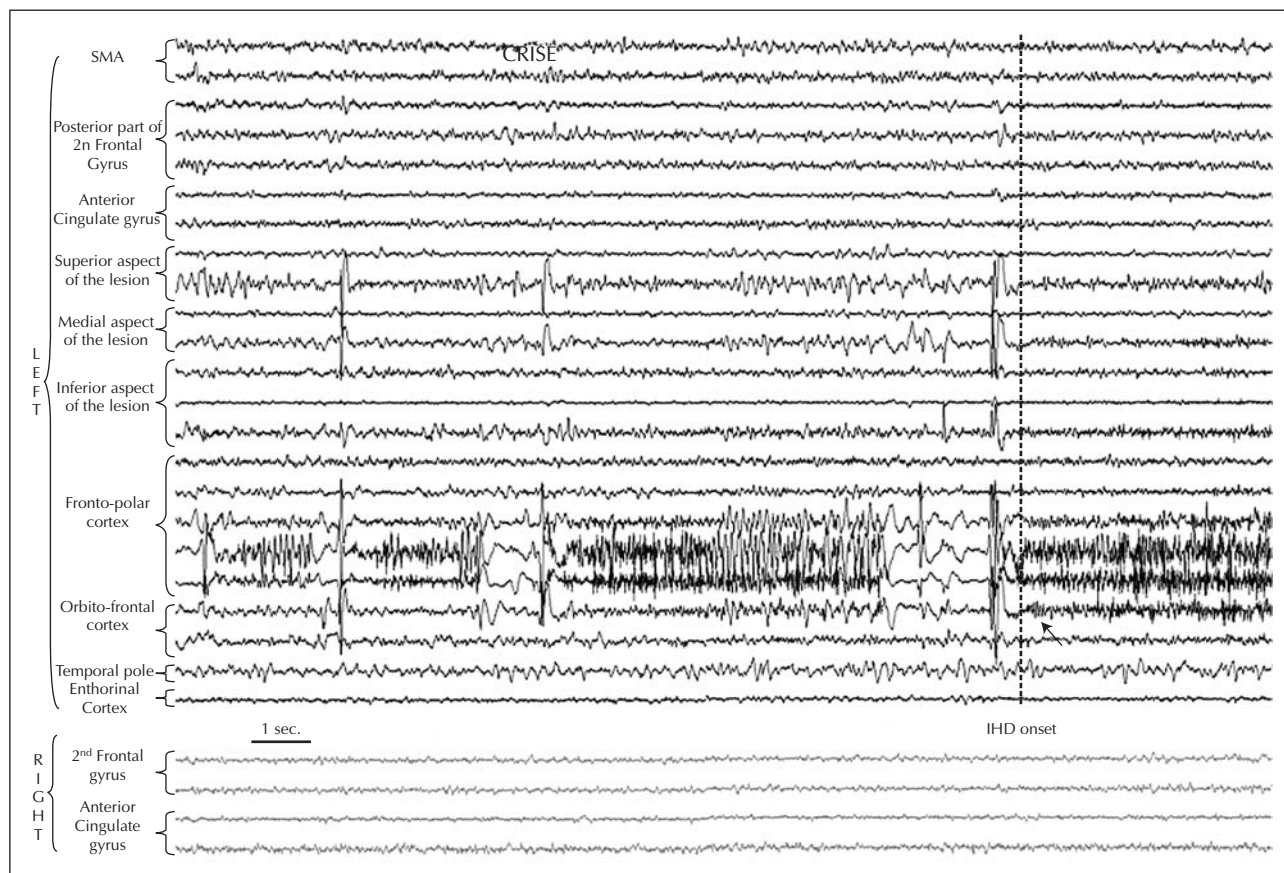
The patient has been seizure free for 2 years post-operatively, without any antiepileptic drug-treatment.



**Figure 1.** A) MRI (FLAIR sequence) displaying a circumscribed, dysplastic lesion in the left fronto-polar cortex. B and C) 18F-FDG PET and [11C]flumazenil PET showing a focal abnormality at the site of the MRI lesion.



**Figures 2 and 3.** Lateral view of the patient's brain showing the intracerebral electrodes (dots), the MRI lesion circumscribed by the dark grey line, and the borders of the surgical resection depicted by the white line.



**Figure 4.** SEEG recordings of the first seizure type showing a well localized ictal SEEG onset within the left fronto-polar region, which then spread to the left orbito-frontal region. IHD onset occurs concurrently with an intensification of the orbito-frontal ictal discharge (arrow).

Neuropsychological functions have clearly improved with no more attention deficit.

## Discussion

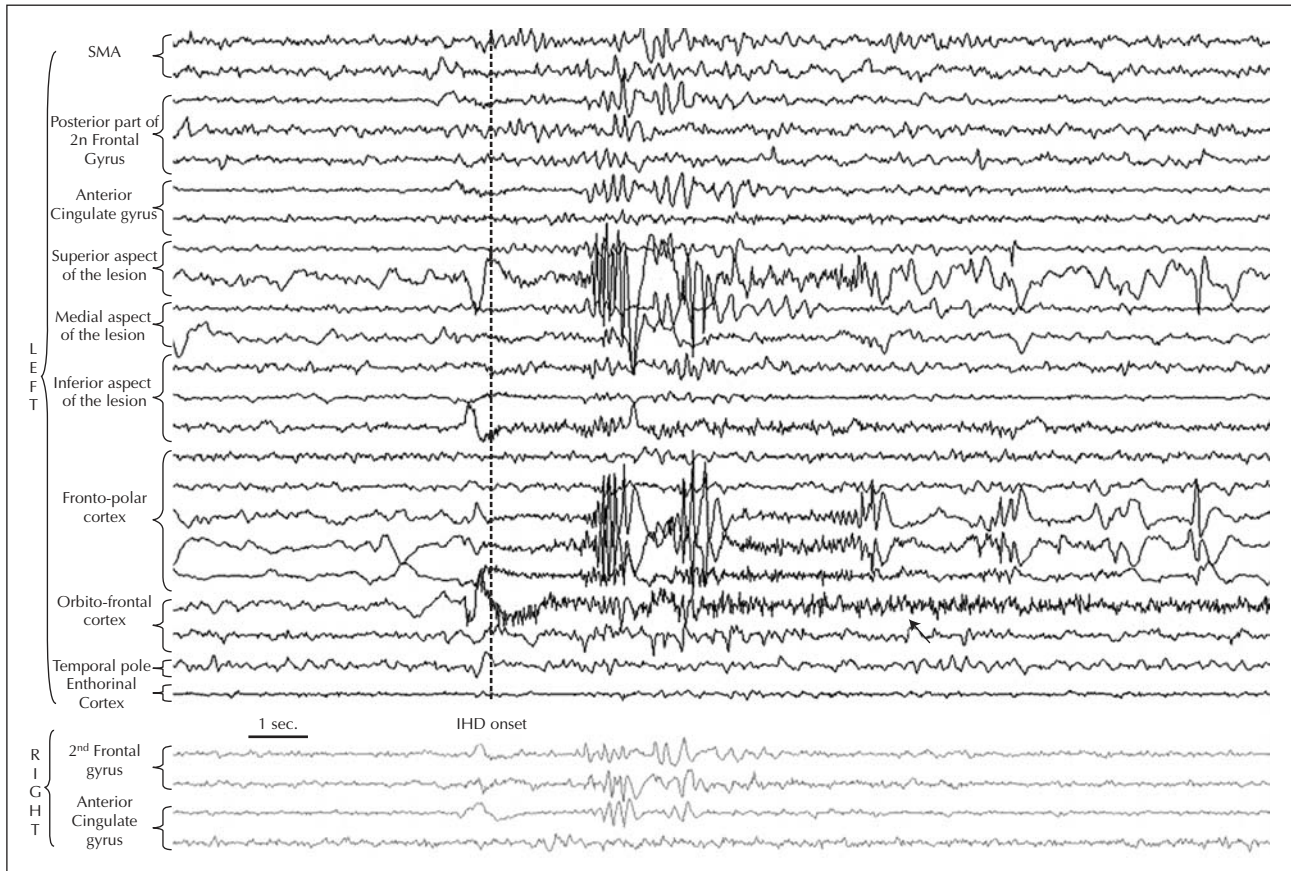
Head and eye deviations are some of the most common ictal motor manifestations in frontal lobe epilepsy, where they are observed in 21% (Manford *et al.* 1996) to 33% (Quesney *et al.* 1992) of seizures. However, their lateralizing value is still a matter of debate. Several authors have described tonic, forced, unnatural head-turning (so-called "version") in patients suffering from frontal lobe seizures whose epileptogenic zone was contralateral to the head deviation in more than 90% of cases (Mc Lachlan 1987, Wyllie *et al.* 1986). Conversely, other authors have failed to demonstrate any lateralizing significance of head-turning in FLE, most likely because they include both tonic and non-tonic head deviations (Ochs *et al.* 1984). Indeed, ipsilateral head deviation, usually non-tonic, has been reported in frontal lobe epilepsy (Jobst *et al.* 2000, Kotagal and Arunkumar 1998, Ochs *et al.* 1984, Quesney *et al.*

1992), though less frequently than in temporal lobe seizures (Fakhoury 1995, Wyllie *et al.* 1986).

More specifically, IHD was reported in frontal lobe seizures originating in the dorsolateral cortex (Jobst *et al.* 2000, Kotagal and Arunkumar 1998), as well as in the anterior frontal, fronto-polar, or orbito-frontal regions (Quesney *et al.* 1992, Chang *et al.* 1991, Jobst *et al.* 2000). Accordingly, our patient presented with very reproducible, early onset IHD associated with a left fronto-polar and orbito-frontal epileptogenic zone. Her IHD appeared to be more specifically associated with the initial or secondary involvement of the orbito-frontal cortex.

Proven cases of orbito-frontal epilepsy are scarce in the literature. Ictal manifestations associated with this form of epilepsy include hypermotor activities, olfactory or gustatory hallucinations (Ludwig *et al.* 1975, Manford *et al.* 1996), as well as IHD (Chang *et al.* 1991), but some reports indicate the lack of clinically overt signs unless adjacent frontal or temporal regions are concurrently involved (Munari *et al.* 1995, Smith *et al.* 2004).

The pathophysiological basis of IHD in FLE remains unknown, and we can only speculate on the basis of this case report and other data from the literature. A role for the



**Figure 5.** SEEG recordings of the second seizure type showing an ictal onset which predominates over the orbito-frontal cortex, but also extends towards the fronto-polar and dorsolateral regions for a few seconds. Thereafter, the ictal discharge remains localized over the orbito-frontal cortex (arrow). IHD occurs during the first second of ictal onset, and continues while the SEEG discharge becomes restricted to the orbito-frontal region, until the end of the seizure.

contralateral frontal lobe appears unlikely in our patient, based on the late and inconsistent involvement of that lobe during the ictal discharge. With the patient being amnesic of her seizures, we cannot exclude the possibility of hallucination-driven head turning, but this also seems unlikely according to the clinical characteristics of the movement observed (*i.e.* brief, repetitive head deviation with an oblique, downward direction). Neither is it suggestive of right-side neglect, in as much as only a very limited portion of the left frontal lobe was seizing at the time of the IHD. Alternatively, one might speculate on the role of the basal ganglia, as previously discussed for IHD associated with temporal lobe seizures (Fakhoury 1995). Animal studies, which have elicited IHD by stimulating the nuclei caudatus or accumbens (Svensson *et al.* 1995, Weston *et al.* 1984), as well as connections between the orbito-frontal cortex and basal ganglia (Herrero *et al.* 2002), support this hypothesis, which could not be directly tested in our patient. In conclusion, ipsilateral head deviation in frontal lobe epilepsy might suggest a fronto-polar or orbito-frontal

seizure onset. The neural network subserving this ictal sign remains to be elucidated, and might involve the basal ganglia. □

## References

- Chang CN, Ojemann LM, Ojemann GA, Lettich E. Seizures of fronto-orbital origin : a proven case. *Epilepsia* 1991; 32(4): 487-91; [Jul-Aug].
- Fakhoury T, Abou-Khalil B. Association of ipsilateral head turning and dystonia in temporal lobe seizures. *Epilepsia* 1995; 36(11): 1065-70.
- Herrero MT, Barcia C, Navarro JM. Functional anatomy of thalamus and basal ganglia. *Childs Nerv Syst* 2002; 18(8): 386-404.
- Jayakar P, Duchowny M, Resnick T, Alvarez L. Ictal head deviation : lateralizing significance of the pattern of head movement. *Neurology* 1992; 42(10): 1989-92.
- Jobst BC, Siegel AM, Thadani VM, Roberts DW, Rhodes HC, Williamson PD. Intractable seizures of frontal lobe origin : clinical characteristics, localizing signs, and results of surgery. *Epilepsia* 2000; 41(9): 1139-52.

Kotagal P, Arunkumar GS. Lateral frontal lobe seizures. *Epilepsia* 1998; 39(Suppl 4): S62-S68.

Manford M, Fish DR, Shorvon SD. An analysis of clinical seizure patterns and their localizing value in frontal and temporal lobe epilepsies. *Brain* 1996; 119(Pt 1): 17-40.

McLachlan RS. The significance of head and eye turning in seizures. *Neurology* 1987; 37(10): 1617-9.

Munari C, Tassi L, Di Leo M, et al. Video-stereo-electroencephalographic investigation of orbito-frontal cortex. Ictal electroclinical patterns. *Adv Neurol* 1995; 66: 273-95.

Ochs R, Gloor P, Quesney F, Ives J, Olivier A. Does head-turning during a seizure have lateralizing or localizing significance? *Neurology* 1984; 34(7): 884-90.

Quesney LF, Constrain M, Rasmussen T. Seizures from the dorso-lateral frontal lobe. *Adv Neurol* 1992; 57: 233-43.

Smith JR, Sillay K, Winkler P, King DW, Loring DW. Orbitofrontal epilepsy : electroclinical analysis of surgical cases and literature review. *Stereotact Funct Neurosurg* 2004; 82(1): 20-5.

Svensson A, Carlsson ML. The muscarine antagonist methscopolamine and the NMDA antagonist AP-5 injected unilaterally into the nucleus accumbens cause mice to rotate in opposite directions. *J Neural Transm Gen Sect* 1995; 101(1-3): 149-57.

Weston J, Stein JF, Greenfield SA. Ipsiversive rotation in awake rats following chronic electrical stimulation of one caudate nucleus. *Neurosci Lett* 1984; 46(3): 297-303.

Wyllie E, Luders H, Morris HH, Lesser RP, Dinner DS. The lateralizing significance of versive head and eye movements during epileptic seizures. *Neurology* 1986; 36(5): 606-11.