

Lateralized ictal dystonia of upper and lower limbs in patients with temporal lobe epilepsy

Robert Kuba, Ivana Tyrliková, Milan Brázdil, Ivan Rektor

Brno Epilepsy Centre, First Department of Neurology, St. Anne's University Hospital and Faculty of Medicine, Masaryk University, Brno, Czech Republic

Received March 5, 2009; Accepted March 18, 2010

ABSTRACT – *Purpose.* To perform a retrospective study to determine the incidence and lateralizing value of ictal dystonia in patients with temporal lobe epilepsy. *Methods.* The study included 142 patients (76 males, 66 females) with temporal lobe epilepsy, aged from 19 to 58 years with an average age of 33.1 ± 8.7 years. Overall, 454 seizures were analysed. The seizure onset zone was mesial in 112 patients (78.8%), and “non-mesial” in 30 patients (21.2%). *Results.* Ictal dystonia was present in 68 of the 142 patients (47.9%), and in 186 of 454 total seizures (40.9%). Upper limb dystonia was present in 94 seizures (50.5%) of 32 patients; hemidystonia in 84 seizures (45.2%) of 30 patients; and lower limb dystonia in eight seizures (4.3%) of six patients. For all cases, all types of ictal dystonia were contralateral to the seizure onset zone. Ictal dystonia was significantly more frequent in patients with a mesial seizure onset zone than in “non-mesial” patients (58.1% vs 7.7%; $p < 0.001$). Within the mesial group, ictal dystonia was significantly more frequent in patients with hippocampal sclerosis than in those patients with other lesions (66.1% vs 41.1%; $p = 0.023$). *Conclusion.* Ictal dystonia in temporal lobe epilepsy is a reliable lateralizing ictal sign. During almost half of the seizures studied, ictal dystonia was present in the form of hemidystonia, and isolated involvement of the lower limbs also occurred. Combined data obtained from both noninvasive and invasive EEG showed that ictal dystonia tended to occur more often in mesial onset temporal lobe epilepsy, especially when hippocampal sclerosis was the epileptogenic lesion.

Key words: temporal lobe epilepsy, ictal dystonia, lateralizing ictal sign, upper limb, lower limb, motor circuit disorder

Ictal dystonia (ID) is a well-known lateralizing ictal sign in temporal lobe epilepsy (TLE). In the literature, dystonia of the upper limbs has been almost exclusively reported. It is clear that ID has both localizing and lateralizing value in patients with TLE, and it is usually present contralateral to the seizure onset zone (Bleasel *et al.*, 1997;

Dupont *et al.*, 1999; Chou *et al.*, 2004; Kotagal *et al.*, 1989; Newton *et al.*, 1992; Yu *et al.*, 2001; Williamson *et al.*, 1998). Moreover, ID is more often present in mesial temporal lobe epilepsy (MTLE) than in neocortical temporal lobe epilepsy (NTLE), as previously reported (Dupont *et al.*, 1999; O'Brien *et al.*, 1996; Saygi *et al.*, 1994).

Correspondence:

R. Kuba
First Department of Neurology,
St. Anne's University Hospital and Faculty of
Medicine, Masaryk University,
Brno, Czech Republic
<robert.kuba@fnusa.cz>

In general, most ictal clinical symptoms which have a certain localizing or lateralizing value occur in the upper parts of the body, including the head, eyes, mouth, and the upper extremities. Ictal manifestations of the lower limbs have not been precisely investigated, probably because of camera orientation which favours the upper half of the body. Another probable reason for neglecting the lower part of the body during video-EEG recording for a majority of patients, is that the sheets or blankets obscure the legs from view (Bleasel *et al.*, 1997; Fakhoury and Abou-Khalil, 1995).

Reports of leg dystonia in the literature are scarce and often inaccurate. Where leg dystonia is mentioned in patients with TLE, it is merely reported that dystonia involves the lower limbs, but no further detailed analyses are provided (Kotagal *et al.*, 1989; Ray and Kotagal, 2005; Williamson *et al.*, 1998). A study evaluating leg behaviour in patients with TLE reported leg dystonia in 2% of all seizures (Chou *et al.*, 2004); no other studies to assess leg dystonia are reported in the literature.

The present study aimed to retrospectively determine the incidence and localization of various types of ictal dystonia, with specific reference to body segment in patients with TLE.

Materials and methods

We reviewed all patients with TLE who underwent video-EEG monitoring at the Brno Epilepsy Centre, at the First Department of Neurology of the Masaryk University Hospital, from 1998 to 2003. In total, we included 142 patients (76 males, 66 females) aged between 19 to 58 years, with an average age of 33.1 ± 8.7 years. The duration of the patients' epilepsy ranged from 2 to 34 years, with an average duration of 18.4 ± 3.9 years. All of the patients suffered from complex partial seizures, with or without secondary generalised tonic-clonic seizures.

Scalp or sphenoidal video-EEG recordings were performed using the 32-channel Brain Quick system (Micromed). Invasive EEG was performed on 38 of the 142 patients. The invasive video-EEG recording was performed using the 64-channel Brain Quick system (Micromed). Referential recordings (a reference electrode on the processus mastoideus) and special bipolar montages were used to evaluate the EEG activity. The EEG was amplified with a bandwidth of 0.4-70 Hz at a sampling rate of 128 Hz. For the invasive EEG we used the stereotactical implantation of orthogonal depth electrodes using the Bancaud-Talairach methodology (Talairach *et al.*, 1967). Of a total of 454 seizures, 76 were analysed during invasive EEG monitoring.

The seizure onset zone was mesial (MTLE) in 112 patients (78.8%) and "non-mesial" (nMLTE) in 30 (21.2%) patients. The seizure onset zone was determined based

on intracranial recording in 38 patients. In another 104 patients, the seizure onset zone was based on the congruent data obtained from magnetic resonance imaging, interictal and/or ictal HMPAO single photon emission tomography, FDG positron emission tomography (FDG-PET), neuropsychological assessment, and the evaluation of interictal and ictal scalp recording.

Patients were primarily excluded who were evaluated only by "noninvasive" methods and in whom these methods provided discordant or conflicting results. These patients were excluded regardless of the absence or presence of ID. In the group of 38 patients who were also evaluated by means of invasive EEG, the depth electrodes were placed individually based on the presumed seizure onset zone. The number of electrodes varied from 6 to 13. Both temporal lobes were evaluated in 32 patients; for six patients only one temporal lobe on the side of the presumed seizure onset zone was evaluated. The amygdala, on the side of the presumed seizure onset zone, was evaluated in 33 patients, the hippocampus and lateral temporal cortex in all 38 patients, the temporal pole in 15 patients, the temporal operculum in 22 patients, and the dorsal part of the temporal lobe on the temporo-occipital junction in 11 patients. According to the lateralization of seizure onset zone, 73 patients had left-sided TLE and 69 patients had right-sided TLE.

Of the 142 patients, 23 patients did not have surgery for their epilepsy. Of these, eight were not refractory to all antiepileptic drugs and were thus not recommended for surgery. Eight patients were not referred for surgery for various reasons (mostly due to the relationship of the seizure onset zone to the eloquent speech cortex and the high risk associated with loss of memory functions). Seven patients refused surgery.

Of the 119 patients who did have surgery for epilepsy, hippocampal sclerosis (HS) was revealed by histopathological examination in 59 patients and histopathological examination showed other kinds of lesions in 60 patients. We observed low grade glioma in 16 patients, some type of malformation of cortical development in 15 patients, both cavernoma and post-traumatic lesions in six patients, dysembryonal neuroepithelial tumour in four patients, and nonspecific gliosis in six patients. In the remaining seven patients, the histopathological investigation was either negative or not assessed.

All patients underwent either tailored lesionectomy or antero-medial temporal resection. Selective amygdalo-hippocampectomy was not performed on any patient. The effect of surgery was evaluated by Engel classification. Two years after surgery, 94 patients (79.7%) were evaluated as Engel I, 20 patients (16.8%) as Engel II or III, and five patients (4.5%) as Engel IV.

The following types of lateralized ictal dystonia were distinguished, in terms of body segment involvement:

- isolated upper limb dystonia (ULD);
- isolated lower limb dystonia (LLD) (*figure 1*);

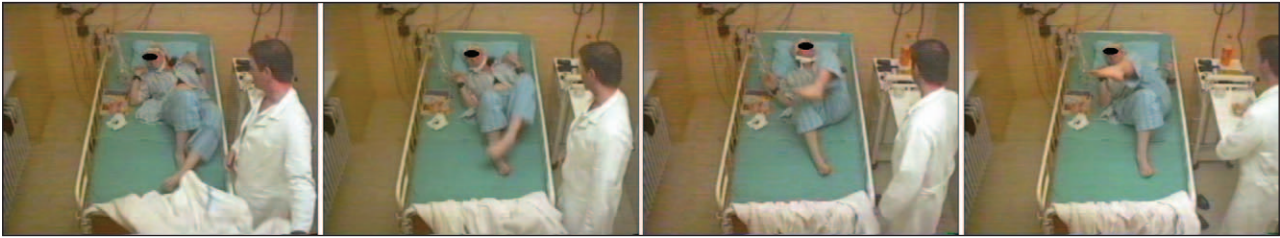

Figure 1. Lower limb dystonia in a patient with right-sided hippocampal sclerosis.

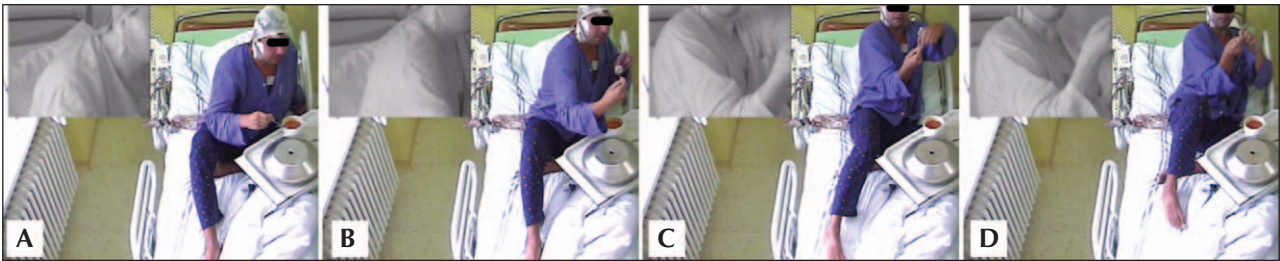


Figure 2. Upper and lower limb dystonia (hemidystonia) in a patient with cortical dysplasia of the left temporal lobe. **A)** Patient is eating during the first phase of the seizure; no dystonic posturing present. **B)** The development of right-sided hand dystonia associated with the automatisms of the left hand oriented to the right dystonic hand. **C)** Inner rotation of the right leg. **D)** Inner rotation of the right leg; flexion in the hip and knee joint.

– simultaneous upper and lower limb dystonia; hemidystonia (HED) (*figure 2*).

ULD was defined according to Kotagal's description as sustained (> 10 s), forced, unnatural posturing of an upper extremity on one side of the body. Dystonic posturing was either with flexion or extension at the elbow with a rotational component (Kotagal *et al.*, 1989). LLD was defined as sustained (> 10 s), forced, unnatural posturing of a lower extremity on one side of the body. Dystonic posturing was either with flexion or extension at the hip and knee with a rotational component (mostly pronation) at the ankle. Unnatural positioning of the lower limb described above could have been associated with external rotation at the hip and/or abduction or hyperextension of toes. HED was defined as the simultaneous occurrence of ULD and LLD. We excluded "tonic posturing", defined as sustained posturing of one upper extremity with flexion or extension at the elbow but without an element of rotation in the arm and usually, but not necessarily, with fisting of the hand (Bleasel *et al.*, 1997).

The primary goal of our study was to determine the incidence and lateralizing value of various types of ictal dystonia in the series of patients with TLE. The secondary goals were as follows:

- to determine potential differences in incidence of ictal dystonia between patients with MTLE and nMTLE;
- to determine potential differences in incidence of ictal dystonia between MTLE patients associated with HS (MTLE/HS) and MTLE patients associated with other lesions or cryptogenic cases (MTLE/LES).

Statistics

The Fischer exact test was used to analyze the significance of the incidence of ID in various subgroups of TLE. Statistical significance was considered at $p < 0.05$.

Results

During the course of the study, for each patient the number of seizures recorded ranged from one to eight (an average of 3.2 ± 1.5 seizures). For 43 out of 454 seizures (9.5%) information regarding leg movement was insufficient due to the legs being covered by a blanket making a valid assessment impossible (for 38 seizures), and insufficient camera orientation on the lower part of the body (for 5 seizures). These seizures were included in the analysis and were simply considered as seizures without LLD.

Incidence of different types of ictal dystonia

In total, ID was present in 68 of the 142 patients (47.9%) and 186 of the 454 total seizures (40.9%). In the group of patients with ID, ULD was present in 94 seizures (50.5%) of 32 patients; HED was present in 84 seizures (45.2%) of 30 patients. LLD was present in 8 seizures (4.3%) of 6 patients (*figure 3*).

In the subgroup of 38 patients who underwent invasive EEG, a total of 78 seizures were recorded. Mesial seizure onset was revealed in 25 out of 38 patients who underwent invasive EEG and non-mesial seizure onset (latero-

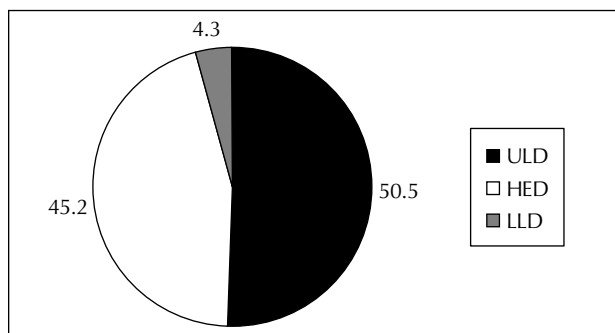


Figure 3. Incidence of various types of ID in seizures where it was present (in percentage).
 ULD: isolated upper limb dystonia; LLD: isolated lower limb dystonia; HED: simultaneous both upper and lower limb dystonia (hemidystonia).

basal temporal cortex, temporal pole) in 13 patients. Overall, ID was present in 18 of the 38 patients (47.3%) and in 38 of the 78 total seizures (48.7%). In the mesial group, ID was present in 16 of 25 patients (64%), but only two of 13 patients (15,4%) in the “non-mesial” group.

During the invasive EEG, ULD was present in 19 of 38 seizures (50%), HED was present in 18 seizures (47.3%) and LLD was present in one seizure (2.7%). ID appeared in 20 to 100% of all seizures recorded for each individual patient (average $78 \pm 28\%$). In 39 of 68 patients (57.3%), ID appeared in all recorded seizures. ID appeared at least 30 seconds after the clear-cut onset of ictal activity in depth electrodes during all seizures investigated by invasive EEG. We did not perform any further time-analysis of the appearance of ID in the clinical course of the seizures.

Lateralizing value

For all cases with different types of ID, the ictal dystonia was contralateral to the seizure onset zone, regardless of whether the patient was evaluated by invasive EEG.

Other variables

Of the 119 patients who underwent surgery, ictal dystonia (ULD, HED, or LLD) was significantly more frequent in patients with MTLE than in those with nMTLE. In MTLE, it was present in 54 of 93 patients and in nMTLE it was present in only in two of 26 patients (58.1% vs 7.7%; $p < 0.001$). For the two patients with nMTLE, dystonia was ULD in one and HED in the other. Other ictal dystonias were noticed only in MTLE patients (figure 4).

Within the MTLE group (93 patients who underwent surgery), ID (ULD, HED, or LLD) was present in 39 of the 59 patients with MTLE/HS, and in 14 of the 34 patients with MTLE/LES (66.1% vs 41.1% respectively; $p = 0.023$) (figure 5).

Discussion

ID is more frequently present in TLE than extratemporal epilepsy (Bleasel et al., 1997) and is considered to be a relatively frequent ictal sign in 23 to 50% patients with TLE (Bleasel et al., 1997; Dupont et al., 1999; Chou et al., 2004; Kotagal et al., 1989; Yu et al., 2001). In this retrospective study, we revealed that ID was present in 47.9% patients with TLE and in 40.9% of all recorded seizures. This percentage is consistent with previously reported data.

In a previous study, we revealed that ID is a late symptom that occurred on average > 30 seconds after the onset of the epileptic seizure in patients with TLE (Kuba et al., 2003). The term “ictal dystonia” in previous literature has usually referred to dystonia of the upper limbs. This present study is the first to describe the localization of ID in patients with TLE in terms of specific body segment involvement. In seizures where ID was present, ULD was present in 50.5% of the seizures; HED was present in 45.2% of the seizures; LLD was present in 4.3% of the seizures. Our results therefore indicate that for patients with TLE, the involvement of the lower limbs in dystonic

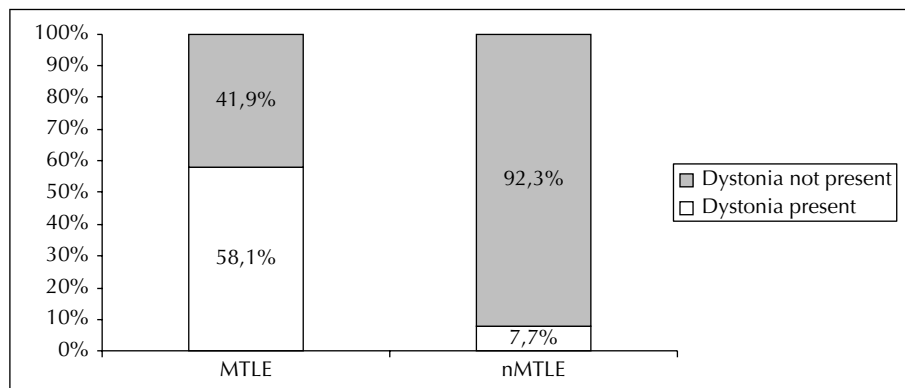


Figure 4. Comparison of the presence of ID in MTLE and nMTLE patients who underwent surgery (in percentages).

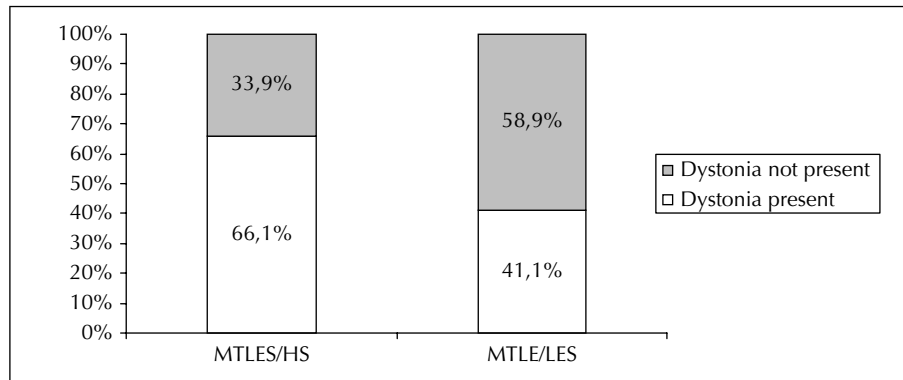


Figure 5. Comparison of the presence of ID in MTLE/HS and MTLE/LES patients who underwent surgery (in percentages).

posturing is almost as frequent as the involvement of the upper limb, HED is common and LLD is relatively infrequent.

The reported data in the literature of ID body segment involvement is scarce and often inaccurate. Williamson *et al.* (1998) mentioned that “dystonia involved most often the arm and less often the leg, and varied from grossly obvious to very subtle, but was highly consistent for each patient.” This study did not provide any further detailed specification of leg dystonia. Similarly, Ray and Kotagal (2005) also mentioned that contralateral dystonic posturing is “most commonly seen in the hand, but occasionally seen in the face and leg”. As in the previously cited study, no further analysis of leg dystonia was reported.

Kotagal *et al.* (1989) speculated that dystonic posturing of the unilateral lower limbs may offer the same lateralizing value as dystonic posturing of the upper extremities. Chou *et al.* (2004) analyzed the lateralizing value of leg behaviour in 38 patients with TLE who were seizure free after temporal lobectomy. Leg behaviour was recorded in 31% of 123 seizures, whereas behaviour of the upper limbs was recorded in 79% of seizures. Of all leg behaviour reported, both tonic and dystonic posturing were usually contralateral to the ictal side. Leg dystonia was noticed only in 2% of all seizures. In this study, leg dystonia was defined as “abnormal extension or flexion with a rotational component, causing unnatural posturing or arched back”.

In addition to its localization value, ID has undoubtedly an excellent lateralizing value. It was exclusively present contralateral to the seizure onset in our study. Almost all studies evaluating the lateralizing value of ID established > 90% predictive value to the contralateral temporal lobe (Bleasel *et al.*, 1997; Dupont *et al.*, 1999; Chou *et al.*, 2004; Kotagal *et al.*, 1989; Newton *et al.*, 1992; Yu *et al.*, 2001; Williamson *et al.*, 1998). The strength of the lateralizing value to the contralateral hemisphere is more prominent in cases where lateralized ID

is associated with automatisms of the side of the body ipsilateral to the seizure onset zone (Dupont *et al.*, 1999). Studies on the general population, i.e. based on mostly noninvasive EEG studies, have shown that ID of any type is significantly more frequent in MTLE patients than in nMTLE patients. In MTLE, it was present in 58.1% of the patients, compared to 7.7% of the patients with nMTLE. The analysis of a smaller subgroup of 38 patients who underwent invasive EEG showed similar results (64 vs 15,4%). Although both results demonstrated higher frequency of ID in mesial temporal epilepsy, these data do not allow us to affirm the precise localising value of ID in TLE patients, due to the low number of patients investigated by means of invasive EEG. Although there are some reported clinical differences between mesial and non-mesial TLE, it is impossible to differentiate between mesial and non-mesial seizure onset based solely on noninvasive data. Moreover simultaneous mesio-lateral seizure onset is reported to occur frequently in TLE patients (Maillard *et al.*, 2004). The temporal pole is another region of the temporal lobe which may be involved in seizure onset in TLE patients. In these patients it is not possible to assess the exact seizure onset zone without appropriate invasive EEG study (Chabardes *et al.*, 2005).

The occurrence of ID predicts the seizure onset zone in mesial temporal structures. In the literature, there are conflicting data concerning the occurrence of ID in MTLE and NTLE. Dupont *et al.* (1999) reported that ID was present in 53% of patients with MTLE and only 23% of patients with NTLE. Whereas the lateralizing value to the contralateral temporal lobe in MTLE of ID was impressive, ID was surprisingly always ipsilateral to seizure onset in NTLE patients. Similar results are reported by other authors (Pfähnder *et al.*, 2002; O’Brien *et al.*, 1996). In the study of Holl *et al.* (2005), no significant differences of ID were identified between MLTE and NTLE groups. In contrast, Gil-Nagel and Risinger (1997) suggested that early contralateral dystonic posturing was more frequent in NTLE. Although some studies may support the notion

that contralateral ID is related to mesial temporal lobe seizure onset, further studies of larger cohort of patients with invasive data are needed to support this hypothesis. Our study demonstrates that there are some differences in the incidence of ID in relation to the underlying epileptogenic lesion. ID in patients with MTLE/HS was present in 66.1% of the patients in our study, whereas it was present in 41.1% of the patients with MLTE/LES.

Saygi *et al.* (1994) reported differences in the clinical course of seizures arising from the temporal lobe in patients with HS and tumours; no significant difference of ID occurrence was noticed. In contrast, Kutlu *et al.* (2005) demonstrated that ID was more often present in patients with HS than in patients with other pathological findings, such as tumours, cavernoma, and haematoma. The clear-cut pathophysiological mechanism of ID and the key structure responsible for its appearance during epileptic seizures remains controversial. Some studies have suggested that epileptic activation of the basal ganglia plays a crucial role in the occurrence of contralateral ID. Kotagal *et al.* (1989) provided indirect evidence of the role of the basal ganglia in the pathophysiology of this phenomenon. In a previous study (Kuba *et al.*, 2003), we did not demonstrate the epileptic activation of the basal ganglia (mostly putamen) contralateral to ID, and noticed widespread activation of the contralateral temporal and frontal lobes at the time of appearance of ID. In the basal ganglia, contralateral to the side of ID, we registered some non-specific changes. The putamen probably collaborates in the genesis of ID, but it does not generate the epileptic discharge during its course (Kuba *et al.*, 2003). Other possible evidence of the involvement of the basal ganglia in ID was obtained from ictal SPECT (single photon emission tomography) studies. Newton *et al.* (1992) studied the regional changes in perfusion during ID with SPECT. A significant increase in the perfusion of the basal ganglia contralateral to the dystonic limbs, compared to seizures without dystonia but with other motor features, was found. The fronto-parietal region, ipsilateral to the discharging lobe, was hypoperfused during temporal seizures; however, this was not specific to the dystonic phase. Only basal ganglia SPECT changes were significant. Joo *et al.* (2004) reported statistically significant hyperperfusion of the caudate nucleus, putamen, and thalamus in patients with ID in comparison to patients without ID, based on subtraction of interictal and ictal SPECT.

The explanation for the relatively low incidence of LLD in comparison to ULD and HED is very controversial. The basal ganglia are involved in the generation of ID, however the nature of this involvement remains hypothetical. Rather than the epileptic activity spreading to the basal ganglia, we hypothesised that the spread of ictal activity from the temporal lobe to either the frontal convexity or the mesial premotor cortex may lead to the impairment of pathways connecting the frontal lobe and

the basal ganglia and thus producing ID. The current view on primary dystonia is that this disorder is better conceptualized as a motor circuit disorder rather than an abnormality of a particular brain structure. Various electrophysiological studies support this hypothesis (Tanabe *et al.*, 2009). Our data suggest that the propagation of ictal discharge occurs from the temporal lobe, contralateral to the side of ictal dystonia, either to the mesial or lateral prefrontal and premotor cortex. The isolated involvement of mesial parts of the frontal lobe without the epileptic activation of lateral regions, leading to the isolated involvement of the pathways involved in leg movements, seems to be rare (Kuba *et al.*, 2003). However, we are aware that this explanation is largely hypothetical.

In summary, in almost half of the seizures studied, ID was present in the form of hemidystonia, and isolated involvement of the lower limbs also occurred. Our study demonstrates that ictal dystonia in TLE is a reliable lateralizing ictal sign and is furthermore typical of mesial onset TLE, especially when hippocampal sclerosis is the epileptogenic lesion. □

Acknowledgments.

This study was supported by the MSMT CR research project: MSM0021622404. We Thank Anne Johnson for grammatical assistance.

Disclosure.

None of the authors has any conflict of interest to disclose.

References

- Bleasel A, Kotagal P, Kankirawatana P, Rybicki L. Lateralizing value and semiology of ictal limb posturing and version in temporal lobe and extratemporal epilepsy. *Epilepsia* 1997; 38: 168-74.
- Chabardes S, Kahane P, Minotti L, *et al.* The temporopolar cortex plays a pivotal role in temporal lobe seizures. *Brain* 2005; 128: 1818-31.
- Chou CW, Yu HY, Shih YH, *et al.* Lateralisation value of lower limb behaviors in complex partial seizures of temporal lobe origin: a video-EEG analysis. *Seizure* 2004; 13: 35-9.
- Dupont S, Semah F, Boon P, *et al.* Association of ipsilateral motor automatisms and contralateral dystonic posturing: a clinical feature differentiating medial from neocortical temporal lobe epilepsy. *Arch Neurol* 1999; 56: 927-32.
- Fakhoury T, Abou-Khalil B. Association of ipsilateral head turning and dystonia in temporal lobe seizures. *Epilepsia* 1995; 36: 1065-70.
- Gil-Nagel A, Risinger M. Ictal semiology in hippocampal versus extrahippocampal temporal lobe epilepsy. *Brain* 1997; 120: 183-92.
- Holl A, Feichtinger M, Körner E, Stefan H, Ott E. Ictal dystonic posturing in mesial versus neocortical temporal lobe seizures. *Seizure* 2005; 14: 269-73.

- Joo EY, Hong SB, Lee EK, *et al.* Regional cerebral hyperperfusion with ictal dystonic posturing: ictal-interictal SPECT subtraction. *Epilepsia* 2004; 45: 686-9.
- Kotagal P, Lüders H, Morris HH, *et al.* Dystonic posturing in complex partial seizures of temporal lobe onset: a new lateralizing sign. *Neurology* 1989; 39: 196-201.
- Kuba R, Rektor I, Brázdil M. Ictal limb dystonia in temporal lobe epilepsy. An invasive video-EEG finding. *Eur J Neurol* 2003; 10: 641-9.
- Kutlu G, Bilir E, Erdem A, *et al.* Temporal lobe ictal behavioral patterns in hippocampal sclerosis and other structural abnormalities. *Epilepsy Behav* 2005; 6: 353-9.
- Maillard L, Vignal JP, Gavaret M, *et al.* Semiologic and electrophysiologic correlation in temporal lobe seizure subtypes. *Epilepsia* 2004; 45: 1590-9.
- Newton MR, Berkovic SF, Austin MC, Reutens DC, McKay WJ, Bladin PF. Dystonia, clinical lateralization, and regional blood flow changes in temporal lobe seizures. *Neurology* 1992; 42: 371-7.
- O'Brien TJ, Kilpatrick C, Nutrie V, Vogrin S, Morfia K, Cook MJ. Temporal lobe epilepsy caused by mesial temporal sclerosis and temporal neocortical lesions. A clinical and electroencephalographic study of 46 pathologically proven cases. *Brain* 1996; 119: 2133-41.
- Pfänder M, Arnold S, Henkel A, *et al.* Clinical features and EEG findings differentiating mesial from neocortical temporal lobe epilepsy. *Epileptic Disord* 2002; 4: 189-95.
- Ray A, Kotagal P. Temporal lobe epilepsy in children: overview of clinical semiology. *Epileptic Disord* 2005; 7: 299-307.
- Saygi S, Spencer SS, Scheyer R, Katz A, Mattson R, Spencer DD. Differentiation of temporal lobe ictal behavior associated with hippocampal sclerosis and tumors of temporal lobe. *Epilepsia* 1994; 35: 737-42.
- Talairach J, Szikla G, Tournoux P, *et al.* *Atlas d'Anatomie Stereotaxique du Telencephale*. Paris: Masson, 1967.
- Tanabe LM, Kim CE, Alagem N, Dauer WT. Primary dystonia: molecules and mechanisms. *Nat Rev Neurol* 2009; 5: 598-609.
- Williamson PD, Thadani VM, French JA, *et al.* Medial temporal lobe epilepsy: Videotape analysis of objective clinical seizure characteristics. *Epilepsia* 1998; 39: 1182-8.
- Yu HY, Yiu CH, Yen DJ, *et al.* Lateralizing value of early head turning and ictal dystonia in temporal lobe seizures: a video-EEG study. *Seizure* 2001; 10: 428-32.