

# Neurosyphilis presenting with status epilepticus

Candan Gürses<sup>1</sup>, Murat Kürtüncü<sup>1</sup>, Jeffrey Jirsch<sup>2</sup>, Nilüfer Yeşilot<sup>1</sup>, Haşmet Hanağası<sup>1</sup>, Nerses Bebek<sup>1</sup>, Betül Baykan<sup>1</sup>, Murat Emre<sup>1</sup>, Ayşen Gökyiğit<sup>1</sup>, Frederick Andermann<sup>2</sup>

<sup>1</sup> Department of Neurology, Istanbul University, Istanbul Faculty of Medicine, Millet Caddesi Capa, 34390 Istanbul, Turkey

<sup>2</sup> McGill University, Montreal Neurological Hospital, Montreal, Quebec, Canada

Received May 15, 2006; Accepted September 4, 2006

**ABSTRACT** – Three patients with neurosyphilis are reported. The first and third patients presented with convulsive status epilepticus and the second with non-convulsive status after penicillin administration. In all cerebrospinal fluid and the serum Venereal Disease Research Laboratory Test (VDRL) and *Treponema Pallidum* hemagglutination (TPHA) or fluorescent treponemal antibody absorption test (FTA-ABS) were positive, but HIV serology was negative. Their EEGs showed periodic, lateralized, epileptiform discharges (PLEDs) just after SE. The first and third patients had no history of epilepsy. Seizures started as focal motor attacks but then secondarily generalized. The first patient's cranial MRI showed cerebral atrophy and hyperintensity involving bilateral medial and anterior temporal regions, more prominent on the left and which disappeared after penicillin treatment. The second case, after receiving penicillin, had nonconvulsive SE, a clinical presentation suggesting a Jarisch-Herxheimer reaction (JHR). Her cranial MR revealed moderate cortical atrophy and widespread confluent hyperintense foci mainly in both periventricular areas, corona radiata and centrum semiovale. MRI of the third case showed a large, left sylvian, arachnoid cyst without mass effect. Executive dysfunction was observed in follow-up neuropsychological tests in all patients. When investigating status epilepticus, neurosyphilis as a cause must not be forgotten.

**Key words:** neurosyphilis, status epilepticus, PLEDs, MRI temporal hyperintensity, Jarisch-Herxheimer reaction

Until the emergence of AIDS, the incidence of neurosyphilis had been decreasing due to intensive use of antibiotic treatments. Now syphilis has become more common in patients with immune suppression, lack of access to primary care, and AIDS (Storm-Mathisen 1978, Schmidt and Gonyea 1975, Rompalo 2002, Hook 1997). Currently, the true incidence of patients with neurosyphilis is not known. It has been mistakenly considered as a disorder of HIV-positive patients only.

A previous study showed that the incidence of seizures in patients with neurosyphilis ranged from 14 to 60% (Hooshmand 1976). *De novo* status epilepticus (SE) is extremely rare as the first symptom of neurosyphilis. The literature contains only isolated case reports (LoVecchio 1995, Heald *et al.* 1996, Suarez *et al.* 1996, Ances *et al.* 2004, Primavera *et al.* 1998).

It is known that patients with Jarisch-Herxheimer reaction (JHR) have convulsions, an altered state of cons-

**Correspondence:**

C. Gürses  
Istanbul University  
Istanbul Faculty of Medicine Millet Caddesi  
Capa  
34390 Istanbul  
Turkey  
Tel.: (+ 00 90) 212 4142000/32565  
Fax: (+ 00 90) 212 5334393  
<candan.gurses@gmail.com>

doi: 10.1684/epd.2007.0058

ciousness, focal neurological signs and psychiatric manifestations. JHR is a complication with a high risk of mortality and severe morbidity. It may occur in about 30% of patients with neurosyphilis after receiving penicillin (Kojan *et al.* 2000, Zifko *et al.* 1994). The penicillin itself may be a factor in the generation of seizures.

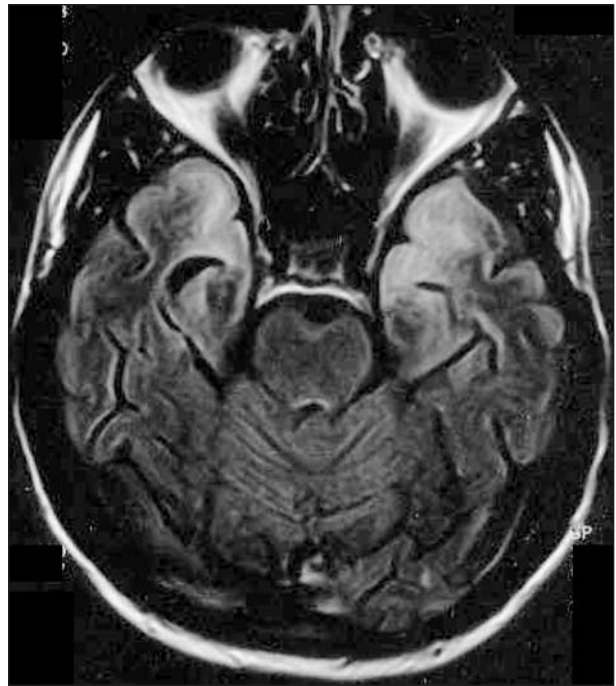
We describe three patients with neurosyphilis, two presented with convulsive SE before penicillin treatment and one with nonconvulsive status epilepticus (NCSE) after receiving penicillin due for JHR.

### Patient 1

A 42-year-old man had progressive memory impairment and speech difficulty for one year. He forgot the names of his relatives and where he put his belongings. He became silent, withdrew from social relations, and lost his job. His psychiatrist tried antidepressants and antipsychotics for the diagnosis of major depression without improvement. On neurological evaluation, he was disoriented with mild dysarthria. He had difficulties with perseverance, diminished concentration and inhibition in his responses. A decrease in verbal fluency was observed. In verbal memory, he was having difficulties in free recall and displaying false positive recognition. The neuropsychological tests indicated executive dysfunction. He had diminished vibration sensitivity in his feet, mildly hyperactive deep tendon reflexes on the left and mild truncal ataxia. Complete blood count, routine serum analysis and sedimentation rate were normal. His cranial MRI showed cerebral atrophy and high signal abnormality, involving bilateral medial and anterior temporal regions more prominent on the left, on T2W and FLAIR images (*figure 1*). No contrast enhancement was found.

His first seizure was described as sudden head and eye deviation to the left and left-sided clonic jerks. For 30 minutes he was conscious but had difficulty in describing his symptoms. On examination, he had bilateral clonic contractions which stopped after being given diazepam 10 mg iv. Four hours after his first seizure, he had three focal-onset, generalized attacks. He was treated with 20 mg/kg phenytoin intravenously. After the status, he presented with transitory post-ictal left homonymous hemianopia, hemiparesis, hemihypalgesia and truncal ataxia. His EEG, done within a few hours, revealed periodic lateralized epileptiform discharges (PLEDs) over the right hemisphere, predominantly in the right temporal region (*figure 2*). CSF analysis showed lymphocytic pleocytosis (22 lymphocytes/mm<sup>3</sup>, 2 polymorphonuclear leucocytes/mm<sup>3</sup>) and a high protein content (134 mg/dL). CSF glucose was normal (80 mg/dL). Serum and CSF VDRL and TPHA were positive. HIV serology and polymerase chain reaction (PCR) for *Herpes simplex* were negative.

He was treated with iv penicillin 24 million units/day for 14 days and with carbamazepine for his seizures. The



**Figure 1.** Transversal FLAIR image shows hyperintensity of bilateral medial and anterior temporal regions more prominent on the left in Patient 1.

hyperintensity on MRI disappeared after penicillin treatment. PLEDs were absent on the 8<sup>th</sup> day of treatment, leaving bilateral slowing in the frontal lobes. After treatment his cognitive abilities and speech recovered, and neurological examination and EEG became normal. Neuropsychological follow-up evaluation five years later, showed mild difficulties in perseverance and free recall of verbal memory. The other evaluations including verbal fluency were normal. He has been seizure-free for five years and has returned to work.

### Patient 2

A 71-year-old woman was brought to the hospital with complaints of impaired memory and walking difficulties. She forgot names and faces of her relatives, and could not recall where she had put her personal belongings. She had unexplained falling episodes, which occurred several times a month. She denied loss of consciousness. Rigidity and ataxic gait were documented. Deep tendon reflexes were hyperactive in the lower extremities, but plantar responses were flexor. Neuropsychological evaluation revealed a frontal dysexecutive syndrome. Cranial MR showed moderate cortical atrophy and widespread confluent hyperintense foci mainly in bilateral periventricular areas, corona radiata and centrum semiovale, consistent with leukoaraiosis (*figures 3, 4*). Extracranial MR angiography was normal except that the V4

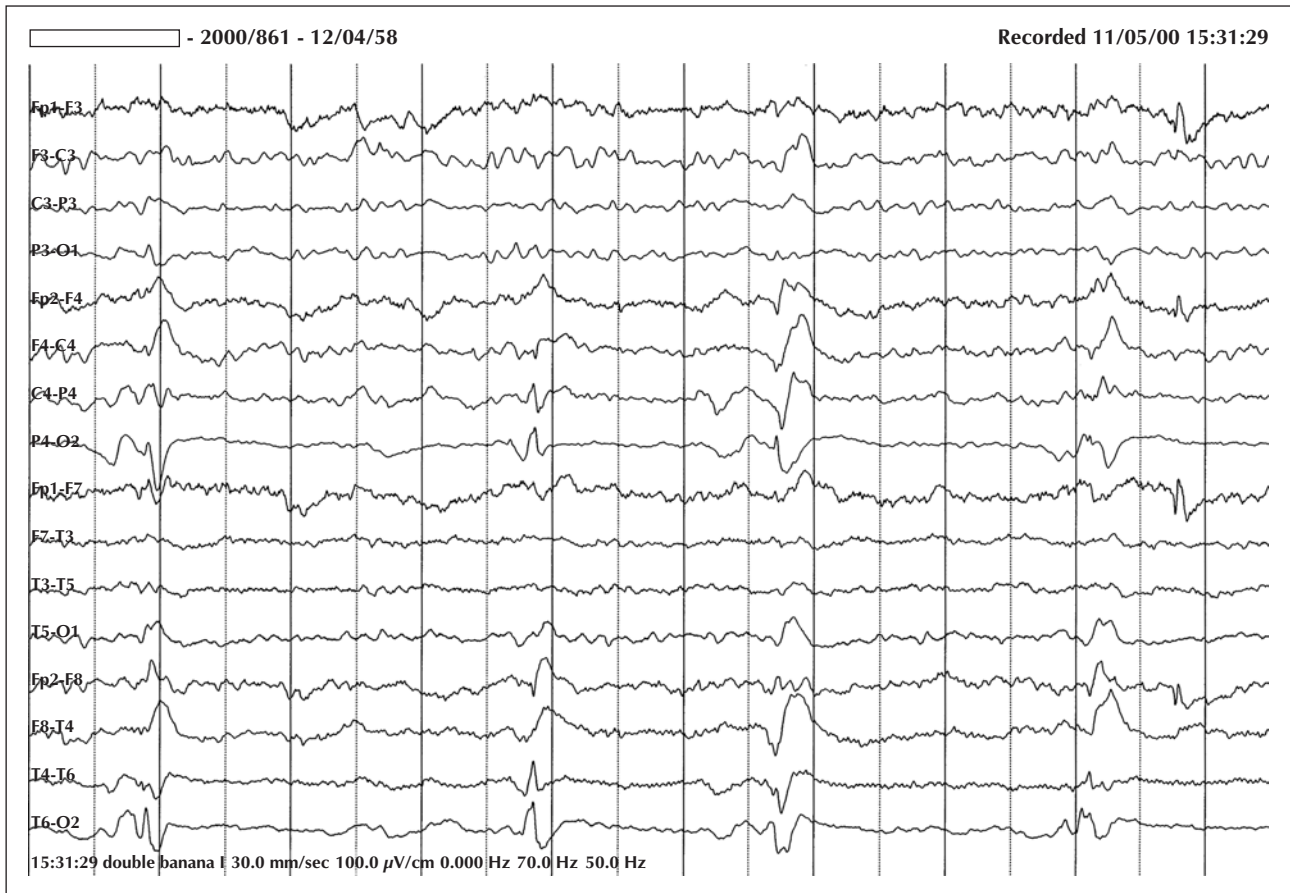


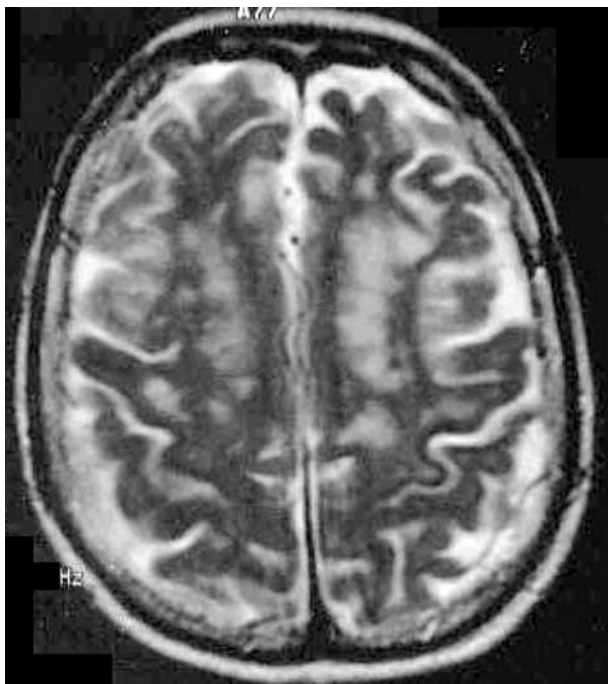Figure 2. PLEDs over the right hemisphere predominantly in the right temporal region in Patient 1.

segment of the vertebral artery was not clearly visible on intracranial MR angiography. Doppler ultrasound examination showed no flow pathology. CSF examination showed a high protein level (156 mg/dL) and mild lymphocytic pleocytosis (28/mm<sup>3</sup>). Both CSF and serum VDRL and TPHA were positive. She was HIV-negative. She was diagnosed to have general paresis, and was treated with 21 million units/day of penicillin. Twelve hours after commencement of treatment she abruptly lost consciousness, had oral automatisms and her eyes deviated to the left. She withdrew her extremities symmetrically in response to painful stimuli. Plantar response was flexor on the left, and extensor on the right. She was diagnosed to have nonconvulsive SE (NCSE) as a part of a JHR. Her EEG showed PLEDs over the right hemisphere, predominantly over fronto-temporal regions (figure 5). She was treated with phenytoin (18 mg/kg). She had none of the classical symptoms of JHR such as fever, tachycardia or hypertension. Her complete blood test was normal and sedimentation rate was 35 mm/hour after SE. Four days later, penicillin was restarted at a dose of 21 million units/day, along with 40 mg/day of methyl prednisolone

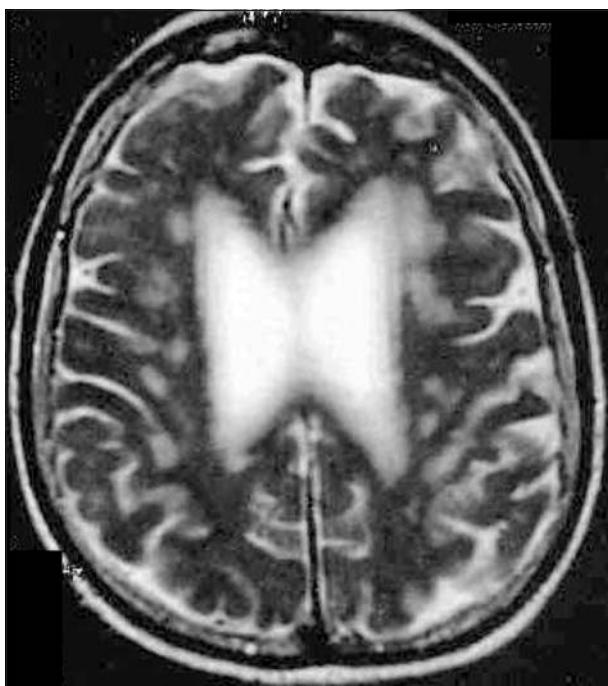for three days without adverse effects. On her last neurological examination, her gait was unsteady and tandem walking was performed with great difficulty. She was lost to follow-up.

### Patient 3

A 44-year-old man developed word finding difficulties, and on the same day had loss of dexterity in his right hand while using chopsticks. Hours later he was found by his wife unconscious with right arm clonic movements. Anti-epileptic drugs did not stop the status. EEG showed pseudoperiodic epileptic discharges maximal in the left posterior quadrant. CT and MRI showed a large left sylvian arachnoid cyst without mass effect. CSF analysis showed lymphocytic pleocytosis (22 lymphocytes/mm<sup>3</sup>, 15 mononuclear leucocytes/mm<sup>3</sup>) and a high protein content. CSF and serum VDRL and FTA-ABS were positive. He was HIV-negative. He was treated with penicillin for 14 days. Eventually, the focal right arm seizures were better controlled and he was extubated. He had language dysfunction with moderate global aphasia as well as some unco-



**Figure 3.** T2W transversal images show widespread, confluent hyperintense foci mainly located in the corona radiata and centrum semiovale bilaterally in Patient 2.



**Figure 4.** T2W transversal images show widespread, confluent hyperintense foci mainly located in the corona radiata and centrum semiovale bilaterally in Patient 2.

ordination of his right limbs. He was maintained on both carbamazepine and phenytoin at the time of his discharge for rehabilitation. Over two years he has had some episodes of a sensation of heat and some stiffening of the right arm. He has also had brief episodes of slurred speech. These sensorimotor manifestations lasted less than a minute. His EEGs showed severe dysfunction, mainly over the lateral aspect of the left hemisphere, but he has had no more major attacks.

## Discussion

General paresis, one of the types of neurosyphilis, causes dementia, seizures, pyramidal signs, optic atrophy and dysarthria (Hook 1997). The three patients presented here had no history of primary syphilis and were diagnosed to have general paresis. All had negative HIV serology. Two patients were investigated for other signs of tertiary syphilis, but none were found. Two patients presented with focal motor SE and the third showed NCSE after receiving penicillin treatment. CSF examinations revealed pleocytosis and increased protein. Serological tests confirmed the diagnosis of neurosyphilis. The first two patients had a rare presentation of SE and memory impairment described in the literature. The first patient's MRI showed hyperintensity over both medial and anterior temporal regions, more prominent on the left side, which disappeared after penicillin treatment. Only a few case reports mentioned MRI findings similar to those of our patients, but no follow-up, control MRI data were described (LoVecchio 1995, Heald *et al.* 1996, Ances *et al.* 2004, Primavera *et al.* 1998). There are no radiological data available for HIV-negative patients with neurosyphilis which would help with prognosis. The MRI findings in two of our patients were an important clue to the diagnosis. The third patient had dual pathology: both neurosyphilis and a large arachnoid cyst. In our patients, the EEGs showed PLEDs. This pattern has occasionally been described as an important feature in patients with neurosyphilis (LoVecchio 1995, Ances *et al.* 2004, Primavera *et al.* 1998). In our previous study on PLEDs, there were no patients with neurosyphilis. It was found that PLEDs which appeared prominently over one side but with a slight contralateral spread, had a stronger relationship with recent frequent seizures/status epilepticus than strictly localized PLEDs (Baykan *et al.* 2000). In another study, most of the EEGs with PLEDs were obtained within the first four days of seizure activity or status epilepticus. The authors postulated that PLEDs could be considered as part of the late phase of SE (Snodgrass 1989). The underlying mechanism causing PLEDs is still unknown. It is impossible to predict the time course of PLEDs. In our first two patients, EEG abnormalities disappeared along with the pathological MRI findings after penicillin treatment.

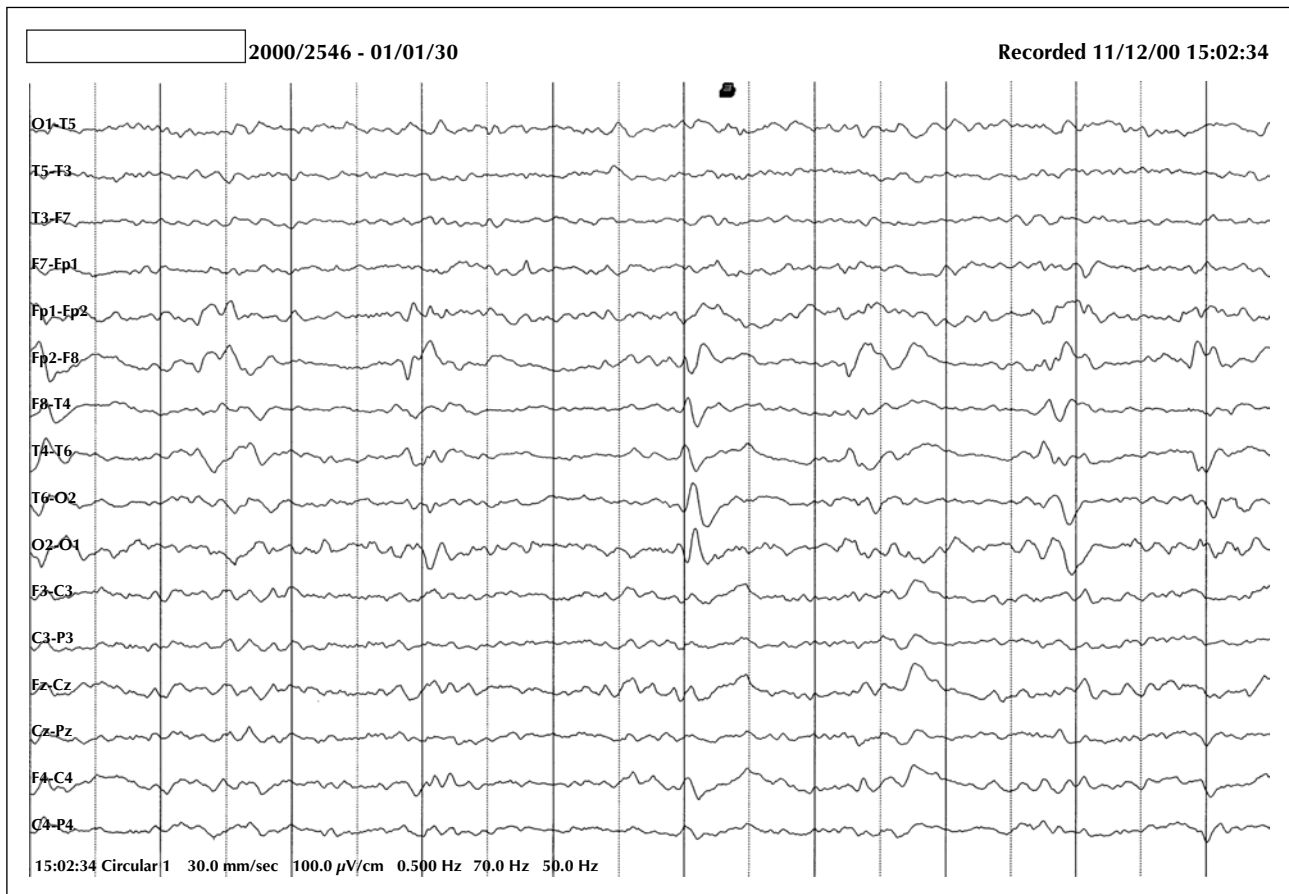


Figure 5. PLEDs over the right hemisphere, predominantly over the fronto-temporal region in Patient 2 who had a Jarisch Herxheimer reaction.

The onset of NCSE in the 12<sup>th</sup> hour after penicillin treatment, the presence of PLEDs in the EEG recorded after NCSE and the neurosyphilis diagnosis led us to suspect a JH reaction, which is historically defined as occurring in patients with neurosyphilis having received penicillin. While the pathogenesis of this reaction is still not fully understood, two types of JHR have been described: One shows a transient rise in temperature, chills, headache, myalgia for 24-hours after drug treatment. In the second type, patients have convulsions, altered mental status, focal neurological signs and psychosis (Aronson and Soltani 1976, Scott *et al.* 1949). This is seen not only during or after treatment with penicillin of patients with neurosyphilis, but also in the course of other spirochetal (louse-borne relapsing fever, rat bite fever, leptospirosis, yaws) and bacterial (brucellosis, tularemia, anthrax) infections (Bryceson 1976, Whittle and Pope 1972). Our second patient is thought to have had the second type of JHR. Finally, the penicillin itself may have been epileptogenic within a patient with a compromised blood brain barrier. The diagnostic possibility of neurosyphilis must be borne in mind in patients with no other obvious cause of status epilepticus. □

## References

- Ances BM, Shellhaus R, Brown MJ, *et al.* Neurosyphilis and status epilepticus: case report and literature review. *Epilepsy Res* 2004; 59: 67-70.
- Aronson IK, Soltani K. The enigma of the pathogenesis of the Jarisch-Herxheimer reaction. *Br J Vener Dis* 1976; 52: 313-5.
- Baykan B, Kınay D, Gökyiğit A, *et al.* Periodic lateralized epileptiform discharges: association with seizures. *Seizure* 2000; 9: 402-6.
- Bryceson ADM. Clinical pathology of the Jarisch-Herxheimer reaction. *J Infect Dis* 1976; 133: 696-704.
- Heald A, Connolly S, Hudgson P. Neurosyphilis presenting as complex partial status epilepticus. *Eur Neurol* 1996; 36: 111-2.
- Hook III EW. Syphilis. In: Scheld WM, Whitley RJ, Durack DT, eds. *Infections of the central nervous system*. Lippincott-Raven Philadelphia, 1997: 669-84.
- Hooshmand H. Seizure disorders associated with neurosyphilis. *Dis Nerv Syst* 1976; 37: 133-6.
- Kojan S, Van Ness PC, Diaz-Arrastia R. Nonconvulsive status epilepticus resulting from Jarisch-Herxheimer reaction in a patient with neurosyphilis. *Clin Electroencephalogr* 2000; 31(3): 138-40.

- LoVecchio F. Neurosyphilis presenting as refractory status epilepticus. *Am J Emerg Med* 1995; 13: 685-6; (letter).
- Primavera A, Solaro C, Cocito L. *De novo* status epilepticus as the presenting sign of neurosyphilis. *Epilepsia* 1998; 39: 1367-9.
- Rompalo AN. Neurosyphilis. In: Johnson RT, Griffin JW, McArthur JC, eds. *Current therapy in Neurologic Disease. 6th edition*. Philadelphia: Mosby, 2002.
- Schmidt RP, Gonyea EF. Neurosyphilis. In: Baker AB, Baker LH, eds. *Clin Neurol Vol 2. Hagerstown*. New York: Harper and Row, 1975: 1-20.
- Scott V, Maxwell RW, Skinner JS. The Jarisch-Herxheimer phenomenon in late syphilis. *JAMA* 1949; 139: 217-20.
- Snodgrass S, Tsuburaya K, Ajmone-Marsan C. Clinical significance of periodic lateralized epileptiform discharges: relationship with status epilepticus. *Jour of Clin Neurophys* 1989; 6: 159-72.
- Storm-Mathisen A. In: Vinken PJ, Klawaw HL, eds. *Syphilis. Handbook of Clinical Neurology*. Vol 33 North-Holland Publishing Company, 1978: 337-94.
- Suarez JI, Mlakar D, Snodgrass SM. Cerebral syphilitic gumma in an HIV negative patient presenting as prolonged focal motor status epilepticus. *N Engl J Med* 1996; 335: 1159-60; (letter).
- Whittle HC, Pope HM. The febrile response to treatment in Gambian sleeping sickness. *Ann Trop Med Parasitol* 1972; 66: 7-14.
- Zifko U, Linder K, Wimberger D, et al. Jarisch-Herxheimer reaction in a patient with neurosyphilis. *J Neurol Neurosurg Psychiatry* 1994; 57: 865-7.