

The precuneal cortex: anatomy and seizure semiology

Ruba R. Al-Ramadhani¹, Veeresh Kumar N. Shivamurthy¹, Kathryn Elkins¹, Satyanarayana Gedela², Nigel P. Pedersen^{1,3}, Ammar Kheder^{1,2,3}

¹ Department of Neurology, Emory University School of Medicine, 201 Dowman Drive, Atlanta, GA 30322, USA

² Children's Healthcare of Atlanta, Atlanta, GA 30322, USA

³ Emory Epilepsy Center, 12 Executive Park Drive, Atlanta, GA 30329, USA

Received July 22, 2020;
Accepted October 20, 2020

ABSTRACT – The purpose of this review is to describe the functional anatomy of the precuneal cortex and outline some semiological features of precuneal seizures. The precuneal cortex is a structure that occupies the posterior medial portion of the parietal lobe, and it has broad cortical and subcortical connections. Neuro-anatomical tracing, functional imaging, as well as electrical stimulation studies of humans and other primates have elucidated many complex integrative functions of the precuneus including visuo-spatial imagery, sensorimotor functions, and consciousness. Based on the understanding of its functions and connectivity, descriptions of potential seizure semiologies are hypothesized and compared to what is available in the literature. The latter is mostly in the form of case reports or case series. Seizures may involve simple or complex motor or sensory manifestations including abnormal eye movements, visual hallucinations, sensation of motion, or medial temporal-like seizures.

Key words: parietal lobe epilepsy; focal epilepsies; precuneus; parietal lobe; epilepsy surgery; SEEG

• **Correspondence:**
Ammar Kheder
Department of Neurology and
Pediatric Institute,
Emory University School of
Medicine,
201 Dowman Drive,
Atlanta, GA, 30322, USA
Nigel P. Pedersen
Department of Neurology,
Emory University School of
Medicine,
101 Woodruff Circle, Room
6107,
Atlanta, GA, 30322, USA
<akheder@emory.edu>
<npeders@emory.edu>

The precuneus is a trapezoidal structure that defines the posterior medial portion of the parietal lobe. This region includes both unimodal and polymodal association regions and has been implicated in many complex integrative functions of the brain including visuo-spatial imagery, sensorimotor functions, and consciousness [1]. The precuneus is extensively involved in many different processes, as we review below, having multiple cortical and subcortical connections. The presentation of lesions in the precuneus can be diverse depending on the location of the lesion. Similarly, precuneal epilepsy represents the rich dynamic interaction between the precuneus and its interconnected structures. Consequently, the clinical manifestations can be difficult to

recognize – a principal motivation for the present review.

Parietal lobe epilepsies make up 5% of focal epilepsies, and a proportion of these originate in the precuneus [2, 3]. However, this may be an underestimation as parietal lobe epilepsy is not frequently studied. Parietal lobe epilepsies can manifest with multiple auras in the same patient, frequently with secondary generalization [4]. Only a handful of reports of precuneal epilepsy exist in the literature, likely because precuneal epilepsy is difficult to recognize, demonstrate and characterize given its heterogeneous presentations and complex circuitry with distinct connections in a relatively small region of the cerebral cortex.

The analysis of seizure semiology is an integral part of presurgical evaluation of epilepsy to better define the epileptogenic zone. Bancaud and Talairach defined the epileptogenic zone as the site of primary organization of the ictal discharges and its early spread [5]. The resultant activation or inhibition of a network of interconnected brain regions gives rise to the symptom and signs of seizure, and the way in which these unfold in time – overall referred to as semiology. An implantation of intracranial electrodes requires the establishment of a solid anatomico-electro-clinical (AEC) hypothesis. Therefore, of an equal importance is an in-depth understanding of functional anatomy in order to plan the implantation schema based on presurgical data. There is significant inter-rater variability in interpreting semiology, as different centers and even different clinicians within the same center may define symptoms and signs of seizure differently [6]. This becomes even more problematic in the case of parietal lobe seizures, particularly those originating from the precuneus, given the wide range of possible semiologies.

For the systematic qualitative component of the present review, we comprehensively searched, evaluated and synthesized research evidence. Inclusion criteria were various types of studies including retrospective studies, review articles, systematic reviews, and case reports. A comprehensive search was performed in PubMed, using terms individually and using the Boolean ANDs and ORs. In the search strategy, the following terms were included: Precuneus OR Precuneal epilepsy OR Parietal lobe epilepsy OR Medial parietal AND seizure AND semiology. Sixty-six articles were found in PubMed. A narrative approach was used to summarize and compare findings of semiologies in articles. Cited references were sometimes obtained, and a broader range of other literature was used in the review of anatomy, function, and organization of the precuneus.

Anatomy

Gross anatomy and histology

Tables 1-2 The precuneus, first illustrated by Soemmering and defined by Burdach [7], refers to the posterior-medial aspect of the superior parietal lobule. The precuneus is defined anatomically as anterior to the cuneus of the occipital lobe, as defined by the parieto-occipital fissure. While typically straight, this fissure can be T-shaped or branched. Anteriorly the border of the precuneus is defined by the posterior paracentral gyrus and the posterior (or marginal) ramus of the cingulate sulcus, corresponding to the posterior margin of the primary sensorimotor cortices [8]. The inferior

border is formed by the subparietal sulcus, which can have a branching course or an H-shape [1].

Given these anatomical landmarks, the medial portion of Brodmann's area (BA) 7 and the dorsal part of BA31 together comprise the precuneus. Brodmann (1909) recognized a histological gradient from anterior to posterior in BA7, with reducing cell density more posteriorly. While BA31 is the dorsal posterior cingulate region, it does not have a clear border with BA7 and likely has more typical cingulate connections; this region extends above the subparietal sulcus and is considered part of the precuneus as defined on gross anatomical grounds (*figure 1*). More recent parcellations based on histology and neuroimaging are shown in *figure 2*. Interestingly, the posterior and ventral portion of the region is architectonically similar to the ventroposterior lateral parietal lobe, which in the rhesus monkey is the parietal gyrus (area PG based on von Economo's nomenclature) (*figure 1*), resulting in the terminology medial PG or PGm. These areas are extensively interconnected [9]. Rapidly evolving studies of regional cortical gene expression and regulatory genes for cortical development herald a new era of genetic-architectonics [10] but are not refined enough on an areal basis at present to be used as a standard method of cortical parcellation for clinical use.

Developmentally, classic studies (e.g. Flechsig, 1901) [11] show that myelinogenesis occurs later than primary sensorimotor regions, with the dorsal anterior precuneus myelinating around the same time as secondary somatosensory and motor cortices, with the remainder of the precuneus, in keeping with a higher order or polymodal role (see below), myelinating very late, shortly before the ultimate completion of myelination in the dorsolateral prefrontal area.

Chemical anatomy

Receptor expression patterns have helped establish the unique functional microarchitecture of the precuneus and have bolstered interspecies comparisons. Neurotransmitter receptors are distributed heterogeneously within the parietal lobe. Based on rhesus monkey autoradiographic data, expression of M3 receptors in the superficial layers of area PGm is high compared to other areas in the parietal lobe, highlighting the existence of this region as proposed on purely cytoarchitectonic grounds previously [12]. While the functional importance of receptor expression is yet to be elucidated, it is interesting that this region, being part of the default mode network [13], expresses excitatory G-protein coupled receptors sensitive to cholinergic inputs provided by components of the basal forebrain arousal nuclei, particularly the nucleus basalis of Meynert [14].

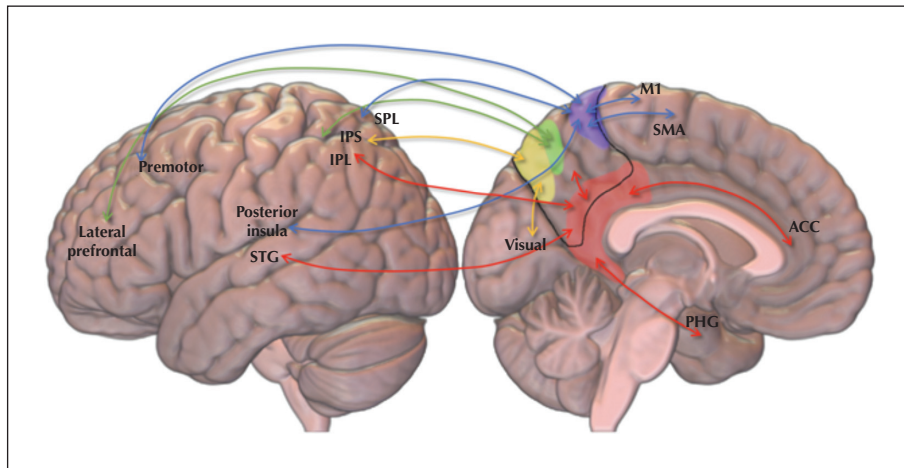


Figure 1. Functional regions of the precuneus and their connections. The four functional subdivisions of the precuneus are depicted: the sensorimotor (blue), cognitive (green), visual (yellow) and limbic (red) subdivisions. Basic connections are depicted. ACC: anterior cingulate cortex/region; IPL: inferior parietal lobule; IPS: intraparietal sulcus; M1: primary motor cortex; PHG: parahippocampal gyrus; SMA: supplementary motor area; SPL: superior parietal lobule; STG: superior temporal gyrus.

Other notable findings seen on chemical studies of the precuneus in certain disease or aging states include decreased metabolism in the bilateral precuneus in early-onset Alzheimer’s disease [15, 16], lowered amplitude of low frequency fluctuations on fMRI suggesting reduction in spontaneous neuronal activity in patients with anti-NMDA encephalitis [17], and a decline in aerobic glycolysis within the precuneus during normal aging that is greater than in most other brain regions [18].

Connections of the precuneus (table 1)

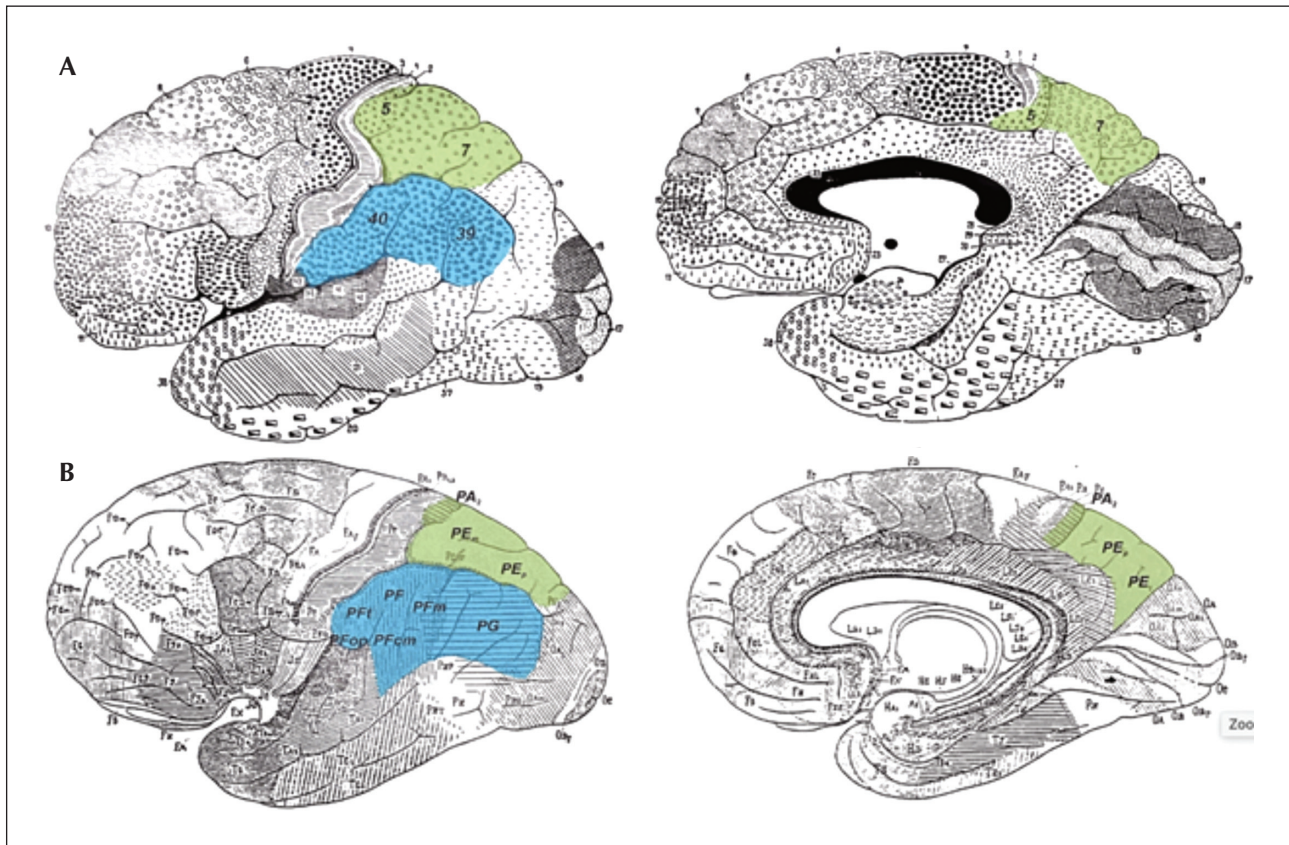
• Functional organization of the precuneus

While considered part of this task-negative network [19], neuroanatomical and functional imaging studies

in non-human primates and humans highlight the central role of the precuneus in specific cognitive tasks related to somatosensory processing, medial temporal inputs from the forebrain, visuospatial processing [20] and cognition. While the default mode network (DMN) hub is thought to reside in the precuneus [13], since studies have shown decreased gamma power during cognitive tasks, present evidence suggests the DMN also, or perhaps only, involves the posterior cingulate cortex (PCC) [21, 22]. Speculatively, the ventral ‘limbic’ medial temporal projecting regions of the precuneus [23] may also be part of this DMN hub, given functional and anatomical similarities to the PCC and both areas are part of the cytoarchitectonic region BA 31.

Table 1. Functional-anatomical divisions of the precuneus.

Precuneus subsections	Connections of the precuneus	Function
Anterior dorsal	Primary and secondary sensory-motor cortices	a. Sensory motor function b. Specially guided movement [33]
Posterior dorsal	Primary and secondary visual cortices	a. Episodic memory and reasoning [30] b. visual special coordination
Ventral precuneus	a. Posterior cingulate gyrus b. Limbic mesial temporal cortex	a. Default mode network (DMN), a network involved in memory, emotion and language processing during resting state [30] b. Attention control [49]
Central precuneus	Prefrontal area	Higher cognitive functions [23,26]



■ **Figure 2.** Cytoarchitectonic parcellation of the precuneus showing parcellations that are commonly used in the epilepsy literature for (A) Brodmann (1909) and (B) von Economo and Koskinas (1925). Note that the margins of the precuneus extend below the shaded area to include the dorsal part of Brodmann's area (BA) 31. In the primate, the central precuneus is termed PGm given the strong homology with von Economo and Koskinas's region, PG. From Caspers *et al.* (2012) [56] with permission.

● **Neuroanatomical tracing studies in the rhesus monkey**

Neuroanatomical tracing, often anterograde tracing with autoradiography in non-human primates, along with other neuroanatomical tracing methods and histological analysis, is the gold standard for determining anatomical connectivity. Given the limitations of diffusion tensor tractography, and the use of structural connectivity to denote this, we suggest using the term *hodological* connectivity to describe methods of neuroanatomical tracing. Studies of non-human primates using autoradiographic and ablation-degeneration techniques found two major rostral-to-caudal connective sequences. The first sequence runs from the dorsal postcentral gyrus, through divisions of the superior parietal lobule, and terminates in the medial surface of the parietal lobe. The second sequence begins in the ventral postcentral gyrus and passes through the rostral inferior parietal lobule to reach the caudal inferior parietal lobule [9]. More recent tracing studies have identified

connections from the dorsal visual precuneus to the posterior dorsal prefrontal cortex (BA8), the posterior claustrum, the intraparietal sulcus, and, as widely appreciated, the inferior parietal lobule [24]. Posterior tracer injections reveal anterograde labeling of efferent projections that are principally within the central precuneus, intraparietal sulcus, posterior parietal region, as well as visual areas V2 and V3, but not the calcarine fissure. When the injection is slightly more dorsal in the visual precuneus, fibers are also noted projecting rostrally into the prefrontal cortex Brodmann areas 6, 9 and 46 and into part of the dorsal V1 region [25]. These marked differences in projection patterns within one candidate domain of the precuneus highlight complex topographic projections that belie the four-sector segregation of the precuneus [23], as described above on the basis of neuroimaging studies (*figure 2*). A fine grained analysis of afferent connections with rhesus retrograde tracing reveal that the higher order visual

area V6A provides input to both the central (PGm) and ventral (BA31) precuneus, but the limbic region has more medial frontal and denser superior/polymodal temporal input, while area PGm has densest input from the ventral precuneal region as well as the lateral parietal and dorsolateral frontal cortex [26]. Together, these findings are consistent with a broadly polymodal function of both regions, albeit of a different flavor, with sensorimotor and visual input predominating for the central precuneus and affective and polymodal sensory inputs for the ventral precuneus. Further bolstering these findings and as a good general principle, connectivity of the prefrontal cortex and cingulate region are essentially reciprocal: for the central region, anterograde tracing from the frontal cortex highlights distinct networks of the dorsal posterior parietal cortex, presumed visual, medial and lateral, to the prefrontal cortex. For the ventral region, reciprocal connections, via the cingulate fasciculus, connect the ventral precuneus, presumably limbic, to the anterior cingulate and medial frontal cortex as well as to the prefrontal areas 8 and 46 [27]. Subcortical projections are less well documented. The sensorimotor precuneus directly innervates the basis pontis in the rhesus monkey based on studies by Schmammann and Pandya in 1989 but this is unknown in humans. In a study by Pandya *et al.* [28], callosal lesions in rhesus monkeys revealed callosal connections by the distribution of degenerating fibers. Based upon this work, the bulk of the precuneus is acallosal, with light contralateral innervation to the central precuneal area. While outside of the precuneus proper, callosal input was noted in the parietooccipital sulcus and surrounding the splenium in the posterior cingulate region. While these regions are outside of the precuneus, both receive input from the precuneus, and are thereby two of several likely oligosynaptic pathways to the contralateral hemisphere.

● **MR-based connectivity**

Connectivity can be assessed in a number of ways, with typical terminology being structural, functional, and effective [29], to which we add hodological connectivity, based in neuroanatomical tracing and described in detail below. In the setting of MR-based work, structural connectivity refers to diffusion-based methods such as diffusion tensor imaging, functional connectivity refers to correlated activity in functional imaging studies (e.g. blood oxygen level desaturation signal in MRI), and effective connectivity refers to techniques that perturb a network to see what changes occur. In the case of the precuneus, our ability to make claims about connectivity is based on having human and rhesus MRI-based tractography, which are similar, then making inferences about human connectivity based

on neuroanatomical tracing studies in non-human primates, principally rhesus monkeys.

Topographical connectivity of the precuneus is notable. Based on analysis of resting state functional connectivity in anesthetized rhesus monkeys and awake resting human subjects, similar patterns of connectivity were noted. Of course, this analysis does not establish anatomical connectivity with certainty, but shows that spatial patterns of correlated cerebral metabolism are similar between humans and rhesus monkeys. Based on these analyses, connectivity of the precuneus was divided into four regions [23] (*figure 2*): (A) The anterior segment contributes to sensorimotor function as it is connected to the primary and secondary sensory and motor cortices. (B) The central precuneus [23], lumped with the ventral precuneus by Wang and co-workers based on tractography [30], is involved in cognition, but is noted by Marguiles to separate into the central region with principally frontal and parietal functional connectivity and the ventral region (C) that connects to 'limbic' structures and the medial temporal lobe. Finally, (D) the posterior portion, is connected to the primary and secondary visual cortices and is thought to participate in higher-order visual functions. Tractography in humans is broadly in agreement with these non-human primate findings [30]. Tractography can suffer from length effects, inability to resolve the entering of exit of smaller bundles, direction, and can show fewer long-range connections than functional connectivity and neuroanatomical tracing approaches, highlighting the valuable contributions of the latter gold standard.

● **Lesion studies (table 2)**

While simple discrete vascular lesion studies are few, there are numerous cases of other lesions of the precuneus or related brain regions that help understand the functional role of the precuneus. Narasimha reported a case of a 59-year-old with left precuneus granuloma presenting with seizures, kinetopsia and delusions of nihilism and guilt [31]. One study by [32] included 14 patients with low-grade gliomas infiltrating either the right or left precuneus, and the anterior-dorsal precuneus was found to be involved in body awareness and perception due to its connections to the primary and secondary somatosensory cortex [32]. Previous studies have identified body awareness disorders like macrosomatognosia, fading limb, and autotopagnosia to be associated with high-order somatosensory cortices [33]. This hypothesis is further supported by the lesion network mapping study by Darby *et al.* which demonstrated that 90% of patients with alien limb syndrome had lesions in areas with functional connectivity to the precuneus, specifically in the right hemisphere [34].

In addition to spatial awareness of the body and associated diseases, precuneal lesions have been implicated

▼ **Table 2.** Summary of precuneal lesional studies.

Study name	Anatomical location	Lesion	Loss of function
Suzuki <i>et al.</i> [6]	Right precuneus	Hemorrhagic stroke	Inability to navigate through either familiar or new environments
Müller <i>et al.</i> [7]	“Virtual lesion” over precuneus	Via transcranial magnetic stimulation	Loss of working memory of object locations
Narasimha <i>et al.</i> [8]	Left precuneus	Granuloma	Kinetopsia; delusions of nihilism and guilt
Herbet <i>et al.</i> [9]	Right or left precuneus and the anterior-dorsal precuneus	Gliomas	Changes in body awareness and perception

in inability to navigate through either familiar or new environments despite being able to describe its location and sometimes even being able to describe how to get to a certain location—a phenomenon called topographical disorientation. A case report by Suzuki *et al.* [35] described a woman who had suffered a hemorrhagic stroke in the right precuneus and subsequently was unable to find her way to places she knew despite being able to describe their locations and recognize buildings. Topographical disorientation and its association with predominantly right precuneal lesions highlight the importance of the precuneus for visuospatial functions. A similar study simulated lesions in the precuneus with transcranial magnetic stimulation to demonstrate the essential role of the precuneus in developing a working memory of object locations and then for using these locations to form a self-centered map with which one can navigate the environment [36]. In a stroke study by Yassi *et al.* in 2015, it was found that strokes involving the precuneus in the left hemisphere were associated with a non-favorable outcome with higher Modified Rankin Scores [37].

● **Direct electrical stimulation mapping**

Stimulation studies have helped elucidate the precuneus's role in vision, visual integration, and possibly vestibular function. Thierie and Andersen hypothesized ‘medial parietal eye field’ after eliciting saccades with electrical microstimulation of the posterior medial parietal cortex in primates [38]. In another study, clinical manifestations induced by bipolar electrical stimulation were analyzed in 172 patients [39] with at least one electrode stereotactically implanted in the parietal cortex. Electrical stimulations in both hemispheres elicited visual illusions or hallucinations, consistent with a previous study by Richer *et al.* [40]. Precuneal stimulation was not helpful in lateralization, perhaps related to its associational nature and strong interhemispheric connections. Another notable finding from this study by Balestrini

et al. [39] included vertiginous symptoms in six subjects with non-dominant and one with dominant hemispheric stimulation. The study authors proposed the vestibular responses may be likely due to the role of the precuneus in the processing of spatial information relative to the position of the subject, allowing the control of body movements. Other studies suggest that the precuneus has a role in vestibular function. One study retrospectively analyzed electrical stimulation in 260 patients with focal epilepsy with vestibular symptoms as part of their epilepsy [41]. Four patients had vestibular symptoms with stimulation of the precuneus (one with left precuneal stimulation, three with right-sided stimulation), all within BA7. The authors of this study suggest but report that they cannot definitively state that the precuneus, specifically an area within BA7, is involved in vestibular function. A case report described a 16-year-old boy with seizure semiology of lateral sensation of movement [42], he had a known lesion in the right paramedian precuneus and electrical cortical stimulation of the area elicited the same vestibular sensation he described with his seizures, again highlighting a possible vestibular role for this region.

● **Functional correlations of precuneal connectivity**

Anatomical connections described above imply and are known to be associated with particular cortical functions, as are reciprocal connections of the dorsal thalamus and precuneus. The main parietal lobe connections to the precuneus are through the caudal parietal operculum, inferior and superior parietal lobules, and internal parietal sulcus [1]. The latter is well studied and has been shown to function in visual-spatial processing, containing the lateral parietal eye fields. It is hypothesized that the precuneus contains a “medial parietal eye field” and is involved in both eye movement control and visual reaching based on monkey functional stimulation studies. This is likely by virtue of either medial to lateral parietal connections

and association with the parietal eye field, or a direct projection to the frontal eye field.

The large group of cortical connections are those with the frontal lobe, but the precuneus innervates each lobe to some extent. The lateral prefrontal cortex, dorsal premotor cortex, supplementary motor area, anterior cingulate gyrus, and frontal eye fields all receive direct precuneal input (*figure 2*), and mostly project reciprocally back to the precuneus. The major projections from the precuneus to the lateral parietal area and premotor cortex play a major role in hand-eye coordination [1]. The precuneus is also connected to different high-order-associated cortices like the temporo-parietal-occipital polymodal cortex which is involved in major sensory processing including auditory, visual and somatosensory processes.

Functional subdivisions of the precuneus are consistent with its cortico-thalamic relations. Taking a broad view, the precuneus can be seen as composed of unimodal (and limbic) association cortices at its edges, with a central polymodal association area (e.g. the 'cognitive' precuneus). Relatedly, the precuneus does not receive direct input from somatosensory relay nuclei. Instead, and as a general principal, the precuneus is connected to the lateral posterior and, somewhat topographically, to the anterior and lateral pulvinar nuclei [43]. The 'limbic' portion of the precuneus, composed of BA31, in keeping with its functional role and connections, is connected with the anterior nuclei and lateral dorsal nucleus of the thalamus [44]. It is worth noting, however, that it is the more ventral BA31 that projects into these regions, thus the significance of these findings for the precuneal dorsal portion of BA31 is not resolved. Specifically, the function of this region is mnemonic, potentially internally-directed (e.g. default mode, although this may be the retrosplenial area) and likely visuospatial, and its connections are with the anterior cingulate gyrus and medial temporal lobe, all consistent with anterior thalamic connection. Retrograde tracing from the dorsal portion of area 31 shows the above inputs along with labeled neurons in the intralaminar mediodorsal and paracentral nuclei [45]. The major thalamic connections of the precuneus, being the pulvinar and laterodorsal nuclei [46], are likely similar in the human based on phylogenic considerations, diffusion imaging [47], and functional imaging [48]. Functional imaging further shows relations with other network components of each precuneal region, along with expanded and expected thalamic relations [49].

In addition to its involvement in auditory, visual and sensorimotor processes, the precuneus is thought to play a major role in consciousness. In overview, posterior cortices likely have a key role in consciousness, e.g. see Koch *et al.* [50], and we presume that is more specifically related to polymodal sensory perceptual

consciousness. Clearly, the parietal cortices, including the precuneus, participate in the higher-order processing of unimodal and polymodal information. Consistent with this idea, when there is loss of consciousness, such as in deep sleep or a vegetative state, the precuneus has been found to be significantly less active and is one of the first regions in the brain to resume activity once patients regain consciousness [1]. Finally, reports of unusual seizure semiology with startle reflex seizures or sensation of imbalance, with lesions identified in the precuneus, suggest that it may also be involved in other processes including part of the startle-induced network and the vestibular system.

Semiology of seizures

• *Semiology based on a systematic qualitative review*

The majority of the literature describing precuneal seizures attributes the wide range of semiologies to the extensive connectivity to multimodal association areas. As discussed earlier, there are multiple processes in which the precuneus is involved including sensorimotor functions, cognition/consciousness, visual integration, and vestibular sensations. Because of these wide connections throughout the cerebral cortex, seizures caused by precuneal involvement may propagate to different areas causing unusual seizure semiologies. Umeoka *et al.* reported a patient with anterior precuneal cortical dysplasia with seizure semiology of bilateral symmetrical tonic posturing of the upper extremities and impaired consciousness which was thought to be a result of propagation to the ipsilateral supplementary motor and premotor cortex [51]. In light of the connectivity described above, spread from or through the sensorimotor precuneus into the frontal motor regions seems likely.

Mailo *et al.* [52] reported right posterior precuneus epilepsy and further discussed the role of the precuneus in spatial awareness, visuo-spatial processing and consciousness, their patient-reported seizures consisted of feeling an urge to move but without vertigo, syncope, or a sense of imbalance. Scalp EEG localized seizures to the non-dominant parieto-occipital region, and imaging findings were consistent with a low-grade neoplasm in the medial parietal cortex. Semiology was explained by the hypothesized role of the precuneus in generating spatial information for imagined or planned body movement [53].

Other case reports have reported unusual semiologies. For example, Saeki *et al.* [54] described startle-induced seizures associated with an epileptogenic zone in the precuneus. The patient reported seizures as linear self-motion perception and occasional body tilts with swaying sensations described as 'being on a boat'. Intracranial electrophysiology showed seizure

onset from circumscribed ependymoma in the paramedian precuneus and hence the region was thought to be associated in processing of static and dynamic vestibular information [42].

● **Possible semiological features of seizures arising in the precuneal cortex**

The Precuneus has strong cortical and subcortical connections which have been demonstrated in stimulation, lesional and functional studies. One can speculate, based on these findings, the theoretically varied manifestations of precuneal epilepsy originating from different sub-regions of the precuneus. These potential features are based on our current understanding of the functional connectivity and the aforementioned literature.

The sensorimotor anterior precuneal region

This can lead to simple or complex motor or sensory manifestations due to connections with the paracentral lobule, BA2, BA6 and SMA. Tonic, clonic, versive, hypermotor, bilateral asymmetric tonic manifestations have been reported [55].

This area is also connected with the parietal operculum and the insula which may contribute to vestibular and body image disturbance.

The cognitive/associative central precuneal region

This region connects with the angular gyrus and the dorsolateral prefrontal cortex including area 8, and therefore, could be related to some of the eye movement-related semiology, such as eye deviation [55].

The visual posterior precuneal region

Complex visual hallucinations and visual illusion can be predicted based on connectivity to the posterior fusiform gyrus. The involvement of the primary visual cortex can lead to elementary visual hallucinations. Blurred vision has been reported which may also be related to this region.

The limbic precuneal region

This area is closely related to the posterior cingulate/retrosplenial region which connects to the limbic medial temporal region, including the parahippocampal gyrus and hippocampus. This can lead to mesial temporal-like manifestations. Given its connectivity with BA32 and 25, a variety of autonomic and emotional responses could be seen.

Conclusion

The precuneus is a fascinating structure which has many known, and potentially still to be discovered, functions due to its extensive cortical and subcortical connections. In summary, the precuneus

can be divided into four distinct regions based on each area's known networks connecting it to other parts of the brain and its associated functions:

The anterior dorsal precuneus has strong connections to primary and secondary sensory-motor cortices, including the frontal eye field which indicate sensory motor function. In addition, it has a role in specially guided movement [33].

The posterior dorsal precuneus is part of a network involving the primary and secondary visual cortices, likely making it essential for visuospatial coordination. It has also been implicated in developing episodic memory and reasoning [30].

The ventral precuneus is part of mnemonic networks and may be part of the default mode network (DMN), a network involved in memory, emotion and language processing during the resting state [30]. However, the most anterior part of the ventral precuneus is involved in attention control [49].

Finally, the central precuneus connects to the prefrontal area through the multisensory posterior inferior parietal lobule and is thought to function within the higher cognitive polymodal cortex [23].

Overall, the precuneus contributes to many different processes that include, but are not limited to, auditory, vestibular, visual, sensorimotor, coordination, and memory consolidation and retrieval functions. ■

Supplementary data.

Summary didactic slides are available on www.epilepticdisorders.com website.

Funding.

Nigel P. Pedersen is supported by the National Institute of Neurological Disorders and Stroke of the National Institutes of Health under award number K08NS105929.

Disclosures.

Nigel P. Pedersen is a member of the Scientific Advisory Board for Dixi Medical USA.

The other authors have no disclosures to declare.

References

1. Cavanna AE, Trimble MR. The precuneus: a review of its functional anatomy and behavioural correlates. *Brain* 2006; 129(3): 564-83.
2. Salanova V. Parietal lobe epilepsy. *J Clin Neurophysiol* 2012; 29: 392-6.
3. Siegel AM, Andersen RA, Freund H-J, Spencer DS. *The Parietal Lobes*. New York, NY: Lippencott, Williams and Wilkins, 2003.
4. Francione S, Liava A, Mai R, Nobili L, Sartori I, Tassi L, et al. Drug-resistant parietal epilepsy: polymorphic ictal

- semiology does not preclude good post-surgical outcome. *Epileptic Disord* 2015; 17(1): 32-46.
5. Talairach J, Bancaud J. Lesion, "irritative" zone and epileptogenic focus. *Stereotactic Funct Neurosurg* 1966; 27: 91-4.
 6. Tufenkjian K, Lüders HO. Seizure semiology: its value and limitations in localizing the epileptogenic zone. *J Clin Neurol* 2012; 8(4): 243-50.
 7. Swanson LW. Response to Foley's review of Swanson's Neuroanatomical Terminology (2014). *J Hist Neurosci* 2015; 24(2): 199-202.
 8. Johns P. Functional neuroanatomy. In: Johns P. *Clinical Neuroscience*. Churchill Livingstone, 2014; Chapter 3: 27-47.
 9. Pandya DN, Seltzer B. Intrinsic connections and architectonics of posterior parietal cortex in the rhesus monkey. *J Comp Neurol* 1982; 204(2): 196-210.
 10. Grasby KL, Jahanshad N, Painter JN, Colodro-Conde L, Bralten J, Hibar DP, et al. The genetic architecture of the human cerebral cortex. *Science* 2020; 367: 6484.
 11. Flechsig of Leipsic P. Developmental (myelogenetic) localisation of the cerebral cortex in the human subject. *Lancet* 1901; 158(4077): 1027-30.
 12. Impieri D, Zilles K, Niu M, Rapan L, Schubert N, Galletti C, et al. Receptor density pattern confirms and enhances the anatomic-functional features of the macaque superior parietal lobule areas. *Brain Struct Funct* 2019; 224(8): 2733-56.
 13. Utevsky AV, Smith DV, Huettel SA. Precuneus is a functional core of the default-mode network. *J Neurosci* 2014; 34(3): 932-40.
 14. Mesulam MM, Mufson EJ, Levey AI, Wainer BH. Atlas of cholinergic neurons in the forebrain and upper brainstem of the macaque based on monoclonal choline acetyltransferase immunohistochemistry and acetylcholinesterase histochemistry. *Neuroscience* 1984; 12(3): 669-86.
 15. Rabinovici GD, Miller BL. Frontotemporal lobar degeneration: epidemiology, pathophysiology, diagnosis and management. *CNS Drugs* 2010; 24(5): 375-98.
 16. Shivamurthy VKN, Tahari AK, Marcus C, Subramaniam RM. Brain FDG PET and the diagnosis of dementia. *AJR Am J Roentgenol* 2015; 204(1): W76-85.
 17. Cai L, Liang Y, Huang H, Zhou X, Zheng J. Cerebral functional activity and connectivity changes in anti-N-methyl-D-aspartate receptor encephalitis: a resting-state fMRI study. *Neuroimage Clin* 2020; 25: 102189.
 18. Goyal MS, Vlassenko AG, Blazey TM, Su Y, Couture LE, Durbin TJ, et al. Loss of brain aerobic glycolysis in normal human aging. *Cell Metab* 2017; 26(2): 353-60.e3.
 19. Fox MD, Snyder AZ, Vincent JL, Corbetta M, Van Essen DC, Raichle ME. The human brain is intrinsically organized into dynamic, anticorrelated functional networks. *Proc Natl Acad Sci USA* 2005; 102(27): 9673-8.
 20. Costigan AG, Umla-Runge K, Evans CJ, Hodgetts CJ, Lawrence AD, Graham KS. Neurochemical correlates of scene processing in the precuneus/posterior cingulate cortex: a multimodal fMRI and 1H-MRS study. *Hum Brain Mapp* 2019; 40(10): 2884-98.
 21. Li J, Kronemer SI, Herman WX, Kwon H, Ryu JH, Micek C, et al. Default mode and visual network activity in an attention task: direct measurement with intracranial EEG. *Neuroimage* 2019; 201: 116003.
 22. Jerbi K, Vidal JR, Ossandon T, Dalal SS, Jung J, Hoffmann D, et al. Exploring the electrophysiological correlates of the default-mode network with intracerebral EEG. *Front Syst Neurosci* 2010; 28: 4: 27.
 23. Margulies DS, Vincent JL, Kelly C, Lohmann G, Uddin LQ, Biswal BB, et al. Precuneus shares intrinsic functional architecture in humans and monkeys. *Proc Natl Acad Sci USA* 2009; 106(47): 20069-74.
 24. Schmahmann JD, Pandya DN. Superior longitudinal fasciculus and arcuate fasciculus. *Fiber Pathways of The Brain*. New York, NY: Oxford University Press, 2006; 393-408.
 25. Yeterian EH, Pandya DN. Fiber pathways and cortical connections of preoccipital areas in rhesus monkeys. *J Comp Neurol* 2010; 518(18): 3725-51.
 26. Passarelli L, Rosa MGP, Bakola S, Gamberini M, Worthy KH, Fattori P, et al. Uniformity and diversity of cortical projections to precuneate areas in the macaque monkey: what defines area PGm? *Cereb Cortex* 2018; 28(5): 1700-17.
 27. Yeterian EH, Pandya DN, Tomaiuolo F, Petrides M. The cortical connectivity of the prefrontal cortex in the monkey brain. *Cortex* 2012; 48(1): 58-81.
 28. Pandya DN, Karol EA, Heilbronn D. The topographical distribution of interhemispheric projections in the corpus callosum of the rhesus monkey. *Brain Res* 1971; 32(1): 31-43.
 29. Park H-J, Friston K. Structural and functional brain networks: from connections to cognition. *Science* 2013; 342(6158): 1238411.
 30. Wang J, Becker B, Wang L, Li H, Zhao X, Jiang T. Corresponding anatomical and coactivation architecture of the human precuneus showing similar connectivity patterns with macaques. *Neuroimage* 2019; 200: 562-74.
 31. Narasimha VL, Basavaraju R, Mangalore S, Mehta UM. Precuneus and psychiatric manifestations: novel neurobiological formulations through lesion based connectivity mapping of psychopathology. *Asian J Psychiatr* 2019; 39: 98-100.
 32. Herbet G, Lemaitre A-L, Moritz-Gasser S, Cochereau J, Duffau H. The antero-dorsal precuneal cortex supports specific aspects of bodily awareness. *Brain* 2019; 142(8): 2207-14.
 33. Zhang S, Li C-SR. Functional connectivity mapping of the human precuneus by resting state fMRI. *Neuroimage* 2012; 59: 3548-62.
 34. Darby RR, Ryan Darby R, Joutsa J, Burke MJ, Fox MD. Lesion network localization of free will. *Proc Natl Acad Sci USA* 2018; 115(42): 10792-7.
 35. Suzuki K, Yamadori A, Hayakawa Y, Fujii T. Pure topographical disorientation related to dysfunction of the viewpoint dependent visual system. *Cortex* 1998; 34(4): 589-99.

36. Müller NG, Riemer M, Brandt L, Wolbers T. Repetitive transcranial magnetic stimulation reveals a causal role of the human precuneus in spatial updating. *Sci Rep* 2018; 8(1): 10171.
37. Yassi N, Churilov L, Campbell BCV, Sharma G, Bammer R, Desmond PM, *et al.* The association between lesion location and functional outcome after ischemic stroke. *Int J Stroke* 2015; 10(8): 1270-6.
38. Thier P, Andersen RA. Electrical microstimulation distinguishes distinct saccade-related areas in the posterior parietal cortex. *J Neurophysiol* 1998; 80(4): 1713-35.
39. Balestrini S, Francione S, Mai R, Castana L, Casaceli G, Marino D, *et al.* Multimodal responses induced by cortical stimulation of the parietal lobe: a stereo-electroencephalography study. *Brain* 2015; 138(9): 2596-607.
40. Richer F, Martinez M, Cohen H, Saint-Hilaire JM. Visual motion perception from stimulation of the human medial parieto-occipital cortex. *Exp Brain Res* 1991; 87(3): 649-52.
41. Kahane P, Hoffmann D, Minotti L, Berthoz A. Reappraisal of the human vestibular cortex by cortical electrical stimulation study. *Ann Neurol* 2003; 54(5): 615-24.
42. Wiest G, Zimprich F, Prayer D, Czech T, Serles W, Baumgartner C. Vestibular processing in human paramedian precuneus as shown by electrical cortical stimulation. *Neurology* 2004; 62(3): 473-5.
43. Jones EG. *The Thalamus, 2nd Ed.* Cambridge University Press. Cambridge (Google Scholar), 2007.
44. Aggleton JP, Saunders RC, Wright NF, Vann SD. The origin of projections from the posterior cingulate and retrosplenial cortices to the anterior, medial dorsal and laterodorsal thalamic nuclei of macaque monkeys. *Eur J Neurosci* 2014; 39(1): 107-23.
45. Gamberini M, Passarelli L, Impieri D, Worthy KH, Burman KJ, Fattori P, *et al.* Thalamic afferents emphasize the different functions of macaque precuneate areas. *Brain Struct Funct* 2020; 225(2): 853-70.
46. Grodd W, Kumar VJ, Schüz A, Lindig T, Scheffler K. The anterior and medial thalamic nuclei and the human limbic system: tracing the structural connectivity using diffusion-weighted imaging. *Sci Rep* 2020; 10(1): 10957.
47. Behrens TEJ, Johansen-Berg H, Woolrich MW, Smith SM, Wheeler-Kingshott CAM, Boulby PA, *et al.* Non-invasive mapping of connections between human thalamus and cortex using diffusion imaging. *Nat Neurosci* 2003; 6(7): 750-7.
48. Zhang D, Snyder AZ, Shimony JS, Fox MD, Raichle ME. Non-invasive functional and structural connectivity mapping of the human thalamocortical system. *Cereb Cortex* 2010; 20(5): 1187-94.
49. Cauda F, Geminiani G, D'Agata F, Sacco K, Duca S, Bagnshaw AP, *et al.* Functional connectivity of the posteromedial cortex. *PLoS One* 2010; 5(9): e13107.
50. Koch C, Massimini M, Boly M, Tononi G. Posterior and anterior cortex - where is the difference that makes the difference? *Nat Rev Neurosci* 2016; 17: 666-6.
51. Umeoka S, Baba K, Terada K, Matsuda K, Tottori T, Usui N, *et al.* Bilateral symmetric tonic posturing suggesting propagation to the supplementary motor area in a patient with precuneate cortical dysplasia. *Epileptic Disord* 2007; 9(4): 443-8.
52. Mailo J, Tang-Wai R. Insight into the precuneus: a novel seizure semiology in a child with epilepsy arising from the right posterior precuneus. *Epileptic Disord* 2015; 17(3): 321-7.
53. Ogiso T, Kobayashi K, Sugishita M. The precuneus in motor imagery: a magnetoencephalographic study. *Neuroreport* 2000; 11(6): 1345-9.
54. Saeki K, Saito Y, Sugai K, Nakagawa E, Komaki H, Sakuma H, *et al.* Startle epilepsy associated with gait-induced seizures: pathomechanism analysis using EEG, MEG, and PET studies. *Epilepsia* 2009; 50(5): 1274-9.
55. Harroud A, Boucher O, Tran TPY, Harris L, Hall J, Dubeau F, *et al.* Precuneal epilepsy: clinical features and surgical outcome. *Epilepsy Behav* 2017; 73: 77-82.
56. Caspers S, Amunts K, Zilles K. Posterior parietal cortex: multimodal association cortex. In : Mai J, Paxinos G (Eds.). *The Human Nervous System*. 2012: 1036-55.

TEST YOURSELF

- (1) What are the functional subdivisions of the precuneus?
- (2) What are the principal connections to the subdivisions of the precuneus?
- (3) What are the possible semiological manifestations of the subdivisions of the precuneus?

Note: Reading the manuscript provides an answer to all questions. Correct answers may be accessed on the website, www.epilepticdisorders.com, under the section "The EpiCentre".